

Comparative Evaluation of Peroneus Longus Tendon and Hamstring Tendon Autografts in Primary Anterior Cruciate Ligament Reconstruction: A Randomized Controlled Trial

Aiysha Khatun¹, Sunita Sharma¹, Ritu Raj Singh¹

Dear Editor,

We read with great interest, the article by Malik et al., "Comparative Evaluation of Peroneus Longus Tendon and Hamstring Tendon Autografts in Primary Anterior Cruciate Ligament (ACL) Reconstruction: A Randomized Controlled Trial." The authors are to be commended for contributing randomized data regarding a pertinent question of graft choice. Based upon our review of the paper, we would like to comment with constructive spirit on some possible limitations in their work that have not been addressed by the authors.

First, the methods the authors used to estimate their sample size are mentioned very briefly as being based on "pilot data from similar published studies," without mentioning their primary endpoint, expected effect size, standard deviation, or minimum important difference that the study would be powered to identify. In ACL reconstruction research, contemporary work increasingly relates power calculations to established minimal clinically important differences (MCID) or patient acceptable symptom states for commonly used patient-reported outcome measures. The MCID for the Lysholm scale has been identified as 5.5 points; however, in this study, the difference between groups at 6 months is 4.3 points (89.4 vs. 85.1), which might be statistically significant but not necessarily clinically significant. Similarly, the minimum important difference in respect of the international knee documentation committee (IKDC) score

does not receive any attention from the authors, despite its clinical importance.

Second, the variability in endpoints and follow-up intervals raises concerns about Type I error inflation. This is because the study makes group comparison using graft diameter, surgery time, pain ratings at 3-time intervals, various functional scores at 3 and 6 months, different stability parameters, strength scores, range of motion, donor pain, and sport participation measures, each tested with an unadjusted alpha level of 0.05. Therefore, P-values barely significant at a threshold of 0.05, such as IKDC and Lysholm scores at 6 months, and Tegner score $P = 0.05$ must be interpreted with care in case effect sizes are small.

Third, there is little information on the standardization of surgical techniques and rehabilitation protocols. The authors mention that fixation was done using "interference screws or suspensory devices according to standard protocol," but do not specify if type of devices and tunnel configuration were comparable across groups. As fixation plays an important role in the stiffness and laxity of the graft, this variability might lead to inaccurate comparison of post-operative stability and rehabilitation outcomes. Similarly, while both groups had "identical rehabilitation protocol," details on important parameters, including gradual loading and sport activity reintroduction guidelines, are missing.


Fourth, the assessment of donor site morbidity was performed

Access this article online


Website:
www.jocr.co.in

DOI:
<https://doi.org/10.13107/jocr.2026.v16.i07.7762>

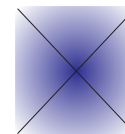
Author's Photo Gallery



Dr. Aiysha Khatun



Dr. Sunita Sharma



Dr. Ritu Raj Singh

¹Department of Orthopaedics, Maharishi Markandeshwar Institute of Physiotherapy and Rehabilitation, Maharishi Markandeshwar (Deemed to be University), Mullana-Ambala, Haryana, India.

Address of Correspondence:

Dr. Sunita Sharma,
Department of Orthopaedics, Maharishi Markandeshwar Institute of Physiotherapy and Rehabilitation, Maharishi Markandeshwar (Deemed to be University), Mullana-Ambala, Haryana, India.

E-mail: ptsunitasharma81@gmail.com

Submitted: 26/06/2026; Review: 27/06/2026; Accepted: June 2026; Published: July 2026

DOI: <https://doi.org/10.13107/jocr.2026.v16.i07.7762>

© The Author(s). 2026 Open Access. This article is distributed under the terms of the Creative Commons Attribution 4.0 International License (<https://creativecommons.org/licenses/by-nc/4.0/>), which permits unrestricted use, distribution, and non-commercial reproduction in any medium, provided you give appropriate credit to the original author(s) and the source, provide a link to the Creative Commons license, and indicate if changes were made. The Creative Commons Public Domain Dedication waiver (<http://creativecommons.org/publicdomain/zero/1.0/>) applies to the data made available in this article, unless otherwise stated.

using manual strength grading along with a general pain assessment tool known as the visual analog scale, but it did not utilize any patient-reported outcomes specific to the ankle, such as American orthopaedic foot and ankle society or foot and ankle disability index scores, which are commonly used today within the project learning tree (PLT) literature. The claim that donor ankle morbidity is “minimal” may therefore be somewhat understated as it is based only on crude clinical assessments, incorporating validated ankle scores would strengthen this safety claim and improve comparability with existing PLT studies.

In conclusion, the authors are to be congratulated for presenting randomized research regarding the use of peroneus longus autografts and to state that, indeed, the results presented make it a legitimate choice for graft usage. Addressing the issues of sampling clarity, multiplicity, outcome definition, reporting of intention-to-treat, surgical standardization, and clinical versus statistical significance would further enhance the methodological robustness and interpretive balance of this valuable contribution.

Declaration of patient consent: The authors certify that they have obtained all appropriate patient consent forms. In the form, the patient has given the consent for his/ her images and other clinical information to be reported in the journal. The patient understands that his/ her names and initials will not be published and due efforts will be made to conceal their identity, but anonymity cannot be guaranteed.

Conflict of interest: Nil **Source of support:** None

References

1. Malik S, Biswas G, Singh SK, Sundaresan N, Bera AP, Kyada M. Comparative evaluation of peroneus longus tendon and hamstring tendon autografts in primary anterior cruciate ligament reconstruction: A randomized controlled trial. *J Orthop Case Rep* 2026;16:320-8.
2. Nascimento BF, Lima MB, Dias Júnior JM, Antunes Filho J, Campos TV, Mendes Júnior AF. Calculation of the minimal important clinical difference of the Lysholm and IKDC scores after anterior cruciate ligament reconstruction. *Rev Bras Ortop (Sao Paulo)* 2022;58:79-84.
3. Kumar K, Rao V, Panda AK, Joshi D. Peroneus longus tendon versus hamstring tendon autograft for primary anterior cruciate ligament reconstruction: A Systematic review and meta-analysis of comparative studies. *Orthop J Sports Med* 2025;13:3.
4. Van Eck CF, Schreiber VM, Mejia HA, Samuelsson K, Van Dijk CN, Karlsson J, et al. “Anatomic” anterior cruciate ligament reconstruction: A systematic review of surgical techniques and reporting of surgical data. *Arthroscopy* 2010;26 Suppl 9:S2-12.
5. Kotsifaki R, Korakakis V, King E, Barbosa O, Maree D, Pantouveris M, et al. Aspetar clinical practice guideline on rehabilitation after anterior cruciate ligament reconstruction. *Br J Sports Med* 2023;57:500-14.
6. Soleymanha M, Nejad AS, Keyhani S, Vosoughi F, LaPrade RF, Tollefson LV. Peroneus longus tendon harvest for ACL reconstruction yields good functional outcome of the ankle: A systematic review and meta-analysis. *Knee Surg Sports Traumatol Arthrosc* 2025;???:[3.1]:1-5.

Conflict of Interest: Nil
Source of Support: Nil

Consent: The authors confirm that informed consent was obtained from the patient for publication of this article

How to Cite this Article

Khatun A, Sharma S, Singh RR. Comparative Evaluation of Peroneus Longus Tendon and Hamstring Tendon Autografts in Primary Anterior Cruciate Ligament Reconstruction: A Randomized Controlled Trial. *Journal of Orthopaedic Case Reports* 2026 July;16(07): 601-602.

