

# An Unusual Case of Patellar Osteochondroma in an Elderly Woman: A Rare Site and Age of Presentation

Anurag Choudhary<sup>1</sup>, Gowtham Senguttuvan<sup>1</sup>, Lionel John<sup>1</sup>, Yogeshwar Agharkar<sup>1</sup>, Karthik Murugan<sup>1</sup>, S Arivoli<sup>1</sup>

## Learning Point of the Article:

Osteochondroma, though typically a tumor of younger individuals, should not be excluded from the differential diagnosis of knee pain in elderly patients. Symptomatic lesions, even in uncommon locations such as the infrapatellar region, can be effectively managed with surgical excision, leading to significant improvement in function and quality of life.

## Abstract

**Introduction:** Osteochondroma, a benign bone tumor commonly found in younger individuals, is seldom observed in older adults. This case report presents an atypical occurrence of an osteochondroma in a 65-year-old female, located in the infrapatellar region of the right knee. Clinical examination revealed a firm, non-tender mass in the infrapatellar area, accompanied by mild joint effusion and restricted range of motion. This case highlights the importance of including osteochondroma in the differential diagnosis for knee pain in elderly patients and demonstrates the effectiveness of surgical intervention in managing symptomatic lesions in uncommon anatomical locations.

**Case Report:** A 65-year-old female presented to the orthopedic outpatient department with a chief complaint of right knee pain and swelling that had progressively worsened over the last year. The pain was described as a dull ache, exacerbated by activity and partially relieved by rest. In addition, the patient experienced mechanical symptoms impacting her mobility and quality of life. Diagnostic imaging, including X-rays, magnetic resonance imaging, and computed tomography scans, confirmed an osteochondroma in the infrapatellar region, characterized by a bony outgrowth, with no signs suggesting malignant transformation. Due to the symptomatic nature and impact on the patient's quality of life, surgical excision was performed achieving complete removal of the lesion.

**Conclusion:** This case illustrates a rare presentation of infrapatellar osteochondroma in an elderly patient, highlighting that such lesions, though uncommon in older adults, should remain a differential consideration in cases of unexplained knee pain with mechanical symptoms. Timely diagnosis through appropriate imaging and surgical excision can lead to excellent symptomatic relief and functional recovery, even in atypical anatomical locations.

**Keywords:** Osteochondroma, elderly, infrapatellar.

## Introduction

Osteochondromas are benign bony projections covered with a cartilaginous cap, often arising from the metaphysis of long bones. They account for 20–50% of all benign bone tumors and are usually discovered in patients under 30 years [1,2]. The

occurrence in older adults is infrequent and poses diagnostic challenges, as symptoms can mimic more common degenerative joint diseases [3,4]. A rare case of Hoffa's osteochondroma arising in the infrapatellar fat pad was reported previously, which emphasized that such atypical presentations can occur beyond

## Author's Photo Gallery



Dr. Anurag Choudhary



Dr. Gowtham Senguttuvan



Dr. Lionel John



Dr. Yogeshwar Agharkar



Dr. Karthik Murugan



Dr. S Arivoli

Access this article online

Website:  
[www.jocr.co.in](http://www.jocr.co.in)

DOI:  
<https://doi.org/10.13107/jocr.2025.v15.i12.6452>

<sup>1</sup>Department of Orthopaedics, Sree Balaji Medical College and Hospital, Chennai, Tamil Nadu, India.

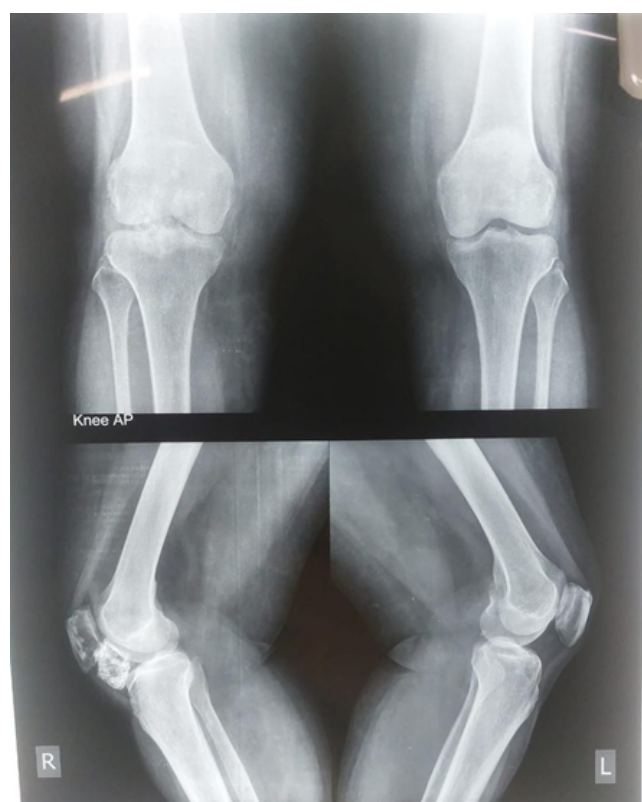### Address of Correspondence:

Dr. Yogeshwar Agharkar,  
Department of Orthopaedics, Sree Balaji Medical College and Hospital, Chennai, Tamil Nadu, India.  
E-mail: [yogeshwaragharkar1998@gmail.com](mailto:yogeshwaragharkar1998@gmail.com)

Submitted: 13/09/2025; Review: 05/10/2025; Accepted: November 2025; Published: December 2025

DOI: <https://doi.org/10.13107/jocr.2025.v15.i12.6452>

© The Author(s). 2025 Open Access. This article is distributed under the terms of the Creative Commons Attribution 4.0 International License (<https://creativecommons.org/licenses/by-nc/4.0/>), which permits unrestricted use, distribution, and non-commercial reproduction in any medium, provided you give appropriate credit to the original author(s) and the source, provide a link to the Creative Commons license, and indicate if changes were made. The Creative Commons Public Domain Dedication waiver (<http://creativecommons.org/publicdomain/zero/1.0/>) applies to the data made available in this article, unless otherwise stated.



**Figure 1:** Pre-operative X-ray.

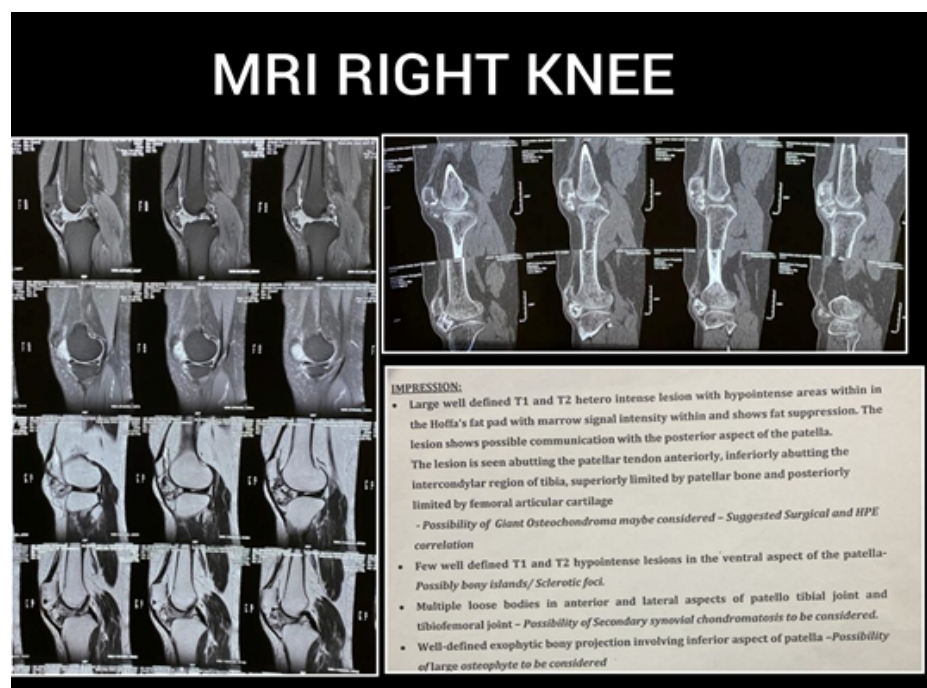
the usual age group and mimic other joint pathologies [5]. This case report aims to highlight the clinical features, diagnostic approach, and successful management of a rare presentation of

osteochondroma in the elderly, contributing valuable insights into its management.

### Case Report

A 65-year-old female presented to the orthopedic outpatient department with a chief complaint of right knee pain and swelling that had progressively worsened over the last year. The pain was described as a dull ache, exacerbated by activity and partially relieved by rest. In addition, the patient experienced mechanical symptoms impacting her mobility and quality of life. No significant past medical history. No history of trauma to the knee. No family history of bone tumors or hereditary multiple exostoses. Physical Examination revealed a visible swelling on the inferior aspect of the right knee, a firm, non-tender, immobile mass. Range of motion was limited, particularly in flexion. Neurovascular status of the limb was intact. Initial anteroposterior and lateral knee X-rays showed a well-defined, bony outgrowth from the inferior aspect of the patella (Fig. 1). Magnetic resonance imaging (MRI) provided detailed visualization, with no signs of malignant transformation or soft tissue involvement with cartilage cap thickness of 1.3 mm (Fig. 2). Computed tomography scan confirmed the continuity. Soft-tissue density lesion noted in the medial aspect of Hoffa's fat pad and knee joint with multiple loose bodies in anterior and lateral aspects of patella-tibial joint and tibiofemoral joint (Fig. 3). Synovial chondromatosis/osteochondroma may be considered. Diagnosis was based on clinical and imaging findings: An

osteochondroma of the posterior aspect of patella was confirmed. Given the patient's significant symptoms and the impact on her daily activities, surgical excision was deemed necessary. Surgical procedure: A medial parapatellar approach was used to access the lesion [6,7]. Excision: The osteochondroma was excised en bloc, ensuring complete removal of the cartilaginous cap. Intraoperative findings were consistent with pre-operative imaging. The wound was irrigated and closed in layers. Hemostasis was achieved, and the extensor mechanism was carefully preserved (Fig. 4). Post-operative care: The patient was placed in a knee immobilizer post-surgery. Pain management was achieved with oral analgesics. Patient was encouraged early mobilization with gentle knee bending



**Figure 2:** Magnetic resonance imaging right knee.



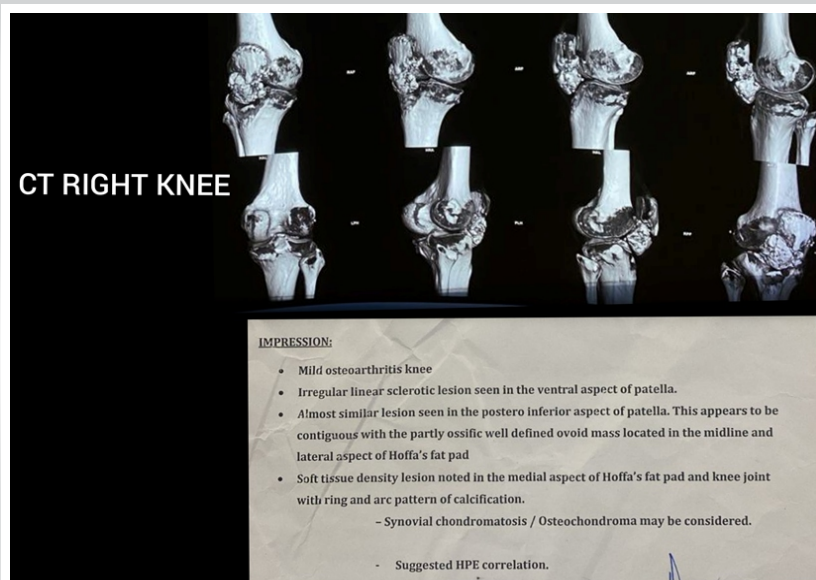


Figure 3: Computed tomography scan.

and quadriceps and hamstring exercises from pod 5. [L1.1] The patient was discharged with instructions for routine wound care and follow-up. At the 6-week follow-up, the patient reported marked reduction in pain and improved knee function. Physical examination showed no signs of recurrence, and the surgical site

was healing well. Radiographs confirmed the absence of residual lesion. Histopathological diagnosis confirmed possibility of osteochondroma with chronic synovitis with thinned out overlying cartilage (Fig. 5).

### Outcome and follow-up

At the 6-week follow-up, the patient reported a marked reduction in pain and improved knee function. Physical examination showed no signs of recurrence, and the surgical site was healing well. Radiographs confirmed the absence of residual lesion (Fig. 6) [Table 1].

### Discussion

This case highlights an unusual presentation of osteochondroma in an elderly patient, emphasizing the importance of considering benign bone tumors in differential diagnoses for knee pain and swelling in older adults. While osteochondromas commonly present in younger individuals, this case illustrates that they can remain asymptomatic until later in life or be discovered incidentally [

7,2,8] . Surgical excision remains the treatment of choice, especially for symptomatic lesions, and offers excellent outcomes when malignancy is not a concern [9,10]. Extrasynovial osteochondromas in the infrapatellar area are rare but clinically significant, as they may interfere with the extensor mechanism of the knee and limit mobility. The mechanical symptoms can mimic meniscal injuries or osteoarthritic changes, delaying accurate diagnosis [1,3]. Imaging, particularly MRI, is essential not only for identifying the lesion but also for assessing cartilage cap thickness, which helps rule out malignant transformation. Differential diagnosis includes synovial chondromatosis, Hoffa's disease, and loose bodies, which can be ruled out with MRI. Functional outcome assessment using the WOMAC scoring system demonstrated steady improvement in pain relief, stiffness reduction, and knee function over the follow-up period. This underscores the effectiveness of surgical excision and rehabilitation in restoring joint mechanics and quality of life, even in elderly patients [10,11] . This case highlights the

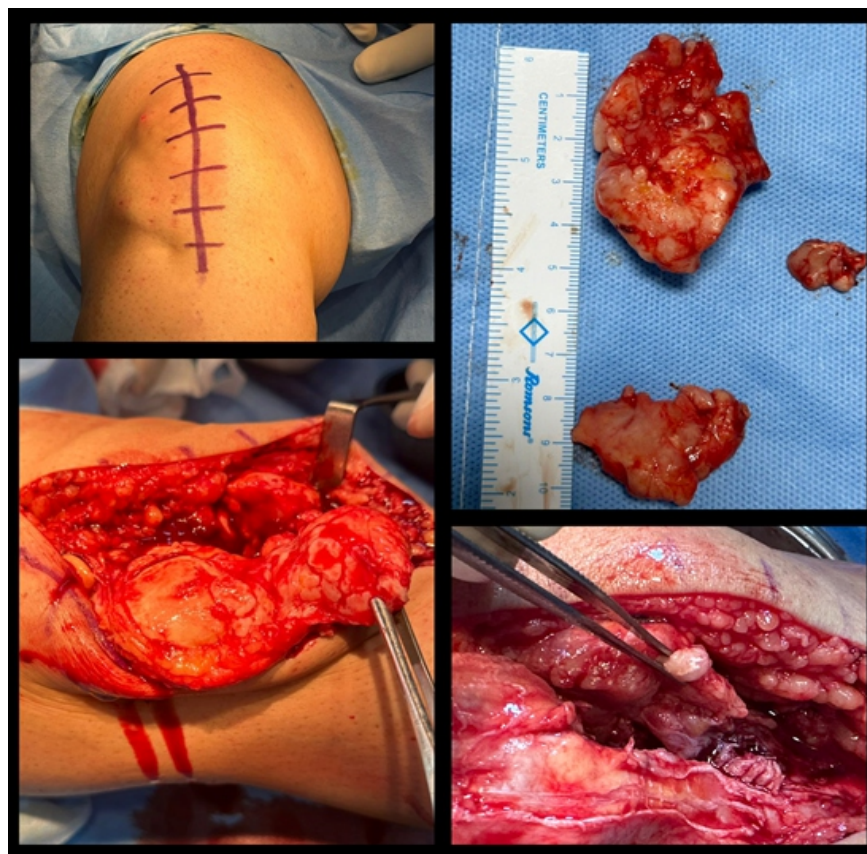

Figure 4: Intraoperative images.

**Microscopic Description:**

A1 A2, B1 to B3, BFB1 to BFB10 : Sections show interlacing bony trabeculae lined by thin cartilaginous cap at places and synovial lining elsewhere with extensive areas of fat necrosis in the interspersed soft tissue, with foamy histiocytes. Some nodules of osteocartilaginous tissue is seen. Overlying synovium shows mild chronic inflammation with synovial hyperplasia.

**IMPRESSION:**

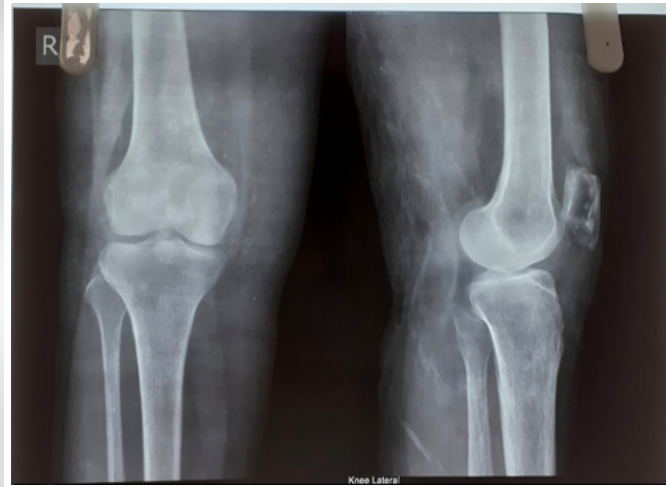RIGHT KNEE SYNOVIAL BIOPSY SHOWING MILD CHRONIC SYNOVITIS.

BONE LESION SHOWING MATURE BONE WITH THINNED OUT OVERLYING CARTILAGE AT PLACES.

**Comments:**

Possibility includes longstanding osteochondroma. Clinical and radiological correlation is suggested.

**Figure 5:** Histopathological report.



**Figure 6:** Post-operative X-ray.

**Table 1: Outcome and follow -up**

Follow-up interval	WOMAC score	Interpretation
6 weeks	38	Moderate symptoms, improving pain and stiffness
3 months	24	Mild symptoms, improved function, and mobility
6 months	14	Minimal pain or stiffness, near-normal daily activities
1 year	6	Excellent functional recovery, no recurrence noted

importance of considering osteochondroma in the differential diagnosis of persistent knee pain in elderly patients and supports surgical excision as a safe and effective intervention for symptomatic lesions [6,11,12].

### Conclusion

Osteochondromas, although rare in the elderly, should be considered in the differential diagnosis of knee pain and swelling. This case underscores the need for thorough clinical and radiological evaluation to ensure accurate diagnosis and effective treatment. Surgical excision of symptomatic osteochondromas provides significant relief and restores function, as demonstrated in this elderly patient. This report contributes to the limited literature on osteochondromas in older adults, offering insights into their management and outcomes. As this is a case report, a control group was not

feasible. Nonetheless, we have compared our findings with previously published literature describing alternative management strategies (observation, excision).

### Limitations of the Study

1. Single patient case report
2. Histological grading or immunohistochemistry was not performed due to resource limitations. However, routine histopathological analysis was conclusive of the diagnosis
3. Potential publication bias due to rare and successful cases is more likely to be reported, which can overestimate the ease of diagnosis or surgical success.

### Clinical Message

Osteochondroma is a common benign tumor in young patients but can rarely present in older adults, leading to diagnostic challenges. Infrapatellar localization is particularly uncommon and may mimic degenerative or inflammatory knee conditions. Careful imaging is essential to confirm the diagnosis and exclude malignant transformation. Surgical excision offers excellent outcomes in symptomatic cases, providing pain relief and functional recovery.

**Declaration of patient consent:** The authors certify that they have obtained all appropriate patient consent forms. In the form, the patient has given the consent for his/ her images and other clinical information to be reported in the journal. The patient understands that his/ her names and initials will not be published and due efforts will be made to conceal their identity, but anonymity cannot be guaranteed.

**Conflict of interest:** Nil **Source of support:** None

## References

1. Maheshwari AV, Jain AK, Dhammi IK. Extraskelatal para-articular osteochondroma of the knee – a case report and tumor overview. *Knee* 2006;13:411-4.
2. Helpert C, Davies AM, Evans N, Grimer RJ. Differential diagnosis of tumours and tumour-like lesions of the infrapatellar (Hoffa's) fat pad: Pictorial review with emphasis on MR imaging. *Eur Radiol* 2004;14:2337-46.
3. Milgram JW, Dunn EJ. Para-articular chondromas and osteochondromas: Report of 3 cases. *Clin Orthop* 1980;148:147-51.
4. Li C, Arger PH, Dalinka MK. Soft tissue osteochondroma: A report of three cases. *Skeletal Radiol* 1989;18:435-7.
5. Panta S, Thapa SK, Paudel KP, Kandel M, Adhikari BR. Hoffa's osteochondroma – para-articular extrasynovial infrapatellar fat pad osteochondroma: A case report. *J Nepal Med Assoc* 2021;59:799-801.
6. Turhan E, Doral MN, Atay AÖ, Demirel M. A giant extrasynovial osteochondroma in the infrapatellar fat pad: End stage Hoffa's disease. *Arch Orthop Trauma Surg* 2008;128:515-9.
7. Mittal A, Srinivasulu PS, Ramprasad R, Prasad YS. Osteochondroma at its rarest site. *J Orthop Case Rep* 2015;5:53-4.
8. Mosher JF Jr, Kettelkamp DB, Campbell CJ. Intracapsular or para-articular chondroma: A report of three cases. *J Bone Joint Surg Am* 1966;48:1561-9.
9. Takahashi M, Nishihara A, Ohishi T, Shiga K, Yamamoto K, Nagano A. Arthroscopic resection of an intra-articular osteochondroma of the knee in the patient with multiple osteochondromatosis. *Arthroscopy* 2004;20:28-31.
10. Sarmiento A, Elkins RW. Giant intra-articular osteochondroma of the knee. *J Bone Joint Surg Am* 1975;57:560-1.
11. Kitsoulis P, Galani V, Stefanaki K, Paraskevas G, Karatzias G, Agnantis NJ, et al. Osteochondromas: Review of the clinical, radiological and pathological features. *In Vivo* 2008;22:633-46.
12. Reith JD, Bauer TW, Joyce MJ. Paraarticular osteochondroma of the knee: Report of 2 cases and review of the literature. *Clin Orthop Relat Res* 1997;334:225-32.

**Conflict of Interest:** Nil

**Source of Support:** Nil

**Consent:** The authors confirm that informed consent was obtained from the patient for publication of this article

## How to Cite this Article

Choudhary A, Senguttuvan G, John L, Agharkar Y, Murugan K, Arivoli S. An Unusual Case of Patellar Osteochondroma in an Elderly Woman: A Rare Site and Age of Presentation. *Journal of Orthopaedic Case Reports* 2025 December;15(12): 57-61.

