

3D-Printed Spine Models for Planning Staged Minimally Invasive Transverse Process Resections for Bertolotti Syndrome: Technical Note

James P Caruso¹, Ammar Adenwalla¹, Nikit Venishetty², Mazin Al Tamimi¹, Carlos A Bagley¹,
Salah G Aoun¹

Learning Point of the Article:

We demonstrate the benefits of 3D-printed models in spine surgery, illustrating their role in pre- and post-operative planning, enhancing intraoperative efficiency, and increasing patient satisfaction, particularly in cases of Bertolotti syndrome.

Abstract

Background: Three-dimensional (3D) printing has enabled numerous advances in spine surgery execution and education. However, few examples exist to outline how this technology can aid the performance of complex spine surgery using minimally invasive surgery (MIS) techniques. Therefore, we present a case that illustrates the benefits of 3D-printed spine model production before and after correction of a congenital lumbosacral anomaly using an MIS approach.

Case Report: A 40-year-old woman with Bertolotti syndrome underwent a staged bilateral L6 MIS transverse process resection for the treatment of severe and progressive axial back pain which had repeatedly failed conservative management. 3D-printed spine models were used for pre- and post-operative surgical planning and patient counseling.

Conclusion: 3D-printed spine models can aid in the planning of complex spine cases suited for an MIS approach.

Keywords: 3D printing, anatomy, Bertolotti syndrome, minimally invasive, spine model.

Introduction

In recent years, minimally invasive spine surgery (MISS) approaches have become increasingly versatile and can be applied safely and successfully in a variety of complex spine pathologies [1]. The number of instrumented MISS procedures performed in the United States continues to increase [2], and cost savings can range from \$8,731 to \$9,295 for MIS compared to open spine surgeries [3]. In addition, MISS exposures can minimize the risk of approach-related complications and aid in post-operative quality of life improvement [1,4-6] since many patients who undergo MISS experience reduced risk of intraoperative and perioperative adverse outcomes, shorter

operative times, and earlier returns to work [6,7]. However, while MISS approaches may benefit patient recovery, smaller incisions and operative working windows can increase the complexity of cases with aberrant anatomy or congenital deformities.

To address these challenges, three-dimensional (3D) printing can serve as a helpful adjunct for surgical preparation and patient education [8], and many surgical subspecialties have adopted 3D-printing practices to improve pre- and intraoperative workflows [9-12]. However, the widespread use of 3D-printing applications in MISS can be limited by material cost, time, and a specialized market associated with the procedures [13]. To

Author's Photo Gallery



Dr. James P Caruso



Dr. Ammar Adenwalla



Dr. Nikit Venishetty



Dr. Mazin Al Tamimi



Dr. Carlos A Bagley



Dr. Salah G Aoun

Access this article online

Website:
www.jocr.co.in

DOI:
<https://doi.org/10.13107/jocr.2024.v14.i01.4152>

¹Department of Neurosurgery, The University of Texas Southwestern, Dallas, Texas,
²Paul L. Foster School of Medicine, Texas Tech Health Sciences Center El Paso, TX.

Address of Correspondence:

Dr. James P Caruso,

Department of Neurosurgery, The University of Texas Southwestern, 5151 Harry Hines Blvd, Dallas, Texas.

E-mail: james.caruso@phhs.org

Submitted: 20/10/2023; Review: 18/11/2023; Accepted: December 2023; Published: January 2024

DOI: <https://doi.org/10.13107/jocr.2024.v14.i01.4152>

This is an open access journal, and articles are distributed under the terms of the Creative Commons Attribution-NonCommercial-ShareAlike 4.0 License <https://creativecommons.org/licenses/by-nc-sa/4.0/>, which allows others to remix, tweak, and build upon the work non-commercially, as long as appropriate credit is given and the new creations are licensed under the identical terms

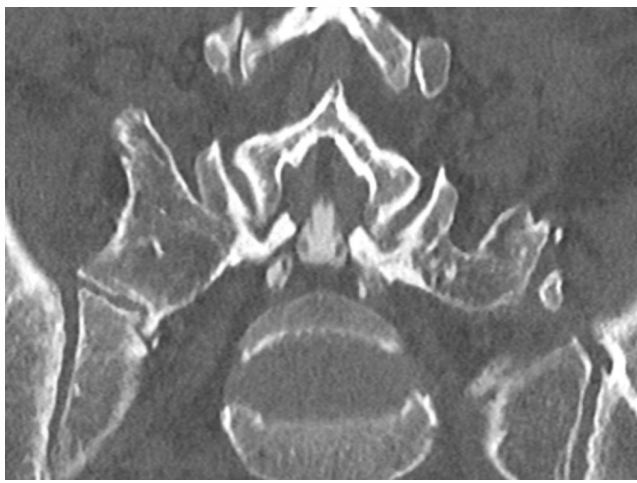


Figure 1: Pre-operative CT scan. Coronal CT image of pre-operative pathology. CT: Computed tomography.

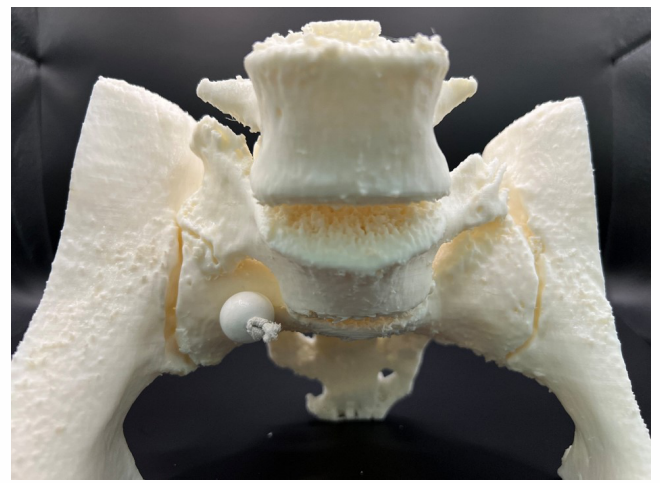


Figure 2: 3D-printed model anterior view. 3D-printed model of pre-operative lumbosacral spine – anterior view.

demonstrate the utility of 3D-printing in MISS, we present a rare case of Bertolotti syndrome requiring bilateral staged L6 transverse process (TP) resection, in which a 3D-printed models of the patient's lumbosacral spine were used for pre-, intra-, and post-operative surgical planning and patient education.

Case Report

A 40-year-old woman presented with over 10 years of axial back pain. Her pain significantly worsened with her last pregnancy a year prior, was refractory to maximal pharmacologic therapy and to repeated corticosteroid injections, which only provided her with a few days of relief, and limited her ability to ambulate and perform activities of daily living. On physical examination, paraspinal palpation at the level of the lumbosacral junction

elicited severe pain, worse on the left compared to the right. Her bilateral lower extremity strength and sensation were preserved. Computed tomography (CT) of her lumbar spine revealed six lumbar vertebrae, bilateral L6 TP hypertrophy with aberrant degenerative changes at sites of articulation with the posterior superior iliac spine (Fig. 1). Her aberrant connection between L6 and the pelvis was complex and multiplanar. To illustrate the patient's unique anatomy and aid in surgical planning, we produced a 3D-printed model of her lumbosacral spine (Fig. 2 and 3). After informed consent and discussion of risks, benefits, and alternatives, she underwent staged left and right MIS L6 TP resections using tubular retractors (Fig. 4). The left side was treated first, followed by the right side after significant improvement of her pain. We staged the procedure to ensure that the patient would respond to surgery before performing bilateral approaches. Postoperatively, the patient's pain improved significantly, and imaging revealed disconnection of the TP-pelvic articulation bilaterally, with a small residual connection on the right side which was surgically inaccessible. To aid in post-operative patient counseling, post-surgical 3D-printed spine models were also produced to illustrate the magnitude of bony removal (Fig. 5). Spine models were produced using standard 2 mm axial cuts from CT scans using open source software for quantitative image analysis and model generation and refinement. The models were made from polylactic acid with a polyvinyl alcohol scaffold, and each model took 9 days to produce using <\$40 off raw materials.

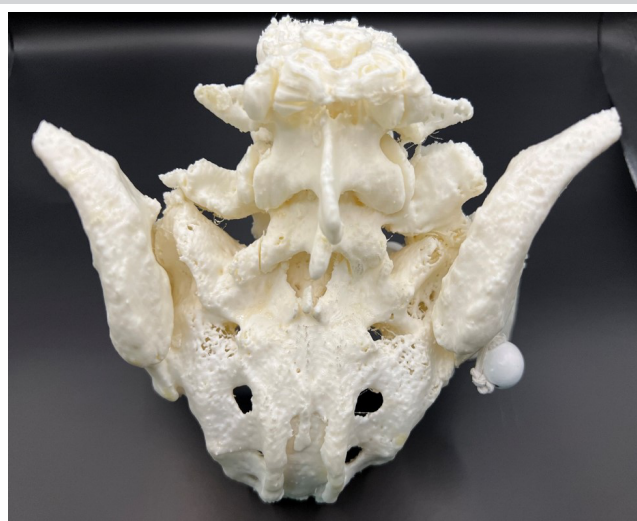

Figure 3: 3D-printed model posterior view. 3D-printed model of pre-operative lumbosacral spine – posterior view.

Discussion

Bertolotti syndrome often presents with chronic axial back pain [14]. Enlarged TPs at the caudal lumbar vertebral level develop anomalous articulations with the sacrum or ilium, leading to

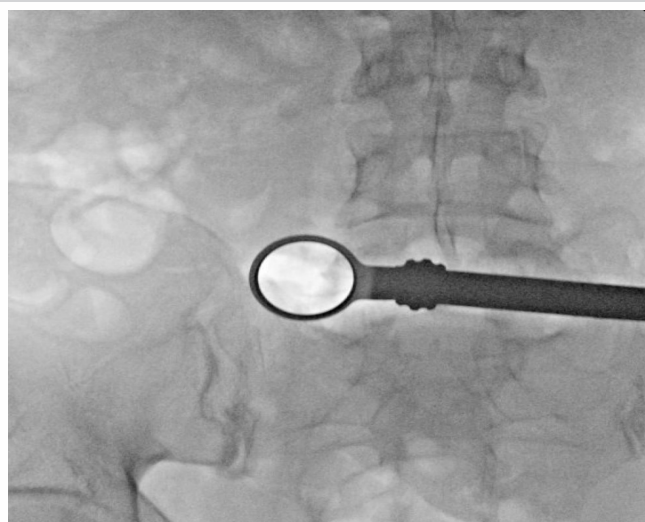

Figure 4: Intraoperative fluoroscopy. Intraoperative fluoroscopy demonstrating docking of tubular retractor.

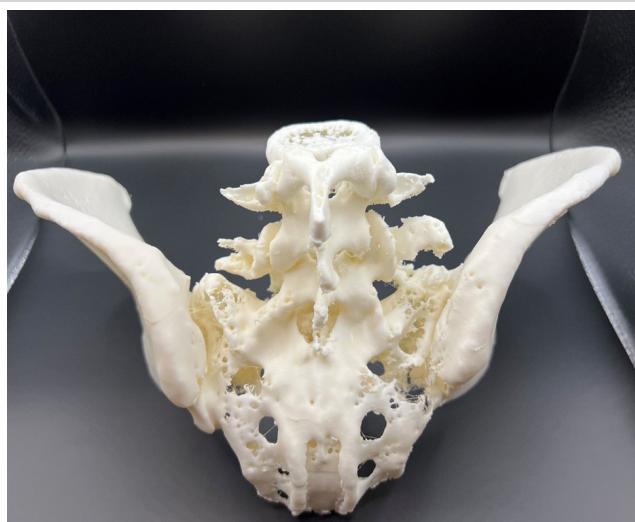

Figure 5: Post-operative lumbosacral spine.

accelerated lumbosacral degeneration and associated disk degeneration and discogenic pain and superior lumbar vertebral levels [14]. The underlying pathophysiology driving this process is unclear, but it often results in restricted range of motion and functional limitations. Surgical management consists of either lumbosacral fusion or resection of the hypertrophic TP, which can carry substantial complexity due to the associated aberrant congenital anatomy.

In this case, a 3D-printed full scale model of the patient's lumbosacral spine allowed the surgeons to better visualize the patient's anatomy to achieve an adequate degree of TP resection, which depended on precise docking of the tubular retractor along the TP during the approach adjacent to the iliac crest. During the procedure, we frequently referenced the model to ensure that we were docked adequately on the aberrant Bertolotti TP-pelvic articulation, rather than incorrectly on the sacroiliac joint. In addition, the minimal financial cost and time required to produce the models render them useful training tools when preparing for cases with unique anatomy. For specific cranial neurosurgery applications, augmented reality can provide a similar benefit [15], but a palpable intraoperative reference object provides superior tactile feedback. In addition, in the post-operative setting, the patient expressed gratitude for being able to directly visualize her anatomy using the model. While this feedback is anecdotal and informal, patient satisfaction is an essential component of

successful spine surgery, and introducing 3D-printed models in pre- and post-operative evaluations may promote this. 3D-printing applications in spine surgery continue to evolve, and further, progress is necessary to develop anatomically-faithful individualized 3D models that account for bone quality to better predict the likelihood of biomechanical success after spine surgery.

Conclusion

Low cost 3D-printed models can assist with anatomic visualization and patient counseling for MISS cases with complex or aberrant anatomy, and they are a useful tool to improve intraoperative workflow and patient satisfaction.

Clinical Message

In an effort to demonstrate the advantages of using three-dimensional (3D)-printed models in spine surgery, we present a case where 3D-printed spine models were used for pre- and post-operative surgical planning and patient counseling in a patient with Bertolotti syndrome. We show how 3D-printed models assist with visualizing complex anatomical features even when restricted by the smaller incisions and operative working windows of MIS spine surgery. These models are a useful tool to improve intraoperative workflow and patient satisfaction.

Declaration of patient consent: The authors certify that they have obtained all appropriate patient consent forms. In the form, the patient has given the consent for his/ her images and other clinical information to be reported in the journal. The patient understands that his/ her names and initials will not be published and due efforts will be made to conceal their identity, but anonymity cannot be guaranteed.

Conflict of interest: Nil **Source of support:** None

References

- Spetzger U, Von Schilling A, Winkler G, Wahrburg J, König A. The past, present and future of minimally invasive spine surgery: A review and speculative outlook. *Minim Invasive Ther Allied Technol* 2013;22:227-41.
- Phillips FM, Cheng I, Rampersaud YR, Akbarnia BA, Pimenta L, Rodgers WB, et al. Breaking through the “glass ceiling” of minimally invasive spine surgery. *Spine (Phila Pa 1976)* 2016;41:S39-43.
- Hopkins B, Mazmudar A, Kesavabhotla K, Patel AA. Economic value in minimally invasive spine surgery. *Curr Rev Musculoskelet Med* 2019;12:300-4.
- Bae J, Lee SH. Minimally invasive spinal surgery for adult spinal deformity. *Neurospine* 2018;15:18-24.
- Vaishnav AS, Othman YA, Virk SS, Gang CH, Qureshi SA. Current state of minimally invasive spine surgery. *J Spine Surg* 2019;5:S2-10.
- Yoon JW, Wang MY. The evolution of minimally invasive spine surgery: JNSPG 75th anniversary invited review article. *J Neurosurg Spine* 2019;30:149-58.
- Goldstein CL, Macwan K, Sundararajan K, Rampersaud YR. Perioperative outcomes and adverse events of minimally invasive versus open posterior lumbar fusion: Meta-analysis and systematic review. *J Neurosurg Spine* 2016;24:416-27.
- Yamaguchi JT, Hsu WK. Three-dimensional printing in minimally invasive spine surgery. *Curr Rev Musculoskelet Med* 2019;12:425-35.
- Yamada T, Osaka M, Uchimuro T, Yoon R, Morikawa T, Sugimoto M, et al. Three-dimensional printing of life-like models for simulation and training of minimally invasive cardiac surgery. *Innovations (Phila)* 2017;12:459-65.
- Barber SR, Kozin ED, Dedmon M, Lin BM, Lee K, Sinha S, et al. 3D-printed pediatric endoscopic ear surgery simulator for surgical training. *Int J Pediatr Otorhinolaryngol* 2016;90:113-8.
- Weinstock P, Rehder R, Prabhu SP, Forbes PW, Roussin CJ, Cohen AR. Creation of a novel simulator for minimally invasive neurosurgery: Fusion of 3D printing and special effects. *J Neurosurg Pediatr* 2017;20:1-9.
- Izatt MT, Thorpe PL, Thompson RG, D’Urso PS, Adam CJ, Earwaker JW, et al. The use of physical biomodelling in complex spinal surgery. *Eur Spine J* 2007;16:1507-18.
- Hsu MR, Haleem MS, Hsu W. 3D printing applications in minimally invasive spine surgery. *Minim Invasive Surg* 2018;2018:4760769.
- Crane J, Cragon R, O’Neill J, Berger AA, Kassem H, Sherman WF, et al. A comprehensive update of the treatment and management of Bertolotti’s syndrome: A best practices review. *Orthop Rev (Pavia)* 2021;13:24980.
- Sheth SA, Bijanki KR, Metzger B, Allawala A, Pirtle V, Adkinson JA, et al. Deep brain stimulation for depression informed by intracranial recordings. *Biol Psychiatry* 2022;92:246-51.

Conflict of Interest: Nil

Source of Support: Nil

Consent: The authors confirm that informed consent was obtained from the patient for publication of this case report

How to Cite this Article

Caruso JP, Adenwalla A, Venishetty N, Tamimi MA, Bagley CA, Aoun SG. 3D-Printed Spine Models for Planning Staged Minimally Invasive Transverse Process Resections for Bertolotti Syndrome: Technical Note. *Journal of Orthopaedic Case Reports* 2024 January;14(1):88-91.

