

A Rare Case of Burkholderia Osteomyelitis Affecting the Hip Joint in an Adult

B Jayakumar¹, Ajay James P¹

Learning Point of the Article:

Timely diagnosis and early aggressive surgical treatment with antibiotic cement beads is advocated to decrease the chronicity of the organism and decrease the morbidity.

Abstract

Introduction: Burkholderia pseudomallei is a gram-negative bacillus. It is predominant in Southeast Asia and Australia. Melioidosis of the hip joint is a very rare condition. This case report is to the best of our knowledge, the only study showcasing an acute proximal femoral osteomyelitis of the hip joint caused by Burkholderia pseudomallei.

Case Report: A 47-year-old male, a known case of diabetes mellitus since 7 years, presented with fever for 2 weeks and pain over left hip for 10 days. He gave a history of treatment for typhoid fever with multiple intravenous and intramuscular injections, 1 month before his present symptoms. On Examination: His left hip joint was tender and all movements of the hip were restricted. His blood investigations revealed high counts (TC=10,150), erythrocyte sedimentation rate (116), and a positive C-reactive protein (CRP). X-ray of the hip joint was normal. An magnetic resonance imaging (MRI) of the hip joint showed bone marrow edema and infiltrates of the left proximal femur, suggestive of an osteomyelitis. The patient was treated with an initial open bone biopsy and culture, which was reported as no growth. Due to persistent surgical site infection, a repeat pus culture and sensitivity yielded growth of Burkholderia pseudomallei. Hence, a wound debridement, bone curettage, and antibiotic cement bead application (Using vancomycin and tobramycin) was done. The wound healed well, and the CRP values and counts dropped rapidly to become normal. Oral cotrimoxazole was started as per the eradication regime. The cement beads were removed after 2 months. A repeat MRI done after 1 month showed that the collection in the left femur was resolving. The patient was treated with injection ceftazidime (1 g Iv Bd X 3 weeks) and was advised to continue oral cotrimoxazole for a total of 6 months.

Conclusion: Isolated bone infection caused by Burkholderia pseudomallei is probably underreported in India. It has a variable presentation and closely mimics tuberculosis. Its early diagnosis, early aggressive surgical treatment, and prolonged antibiotic administration are vital to prevent the chronicity of this infection and decrease the morbidity.

Keywords: Melioidosis, Burkholderia pseudomallei, Burkholderia osteomyelitis, osteomyelitis.

Introduction

Burkholderia pseudomallei is a Gram-negative bacillus, which is a free-living saprophyte. It was first described by Whitmore and Krishnaswami in morphea addicts in Burma [1]. The spread of organism is caused by inhalation, ingestion, or inoculation. It causes a spectrum of diseases ranging from pneumonia to cutaneous

abscess, gastrointestinal abscess, genitourinary infections, and skeletal infections. The disease caused by Burkholderia pseudomallei is called Melioidosis. The risk factors for this disease are diabetes mellitus, alcohol intake, chronic renal failure, and prolonged steroid therapy. Skeletal infections though uncommon have been recorded in the literature. Melioidosis is predominant in

Author's Photo Gallery



Dr. B Jayakumar



Dr. Ajay James P

Access this article online

Website:
www.jocr.co.in

DOI:
<https://doi.org/10.13107/jocr.2022.v12.i12.3472>

¹Department of Orthopaedics, Aarupadai Veedu Medical College, Puducherry, India.

Address of Correspondence:

Dr. Ajay James P,
Department of Orthopaedics, Aarupadai Veedu Medical College, Puducherry - 607 402, India.
E-mail: ajaypeter18@gmail.com

Submitted: 18/09/2022; Review: 08/10/2022; Accepted: November 2022; Published: December 2022

DOI: <https://doi.org/10.13107/jocr.2022.v12.i12.3472>

This is an open access journal, and articles are distributed under the terms of the Creative Commons Attribution-NonCommercial-ShareAlike 4.0 License <https://creativecommons.org/licenses/by-nc-sa/4.0/>, which allows others to remix, tweak, and build upon the work non-commercially, as long as appropriate credit is given and the new creations are licensed under the identical terms



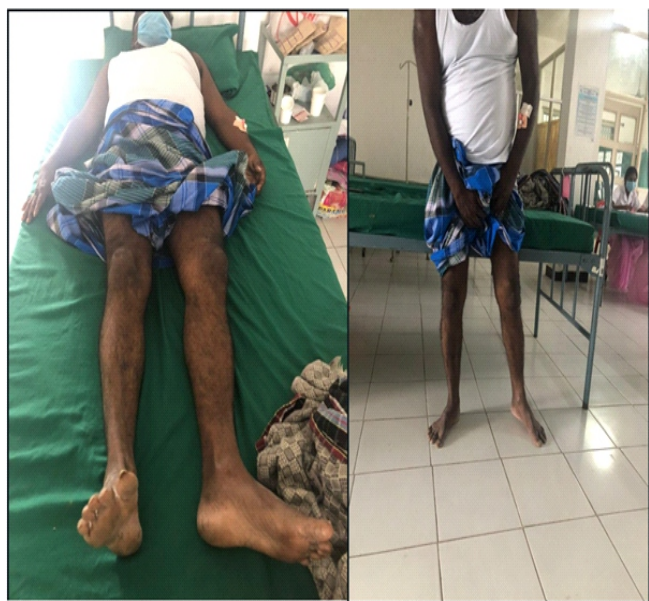

Figure 1: Affected lower limb in external rotation.

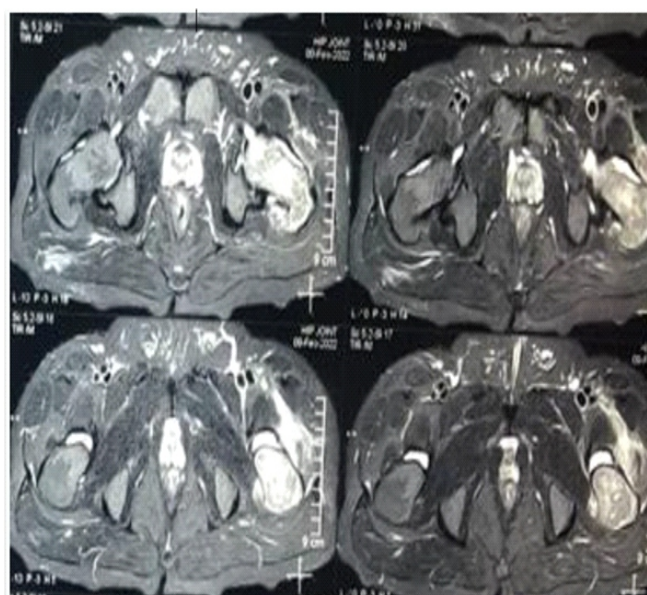


Figure 2: MRI of left proximal femur showing bone marrow edema and infiltrates.

some regions of Australia and Southeast Asia.

Case Report

We report a 47-year-old male patient who is a known diabetic for past 7 years on oral hypoglycemic agents with complaints of fever for 2 weeks and pain over the left hip for the past 10 days. The fever was intermittent and of low-grade type. The patient complained of an evening rise of temperature. The pain was insidious in onset and was initially mild but progressed to become very severe and throbbing in nature, thus rendering him unable to weight bear and move his affected limb properly. The patient also gave a history of treatment in a local hospital 1 month before his present symptoms for a suspected typhoid fever, during which time, he was treated with antibiotics and received an intramuscular injection over his left buttock.

On Examination

There was local rise of temperature over the left groin. Multiple tender and non-matted inguinal lymph nodes were palpable. The left lower limb was kept in an attitude of external rotation (Fig. 1). There appeared to be an area of 5 × 5 cm induration over left gluteal region. Anterior and posterior joint line tenderness was present. There was no apparent or true shortening. The range of movements was as follows: Flexion of 0–30° was possible beyond, in which movements were restricted by severe pain and spasm. The limb was placed in an attitude of 60° external rotation and could be internally rotated only until neutral position, beyond which further movements were restricted by pain and spasm. Extension was possible up to 10° but with associated pain. Abduction of 25 degrees and adduction of 20° was possible with associated pain.

He was admitted and his blood investigations revealed elevated

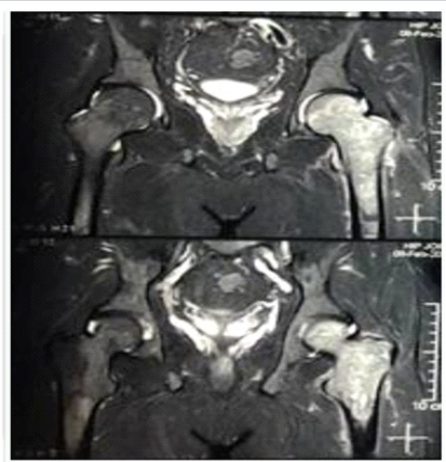


Figure 3: MRI suggestive of left proximal femur osteomyelitis.

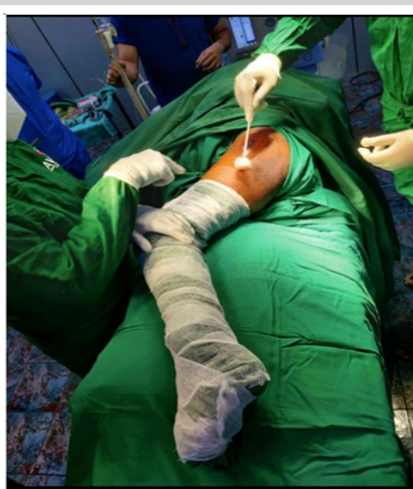

Figure 4: The position of the patient during surgery and approach.

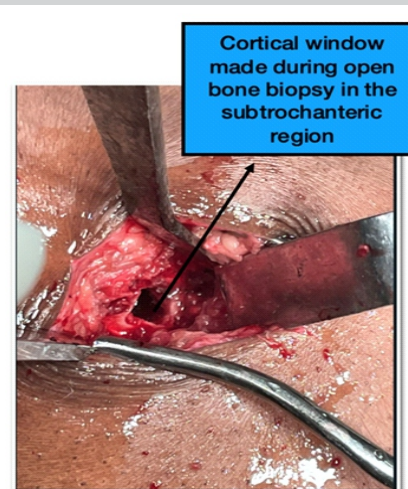


Figure 5: Cortical window after the initial bone biopsy.

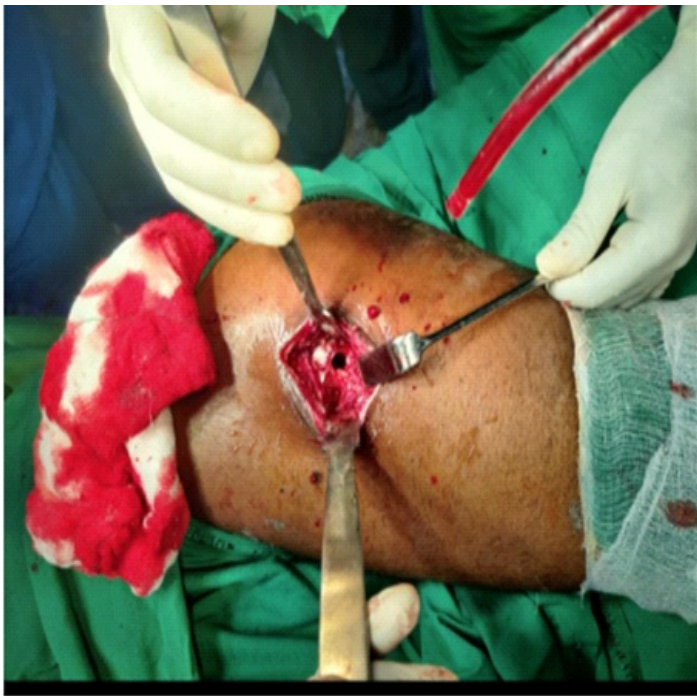

Figure 6: The cortical window during the second surgical procedure within which antibiotic cement beads were applied.




Figure 7: Antibiotic cement beads passed over a stainless steel wire.

counts (TC=10,150), high erythrocyte sedimentation rate (ESR) (116), and a positive C-reactive protein (CRP). His blood culture and urine culture were negative. A Mantoux test was done and was negative. A surgery opinion was sought in view of the induration on posterior aspect of the left buttock to rule out an underlying injection abscess. An USG of the gluteal region was done and was normal. X-ray of the hip joint appeared to be normal. The patient was started on IV antibiotics (Injection cefotaxime 1 g IV BD) and analgesics. In spite of a mild relief of pain, the patient continued to complain of a low grade, intermittent fever in the evenings and his repeat blood counts, even after 5 days of initiating treatment were high (TC=12440/CU mm and ESR =118). Hence, an magnetic resonance imaging (MRI) of the hip joint was done which showed

evidence of bone marrow edema and infiltrates in the proximal femur suggestive of an osteomyelitis (Fig. 2 and 3).

The patient was posted for an open bone biopsy and bone curettage under spinal anesthesia. A direct lateral approach to hip was done (Fig. 4) and after making a cortical window in the subtrochanteric region using multiple drill bits and an osteotome, the infected soft tissue and bone curettage specimen were sent for histopathology study (Fig. 5). The pus and infected tissues were sent for culture. The tissue and pus culture were reported to have no growth. The patient however had some relief of symptoms with decrease in pain. The patient was immobilized with a de-rotation boot to discourage him from pre-mature weight bearing, so as to avoid an iatrogenic

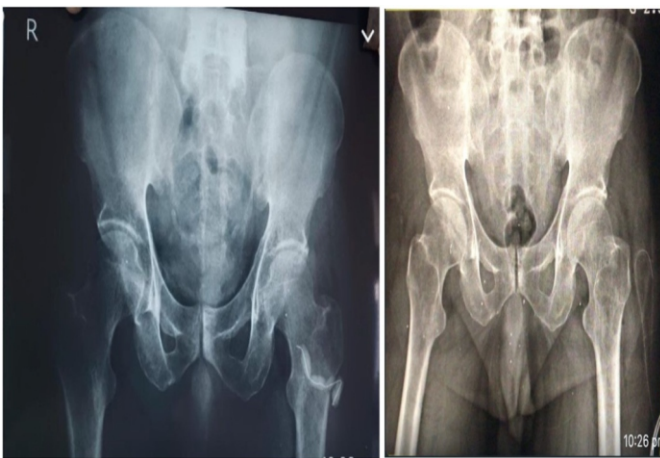


Figure 8: Pre-operative and post-operative X-ray before and after cement bead removal.

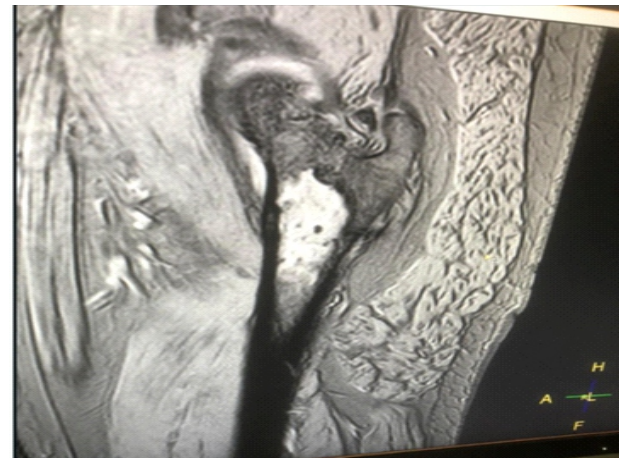


Figure 9: An intramedullary abscess which is resolving on repeat MRI.

subtrochanteric fracture. He was treated by regular wound care, dressings, and iv antibiotics (Inj Taxim) in the post-operative period. He had persistent pain and severe pus discharge from the surgical site from the 5th post-operative day onward. Aspiration of the surgical site was done using a syringe under sterile conditions and about 5 mL of pus was sent for culture. It was reported as *Burkholderia pseudomallei*. A computed tomography chest and USG of abdomen were done to rule out other foci of infection and were found to be normal.

As the surgical wound had copious pus discharge and as the CRP values continued to be positive in spite of the falling WBC counts, the patient was posted for a second surgical procedure. A wound debridement, bone curettage, and antibiotic cement bead application passed over a stainless steel wire containing 2 g of vancomycin and 2.4 g of tobramycin in 40 g of bone cement was done (Fig. 6 and 7). The bone curettage specimen and infected soft tissue were sent for histopathology and culture and sensitivity.

Following the second surgical procedure, the patient received IV antibiotics (Inj Piptaz for a total of 2 weeks postoperatively) and Tab Cotrimoxazole (160 mg BD) until date of discharge. Tab Cotrimoxazole was planned for a total minimum dosage of 6 months as per the recommended eradication regime for Melioidosis. The CRP dropped and became negative within a week following the second surgery and initiation of antibiotics. The patient's wound healed well after the second procedure and patient was discharged after suture removal.

The patient continued his follow-up in our hospital on a weekly basis and was on antibiotic therapy as planned (Tab Cotrimoxazole 160 mg BD and Tab. Ciprofloxacin 500 mg Bd). He had no episodes of fever but presented with a sinus on the proximal edge of the healed scar 3 weeks after the date of discharge, with a mild serous discharge. This healed with regular dressings, antibiotics, and glycemic control within a week's time.

He had no episodes of recurring sinuses after this. The patient was posted for removal of the antibiotic cement beads after 2 months. The beads were removed along with the SS wire in entirety under C-arm guidance (Fig. 8). The surgical wound healed well in post-operative period and he was sent home with the advice of non-weight-bearing mobilization with walker and to continue his oral antibiotics.

After 1 month, the patient was reviewed and was found to have no episodes of fever, pain, or sinus discharge after the cement bead removal. His blood counts and CRP values were also normal. A repeat MRI scan of both the hip joints and left femur was taken (Fig. 9). A 49 × 21 mm collection in the metadiaphyseal region suggestive of a likely resolving abscess was reported, subject to clinical correlation. As patient was asymptomatic and all his blood investigations were normal, he was treated conservatively with injection Ceftazidime 1 g IV BD for 3 weeks and Tab Cotrimoxazole (160 mg BD) was continued.

Discussion

In this case, given the background of treatment for a typhoid fever and having received multiple IV injections and an intramuscular gluteal injection, we considered the possibilities of a *Salmonella* osteomyelitis or reactive arthritis. We also did an USG of the left gluteal region and got a surgeon's opinion to rule out a gluteal abscess. Tuberculin test was also negative. We hence agree with other authors in aptly naming melioidosis as a great mimicker [2, 3].

Our study is unique as the hip joint is not commonly involved. We however did find some parallels to a study by Iyengar et al., where the patient profile, risk factors, presentation, and blood picture (high ESR >110) matched closely with ours [4]. The knee joint is said to be the most involved [5], whereas, in our case, hip joint is involved. This case is to the best of our knowledge, the only case report showcasing an acute *Burkholderia* osteomyelitis of proximal femur in an adult that is available in literature.

Diagnosis must be considered for those who are returning from endemic areas [6]. Melioidosis is considered endemic in the regions of Thailand and Northern Australia [7]. The Skeletal infection occurs usually secondary to an infection from elsewhere, although primary bone infections are also recorded in the literature [8].

In our case report, the initial cultures were negative, which may be due to a prolonged antibiotic therapy before his presentation to our hospital. A similar picture where most of the initial cultures were negative, but subsequently turned positive was reported in the study by Pandey et al. [9]

Our case also required repetitive surgical procedures, for debulking of the infected tissue and pus for the treatment. This is similar to the case reports described by the authors Morse et al., which also required multiple surgeries, ranging from arthrotomies and washout to sequestrectomy and cement bead application for treatment [8]. We assume that our early surgical intervention was instrumental in treating the patient, thereby avoiding the complications of a possible sequestrum formation, chronicity and prolonged treatment which would add to the morbidity of the patient.

The repeat MRI taken 4 months after treatment showed a possible abscess which has drastically reduced in comparison with the previous MRI scan, we thereby infer the effectiveness of the response to our treatment and therefore continued with our medical line of management.

The presence of persistent changes in the repeat MRI scan in our case is similar to a study by Morse et al., wherein the repeat MRI and CT showed radiological changes even after several weeks of initiation of treatment. This we believe is the inherent nature of the organism to cause a long-standing disease.

The most common risk factors are diabetes mellitus, alcoholism, thalassemia, chronic renal failure, male gender, and contact with water bodies [10]. Diabetes mellitus seems to be the most common

associated risk factor.

The recommended treatment regime advocated is to use ceftazidime, carbapenems, or imipenem for a period of 2–4 weeks followed by an eradication regime of cotrimoxazole for 3–5 months [11].

Some authors advocate the role of G-CSF in Melioidosis. It reduces the mortality rate of septicemia in Melioidosis [12]. However, the effectiveness is unclear as some studies show that, G-CSF does not directly reduce the mortality rate but buys important time and prolongs the life of the patient by improving the neutrophil function during sepsis. Thus, it facilitates to make important lifesaving decisions [13].

Conclusion

We conclude that isolated musculoskeletal infections caused by Burkholderia species, though rare, are probably under-reported

in India. It closely imitates several diseases, especially tuberculosis and its presentation is often variable and atypical. Its early diagnosis and aggressive treatment are necessary, given the long-standing inherent nature of the organism and its resistance to many antibiotics. Repeat MRI done, 4–6 months after treatment is a useful tool to assess the effectiveness of treatment and plan further. We believe that surgery coupled with antibiotic cement beads application is an extremely effective modality of treatment.

Clinical Message

We advocate to consider Melioidosis as an important differential diagnosis in all atypical cases with a variable presentation in the subcontinent. We stress on the importance of early aggressive surgical treatment and antibiotics, to decrease the chronicity of the organism and morbidity in patient.

Declaration of patient consent: The authors certify that they have obtained all appropriate patient consent forms. In the form, the patient has given the consent for his/ her images and other clinical information to be reported in the journal. The patient understands that his/ her names and initials will not be published and due efforts will be made to conceal their identity, but anonymity cannot be guaranteed.

Conflict of interest: Nil **Source of support:** None

References

- Whitmore A, Krishnaswami CS. An account of the discovery of a hithertoun described infective disease occurring among the population of Rangoon. *Indian Med Gaz* 1912;47:262-7.
- Yee KC, Lee MK, Chua CT, Puthuchear SD. Melioidosis, the great mimicker: A report of 10 cases from Malaysia. *J Trop Med Hyg* 1988;91:249-54.
- Singh M, Mahmood M. Melioidosis: The great mimicker. *J Community Hosp Intern Med Prospect* 2017;7:245-7.
- Iyengar R, Manikanta MD, Goveen M. Chronic osteomyelitis of the femur caused by Burkholderia pseudomallei in a patient with Type 2 diabetes mellitus. *J Clin Sci Res* 2021;10:43-6.
- Kosuwon W, Taimglang T, Sirichativapee W, Jeeravipoolvarn P. Melioidotic septic arthritis and its risk factors. *J Bone Joint Surg Am* 2003;85:1058-61.
- Thin RN, Brown M, Stewart JB, Garrett CJ. Melioidosis: A report of ten cases. *QJ Med* 1970;39:115-27.
- Currie BJ, Fisher DA, Howard DM, Burrow JN, Lo D, Selva-Nayagam S, et al. Endemic melioidosis in tropical Northern Australia: A 10 year prospective study and review of literature. *Clin Infect Dis* 2000;31:981-6.
- Morse LP, Smith J, Mehta J, Ward L, Cheng AC, Currie BJ. Osteomyelitis and septic arthritis from infections with Burkholderia pseudomallei: A 20 year prospective melioidosis study from northern Australia. *J Orthop* 2013;10:86-91.
- Pandey V, Rao SP, Rao S, Acharya KK, Chhabra SS. Burkholderia pseudomallei musculoskeletal infections (melioidosis) in India. *Indian J Orthop* 2010;44:216-20.
- Cheng AC, Currie BJ. Melioidosis: Epidemiology, pathophysiology and management. *Clin Microbiol Rev* 2005;18:383-416.
- Inglis TJ. The treatment of melioidosis. *Pharmaceuticals (Basel)* 2010;3:1296-303.
- Cheng AC, Stephen DP, Anstey NM, Currie BJ. Adjuvant granulocyte-colony stimulating factor for treatment of septic shock in melioidosis. *Clin Infect Dis* 2004;38:32-7.
- Cheng AC, Limmathurotsakul D, Chierakul W, Getchalarat N, Wuthiekanun V, Stephens DP, et al. A randomized control trial for treatment of severe sepsis due to melioidosis in Thailand. *Clin Infect Dis* 2007;45:308-14.

Conflict of Interest: Nil
Source of Support: Nil

Consent: The authors confirm that informed consent was obtained from the patient for publication of this case report

How to Cite this Article

Jayakumar B, James AP. A Rare Case of Burkholderia Osteomyelitis Affecting the Hip joint in an Adult. *Journal of Orthopaedic Case Reports* 2022 December;12(12):77-81.

