

Arthroscopic Salvage Procedure for Iatrogenic Conjoint Tendon Avulsion Fracture Following Arthroscopic Latarjet Procedure Using Double Sling Fixation Technique – A Case Report

Ayyappan V Nair¹, Pramod Kumar Mohan¹, Ajit Jangale¹, Pavan Krishna¹, Naresh Goud¹

Learning Point of the Article:

Iatrogenic coracoid graft fractures during arthroscopic Latarjet procedure can be salvaged maintaining the triple effect of the Latarjet – the bone block effect, the sling effect, and capsulolabral effect.

Abstract

Introduction: We present a case report of an iatrogenic conjoint tendon avulsion fracture following arthroscopic Latarjet and salvage technique to address the complication with a novel double sling technique.

Case Report: A 16-year-old male patient who presented with recurrent instability of the right shoulder was counseled for an arthroscopic Latarjet procedure, taking account of critical glenoid bone loss and his contact sporting activities. An intraoperative coracoid tip fracture occurred, which was managed with the double sling technique. At 1-year follow-up, the patient has made a good recovery with a full range of movements and a stable shoulder; the CT scans showed a well-approximated coracoid tip fragment.

Conclusion: Iatrogenic intraoperative coracoid graft fractures during arthroscopic Latarjet can be managed depending on the site of the fracture and quality of the bone. The double sling fixation technique helps in maintaining the sling action of the conjoint tendon in patients with recurrent instability.

Keywords: Latarjet, Coracoid graft fracture, Arthroscopy, Shoulder surgery, Instability, Graft salvage.

Introduction

Arthroscopic Latarjet is technically demanding and has a steep learning curve providing good union rates and minimal complications with less bleeding, less post-operative pain, and can also deal with associated shoulder pathology and better cosmesis [1]. The complications of arthroscopic Latarjet are similar to those of open Latarjet and include neurovascular complications due to its proximity, graft-related complications, implant-related complications, stiffness, and infection [2, 3]. Athwal et al. have described intraoperative graft fracture in their

list of complications but post-operative graft failure has been rarely described [4]. We present a case report of an iatrogenic conjoint tendon avulsion fracture following arthroscopic Latarjet and a novel double sling technique to salvage the coracoid graft.

Case Report

A 16-year-old male patient who was a college basketball player presented with recurrent anterior shoulder instability of the right shoulder for the past 2 years. He had multiple episodes of

Access this article online

Website:
www.jocr.co.in

DOI:
<https://doi.org/10.13107/jocr.2023.v13.i09.3884>

Author's Photo Gallery



Dr. Ayyappan V Nair



Dr. Pramod Kumar Mohan



Dr. Ajit Jangale



Dr. Pavan Krishna



Dr. Naresh Goud

¹Department of Shoulder and Sports Injury, Bangalore Shoulder Institute, Bengaluru, Karnataka, India.

Address of Correspondence:

Dr. Pramod Kumar Mohan,
Department of Shoulder and Sports Injury, Bangalore Shoulder Institute, Bengaluru, Karnataka, India.
E-mail: pramod.stanley@gmail.com

Submitted: 01/06/2023; Review: 10/07/2023; Accepted: Aug 2023; Published: September 2023

DOI: <https://doi.org/10.13107/jocr.2023.v13.i09.3884>

This is an open access journal, and articles are distributed under the terms of the Creative Commons Attribution-NonCommercial-ShareAlike 4.0 License <https://creativecommons.org/licenses/by-nc-sa/4.0/>, which allows others to remix, tweak, and build upon the work non-commercially, as long as appropriate credit is given and the new creations are licensed under the identical terms

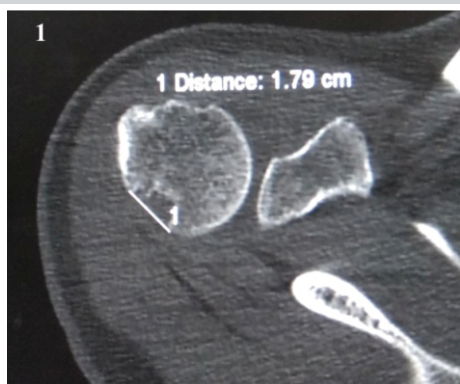

Figure 1: CT scan showing 20% of glenoid bone loss with an engaging hill sach's lesion.

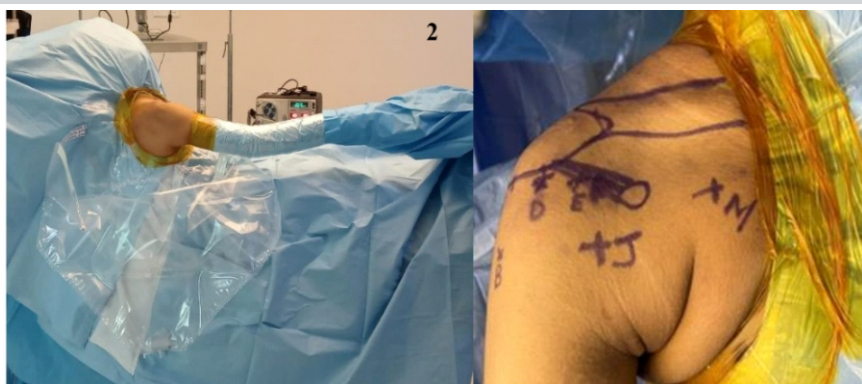

Figure 2: Patient positioning and portal placement.

dislocation; the most recent episode was 1 month before he presented to us. On clinical examination, the patient had a full range of motion and had a positive apprehension test for instability. Radiological screening with CT and MRI showed glenoid bone loss of 20% and engaging Hill Sachs lesions (Fig. 1). Considering the critical glenoid bone loss with engaging Hill Sach lesion and being a contact sport athlete, he was counseled for arthroscopic Latarjet procedure with remplissage of the Hill Sach lesion.

Surgical technique

Patient positioning and portal placement

Under general anesthesia and an interscalene block, the patient is positioned in a beach chair position. The arm is prepped and

draped held by traction cable with the shoulder in 60° anterior elevation, 10° shoulder abduction and neutral rotation (Fig. 2).

Portal placement (Fig. 2)

A portal: Standard posterior portal known as soft spot, 2 cm medial and inferior from the posterolateral corner of the acromion. Used for visualization and passing switching stick for subscapularis split.

E portal: In the rotator interval, made with the outside-in technique just above the lateral half of the subscapularis.

D portal: Lateral portal made anterior to the long head of the biceps. Used for instruments during coracoid preparation and coracoid osteotomy. Furthermore, used for visualization during

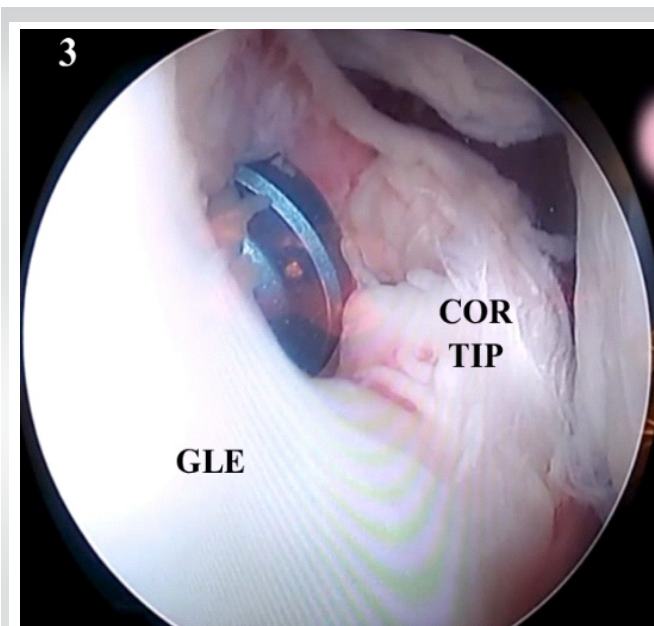


Figure 3: Viewing from the J portal, the free-floating fractured distal tip of the coracoid graft, along with the conjoint tendon with the intact metallic screws visualised. COR TIP: Coracoid tip, GLE: Glenoid face.

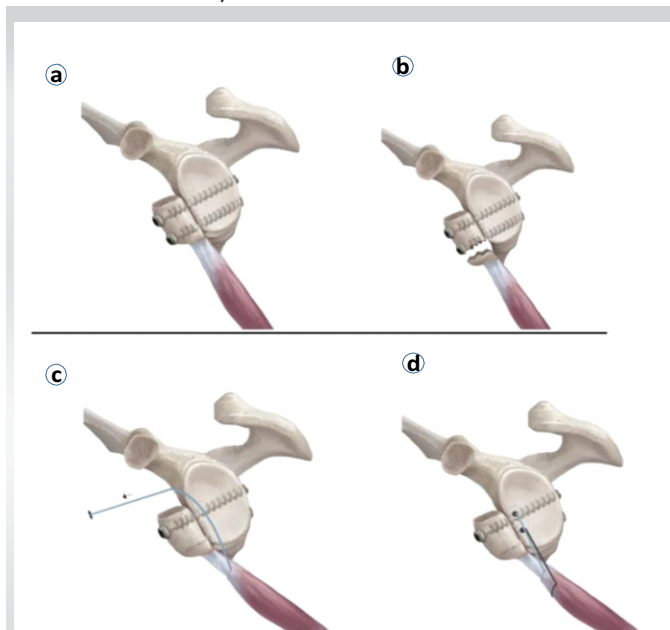


Figure 4: The animated surgical technique of double sling fixation of graft fracture fixation. (a) Well-positioned coracoid bone block after screw fixation. (b) Fractured coracoid tip with conjoint tendon origin beneath alpha screw. (c) Reduced coracoid tip fracture using proximal sling suture. (d) Well-approximated coracoid tip and suture slings anchored to glenoid with 2.7 mm pushlock anchors.

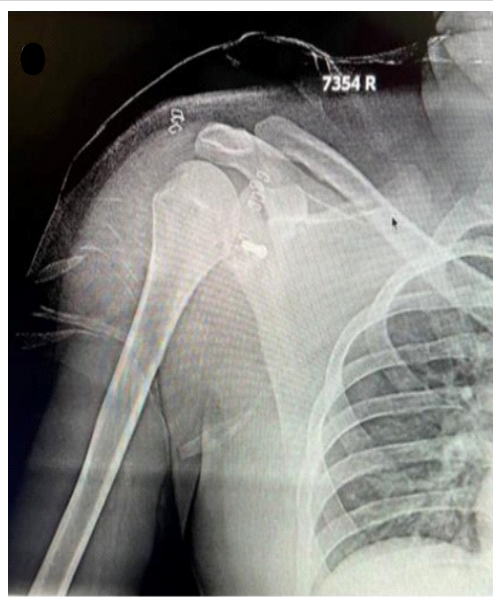

Figure 5: Post-operative X-ray showing well-positioned bone block with a single screw.

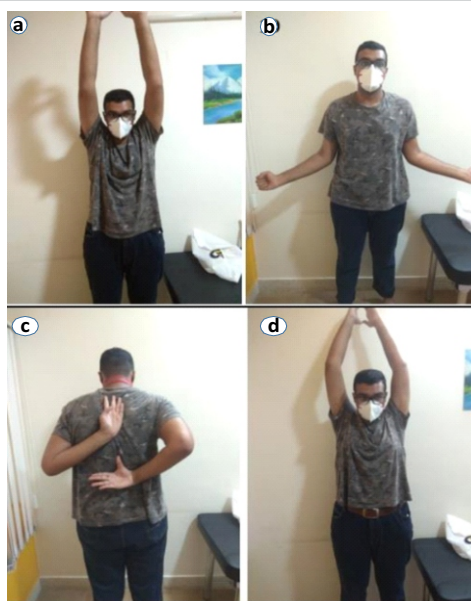

Figure 6: (a-d) 3 month follow-up after the second surgery with an almost full range of movements.

Surgical steps

The arthroscopic Latarjet procedure as described by Lafosse was performed. Remplissage of the Hill Sach lesion was performed with a triple-loaded all-suture anchor (Stryker, India). The coracoid graft was prepared, osteotomized, and transferred through the subscapularis split. The coracoid graft fixation was carried out with two cannulated metal screws (Depuy-Mitek) and tightening of the screws was performed. While tightening the alpha screw, we encountered an iatrogenic fracture of the coracoid graft below the alpha screw causing a free floating fracture of the distal tip of the coracoid graft

the shoulder’s anterior access, exposure, subscapularis split, and fixation of the graft.

H Portal: Anterosuperior portal above coracoid. Used for coracoid drilling and coracoid osteotomy.

J portal: Anteroinferior portal above subscapularis. Used for visualization during the preparation, osteotomy, and transfer of the coracoid graft.

I portal: Ancillary portal. Used to make the subscapularis split, also used for visualization during the preparation of the coracoid holes.

M portal: Anterior portal made medial to the conjoint tendon. Used for the pectoralis minor tendon release and double-barrel coracoid positioning cannula.

along with the conjoint tendon (Fig. 3).

The alpha screw was removed with the MITEK arthroscopic screwdriver. Refixation of the conjoint tendon with the inferior coracoid tip was done with a novel double sling technique. The conjoint tendon was secured with cinch sutures using a fiber wire loaded on the Arthrex scorpion suture passer at the proximal aspect of the conjoint tendon and traction load was given to the proximal suture sling. The conjoint tendon along the bone fragment was approximated to the remaining bone block. Second sling fixation was done using a similar technique, cinch sutures are taken distally to the initial sutures and anchored at 5.30 O’clock position using push-lock while maintaining traction on the proximal suture sling. The proximal suture sling was anchored to the 3.30 O’clock position. (Fig. 4a-d) shows the animated surgical technique of double sling fixation of graft fracture fixation. Intraoperatively fractured coracoid tip, along with conjoint tendon was found stable as the shoulder is put through all range of movements. (Fig. 5) shows a post-operative X-ray showing a well-positioned bone block with a single screw. Post-surgery, the patient was immobilized for 2 weeks and rehabilitation was started gradually as per standard protocol followed for arthroscopic Latarjet.

Outcome

The patient was followed up at 3 months and 6 months. At end of the 3-month follow-up visit, the patient had full ROM and no instability. (Fig. 6a-d)

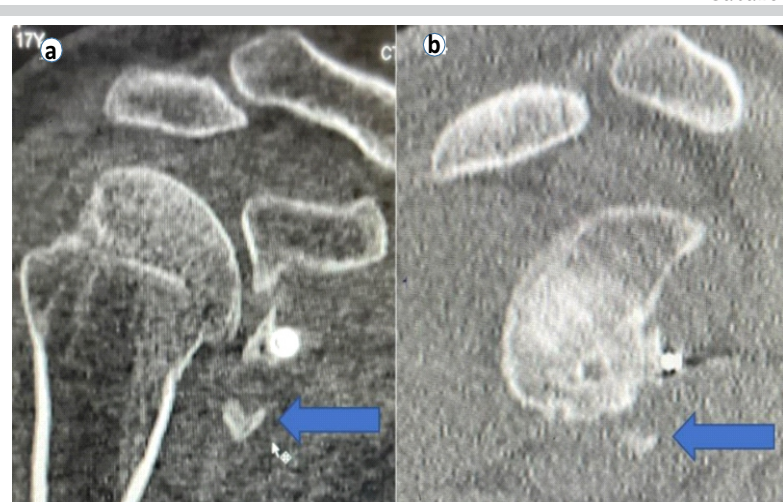
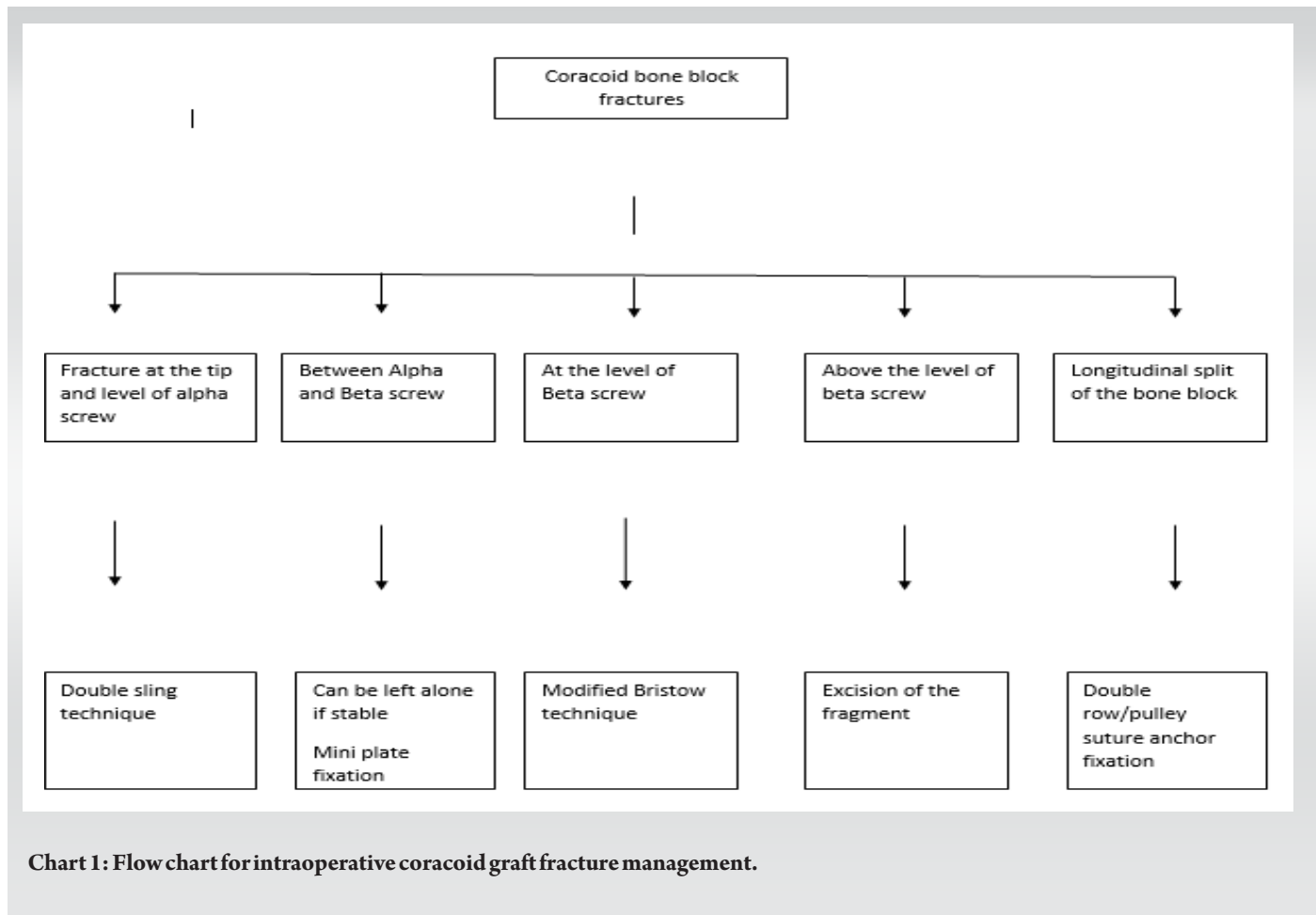


Figure 7: (a and b) Follow-up 12 months post-operative CT scans showing coracoid tip fragment which is close to the good bony integrated main bone block fragment with intact screws.





shows 3-month follow-up after the surgery with an almost full range of movements. Follow-up CT scan at 12 months after surgery showed good bony integration of the main coracoid graft and intact screw, with the fractured coracoid graft close to the main bone block. The proximity of the coracoid tip fragment implied the sling action of the conjoint tendon was maintained (Fig. 7a). The patient was allowed to return to sports at end of 6 months. The patient has continued to do well at 12-month post-operative with no instability (Fig. 7b).

Discussion

The arthroscopic Latarjet procedure is well described by Lafosse and has been practiced around the world by many shoulder surgeons. Arthroscopic Latarjet provides excellent visualisation of neurovascular structures and graft positioning, also other shoulder pathologies can be addressed simultaneously [5]. Complication rates following arthroscopic Latarjet by Atwal et al. were similar to open Latarjet case series by Shah et al. [2]. Meraner et al. in his study of a 10-year follow-up of the arthroscopic Latarjet procedure estimated the complication rates to 30% [6]. Pereira and Gutierrez in their study of complications of coracoid transfer procedures described a higher percentage of screw-related complications

and revision surgeries when compared to data reported in the literature [7]. They highlighted that the arthroscopic technique was found to have an overall lower rate of complications when compared to open procedures. The most commonly described complication is loss of external rotation found in 67% of the shoulders [7]. Athwal et al. described six cases of intraoperative graft fracture, they believed that this complication is preventable with good preparation of the graft under surface to match the glenoid surface. Four out of six cases healed without complication, while two cases needed revision with iliac crest bone block procedures.

We believe that the iatrogenic conjoint tendon avulsion fracture of the coracoid graft in this patient is caused by excessive tightening of the alpha screw near the physis close to the conjoint tendon origin. The apophyseal injuries of the base are more common in the age group of 15–16 years in a study by Ogawa et al. [8]. Ogawa's functional classification of coracoid fractures is fracture of coracoid proximal to coracoclavicular ligament and fracture of coracoid distal to the coracoclavicular ligament [9].

Management of these graft fractures depends on the location of the fracture, the size, stability, and bone quality of the bone block. Fractures at the tip and the level of the alpha screw can be

managed with the double sling technique as described in this case report. Fractures between alpha and beta screws can be managed depending on the stability of the bone block and can be left alone in case of adequate stability or managed with a mini buttress plate (Di Giacomo plate; Arthrex)-screws inserted through the plate to get adequate stability [10]. Fractures at the level of beta screws can be managed with a single screw similar to the modified Bristow technique [11]. Fractures above the level of the beta screw are rare and can be managed with the excision of the fragment [4]. Fractures of the longitudinal split of the coracoid bone block can be managed with double-row suture anchor fixation [12]. Fractures with poor bone quality and instability can be managed with the isolated conjoint tendon transfer or iliac crest bone grafting technique [13, 14].

In our study, we performed a novel double sling technique to address conjoint tendon avulsion fracture of the coracoid graft using the double sling technique as described, which is comparable to knotless bony bankart fixation. We were able to get a good bony integration of the bone block with maintained sling action of the conjoint tendon with our technique. The triple effect of the Latarjet surgery was important in maintaining the stability of the shoulder. Flow chart for Latarjet

surgery coracoid graft fracture management is shown in (Chart 1).

Conclusion

Latarjet procedure provides good results in patients with glenohumeral instability with glenoid bone loss. The arthroscopic Latarjet technique has a steep learning curve and has the advantage of minimally invasive and fast recovery. Complication rates are almost similar to open Latarjet. Graft fractures after Latarjet procedures have been described intraoperatively. Following graft fracture, the salvage procedure depends on fracture fragment size, location of fracture, and graft stability.

Clinical Message

This case report is to highlight the management of intraoperative coracoid graft management while performing arthroscopic Latarjet procedure. The sling effect of the conjoint tendon can be maintained with double sling fixation.

Declaration of patient consent: The authors certify that they have obtained all appropriate patient consent forms. In the form, the patient has given the consent for his/ her images and other clinical information to be reported in the journal. The patient understands that his/ her names and initials will not be published and due efforts will be made to conceal their identity, but anonymity cannot be guaranteed.

Conflict of interest: Nil **Source of support:** None

References

1. Dauzère F, Faraud A, Lebon J, Faruch M, Mansat P, Bonneville N. Is the latarjet procedure risky? Analysis of complications and learning curve. *Knee Surg Sports Traumatol Arthrosc* 2016;24:557-63.
2. Shah AA, Butler RB, Romanowski J, Goel D, Karadagli D, Warner JJ. Short-term complications of the latarjet procedure. *J Bone Joint Surg Am* 2012;94:495-501.
3. Young DC, Rockwood CA Jr. Complications of a failed Bristow procedure and their management. *J Bone Joint Surg Am* 1991;73:969-81.
4. Athwal GS, Meislin R, Getz C, Weinstein D, Favorito P. Short-term complications of the arthroscopic latarjet procedure: A North American experience. *Arthroscopy* 2016;32:1965-70.
5. Lafosse L, Boyle S. Arthroscopic latarjet procedure. *J Shoulder Elbow Surg* 2010;19:2-12.
6. Meraner D, Smolen D, Sternberg C, Thallinger C, Hahne J, Leuzinger J. 10 years of arthroscopic latarjet procedure: Outcome and complications. *Indian J Orthop* 2019;53:102-10.
7. Pereira AC, Gutierrez M. Complications of coracoid transfer procedures for the treatment of recurrent shoulder dislocation. *Porto Biomed J* 2017;2:161-6.
8. Ogawa K, Inokuchi W, Matsumura N. Physeal injuries of the coracoid process are closely associated with sports activities: A systematic review. *Orthop J Sports Med* 2020;8:2325967120967914.
9. Ogawa K, Yoshida A, Takahashi M, Ui M. Fractures of the coracoid process. *J Bone Joint Surg Br* 1997;79:17-9.
10. Di Giacomo G, Costantini A, de Gasperis N, De Vita A, Lin BK, Francone M, et al. Coracoid bone graft osteolysis after Latarjet procedure: A comparison study between two screws standard technique vs mini-plate fixation. *Int J Shoulder Surg* 2013;7:1-6.

11. Schroder DT, Provencher MT, Mologne TS, Muldoon MP, Cox JS. The modified bristow procedure for anterior shoulder instability: 26-year outcomes in naval academy midshipmen. *Am J Sports Med* 2006;34:778-86.
12. Kongmalai P, Levine WN. Double-row fixation of the transferred coracoid process: A rescue technique for intraoperative coracoid fracture during the Latarjet procedure. *J Shoulder Elbow Surg* 2019;28:e226-31.
13. Tennent D, Colaço HB, Arnander M, Pearse E.

Arthroscopic conjoint tendon transfer: A technique for revision anterior shoulder stabilization. *Arthrosc Tech* 2016;5:e201-5.

14. Malahias MA, Chytas D, Raoulis V, Chronopoulos E, Brilakis E, Antonogiannakis E. Iliac crest bone grafting for the management of anterior shoulder instability in patients with glenoid bone loss: A systematic review of contemporary literature. *Sports Med Open* 2020;6:12.

Conflict of Interest: Nil

Source of Support: Nil

Consent: The authors confirm that informed consent was obtained from the patient for publication of this case report

How to Cite this Article

Nair AV, Mohan PK, Jangale A, Krishna P, Goud N. Arthroscopic Salvage Procedure for Iatrogenic Conjoint Tendon Avulsion Fracture Following Arthroscopic Latarjet Procedure Using Double Sling Fixation Technique – A Case Report. *Journal of Orthopaedic Case Reports* 2023 September;13(9): 77-82.