

Case Report of Herpes Zoster Infection of the Cervical Dermatome – A Rare Cause of Acute Shoulder Pain

Amirzeb Aurangzeb¹, Elliot Yeung Chong¹, Paul Wen Loong Yuen¹, Don Thong Siang Koh²,
Chung Liang Kuo¹

Learning Point of the Article:

The goal of this paper is to illustrate an approach to shoulder pain and to remind clinicians of the rarer entities that may mimic that of rotator cuff pathology as well as to consider red flag differentials in the process of making an eventual diagnosis for the patient.

Abstract

Introduction: Acute shoulder pain is among the most common presenting complaints in the clinic. Clinicians may find it challenging with the myriad of potential etiologies to explain for the presenting complaint. We present a unique case, where a herpes zoster infection in the C6 dermatome mimicked the presentation of rotator cuff pathology and was admitted to the care of orthopedics. We have also included a detailed literature review on the topic in our study.

Case Report: The patient was a 38-year-old Chinese female who presented with acute atraumatic right-sided shoulder pain and weakness which was potentially confounded by an attempt of traditional Chinese medicine. Clinical examination revealed that the range of motion was globally reduced and painful in all directions with equivocal impingement testing. Examination of the skin revealed the presence of polymorphous eruption of erythematous papules and vesicles in the right shoulder and C6 region. In this paper, we discuss a possible algorithm to aid clinicians in an acute shoulder pain history with accompanying red flags to look out for. This is accompanied by a detailed literature review on the topic which demonstrates the rarity of this presentation which eventually confounded the initial management of the patient.

Conclusion: A thorough history and physical examination must remain the cornerstone of a clinician's diagnostic algorithm. Zoster neuropathy at the level of the cervical spine is a rare entity. This case report also emphasizes the need for cognizance of local traditional remedies practiced and their interactions with clinical diagnosis and treatment.

Keywords: Shoulder, zoster, cervical.

Introduction

Varicella otherwise commonly known as chickenpox disease is a contagious viral illnesses caused by the varicella-zoster virus. Primary varicella infections usually tend to present as a vesicular pruritic rash occurring over the trunk, head, and face. Herpes zoster is classically associated with a localized, painful, and blistering rash that follows a unilateral dermatomal distribution that does not cross the midline [1]. Herpes zoster is most

commonly in the thoracic region, followed by the lumbar, cervical, and then sacral region [2,3]. Symptoms tend to be more severe for adults than for children [4]. Herpes zoster disease, or shingles, occurs when the dormant varicella-zoster virus reactivates within the dorsal root ganglia or cranial nerve [5]. Herpes zoster disease is normally managed within a primary care setting, through patient education, contact precaution, and appropriate analgesia.

Author's Photo Gallery



Dr. Amirzeb Aurangzeb



Dr. Elliot Yeung Chong



Dr. Paul Wen Loong Yuen



Dr. Don Thong Siang Koh



Dr. Chung Liang Kuo

Access this article online

Website:
www.jocr.co.in

DOI:
<https://doi.org/10.13107/jocr.2024.v14.i08.4658>

¹Department of Orthopaedic Surgery, Changi General Hospital, Singapore, Singapore,

²Department of Orthopaedic Surgery, Singapore General Hospital, Singapore, Singapore.

Address of Correspondence:

Dr. Amirzeb Aurangzeb,
Department of Orthopaedic Surgery, Changi General Hospital, Singapore.
E-mail: amirzeb19@yahoo.com.sg

Submitted: 08/05/2024; Review: 24/06/2024; Accepted: July 2024; Published: August 2024

DOI: <https://doi.org/10.13107/jocr.2024.v14.i08.4658>

This is an open access journal, and articles are distributed under the terms of the Creative Commons Attribution-NonCommercial-ShareAlike 4.0 License <https://creativecommons.org/licenses/by-nc-sa/4.0/>, which allows others to remix, tweak, and build upon the work non-commercially, as long as appropriate credit is given and the new creations are licensed under the identical terms

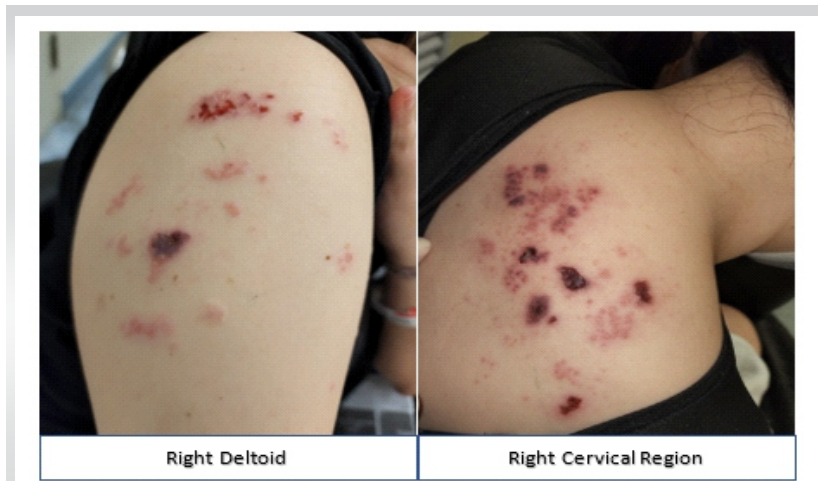


Figure 1: Clinical pictures of the patient on presentation, maculopapular rash over the right deltoid and cervical region.

However, when herpes zoster affects less common dermatomes, its manifestation may be atypical and pose a diagnostic conundrum. We present a rare case of a herpes zoster infection in the C6 dermatome closely mimicking that of rotator cuff pathology. The goal of the paper is to illustrate an approach to shoulder pain and to remind clinicians of the rarer entities that may mimic that of rotator cuff pathology as well as to consider red flag differentials in the process of making an eventual diagnosis for the patient.

Case Report

The patient was a 38-year-old Chinese female with a history uncomplicated childhood varicella disease. She presented to the emergency department with a 7-day history of atraumatic right-sided shoulder pain and weakness. Her symptoms developed acutely and she had significant rest pain and night

pain. Symptoms were significant enough to affect her quality of sleep and function including the donning and removing of clothes. The patient had no prior history of fever, myalgia, or malaise. The patient did not complain of stiffness or numbness in the affected upper limb. There was no previous surgery performed on the right shoulder and she did not suffer from any chronic metabolic diseases. Nil red flags were picked up during history taking as well (Fig. 1).

Significantly, the patient's husband attempted acupuncture and a traditional Chinese massage technique known as "gua sha" which involves rubbing down affected areas with sand or a mild exfoliating substance. These measures were attempted on the right shoulder without symptomatic relief. It was only after a week of severe discomfort that she presented to the emergency department seeking medical treatment.

Clinical examination revealed that her right shoulder range of motion was globally reduced and painful in all directions. There was no significant effusion. Impingement testing was not performed as the patient was in significant pain on movement of the shoulder despite analgesics. Rotator cuff strength testing revealed weakness in supraspinatus, infraspinatus, and subscapularis muscles. Closer inspection revealed a polymorphous eruption of erythematous papules and vesicles with some crusting over the C6 dermatome, extending to the right lateral arm and upper trapezius. This rash was not described to be itchy or painful and was claimed to have been brought about by acupuncture and massage performed by the patient's husband. It was unclear if the rash originally started before or after the acupuncture efforts from history taking. The

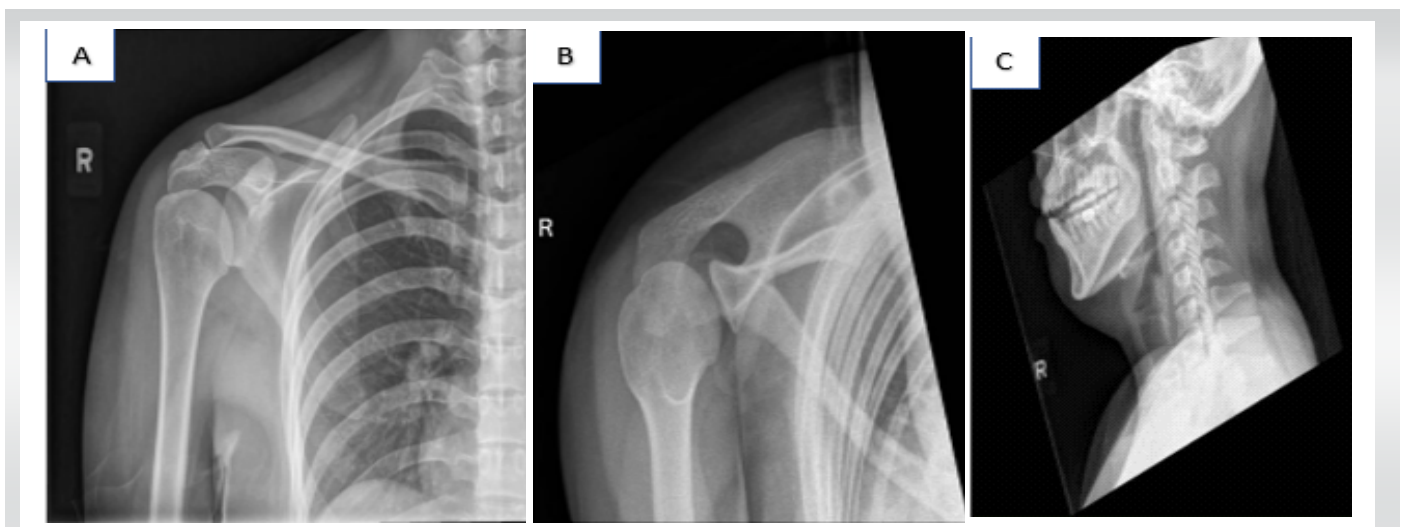


Figure 2: (A and B) The anterior-posterior (AP) and axillary views of the right shoulder with the humeral head are enlocated, nil fractures seen. (C) Lateral cervical spine radiograph with some mild loss of cervical lordosis and spondylotic changes at C5/C6.

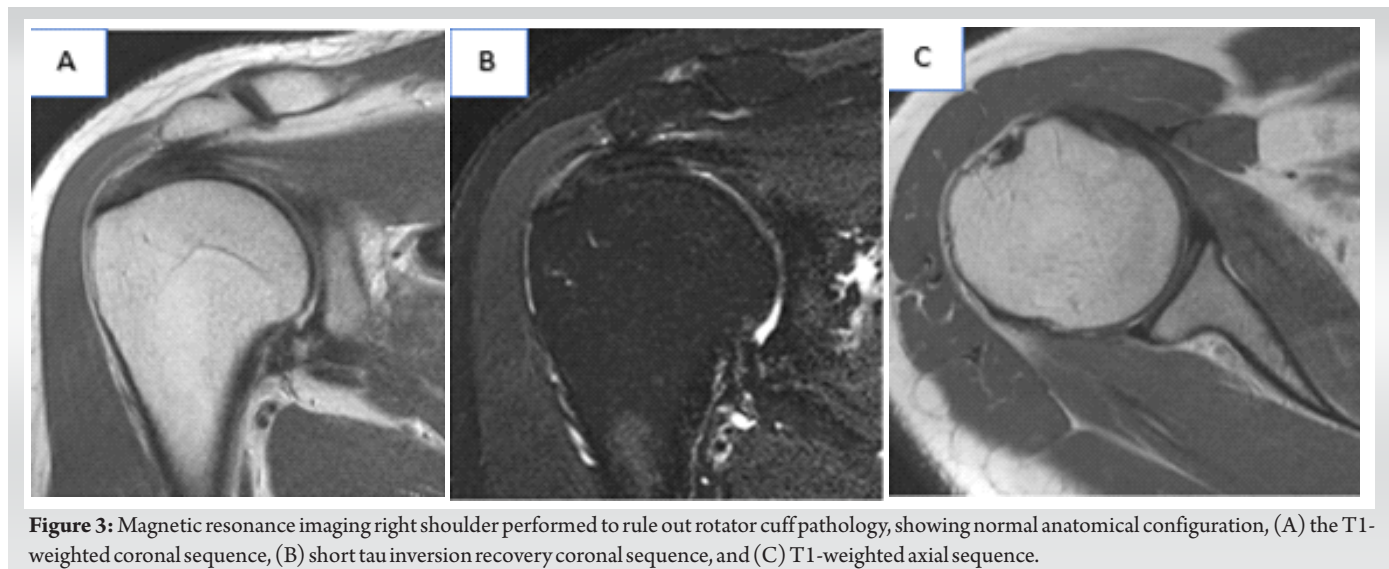


Figure 3: Magnetic resonance imaging right shoulder performed to rule out rotator cuff pathology, showing normal anatomical configuration, (A) the T1-weighted coronal sequence, (B) short tau inversion recovery coronal sequence, and (C) T1-weighted axial sequence.

initial impression was that of right shoulder rotator cuff impingement syndrome by the Emergency Department physician, with the skin lesions attributed to the excoriating massage by both the patient and the physician. The patient was promptly admitted under the care of orthopedic department.

Biochemical evaluation was unremarkable with flat inflammatory markers of total white cell count of $5.7 \times 10^3/\text{UL}$ and C-reactive protein of 2.3 mg/L. Radiographs of the right shoulder and cervical spine were performed, showing no acute fracture or bony injury and preserved subacromial space with congruence of the right glenohumeral and acromioclavicular joints and straightening of the normal cervical lordosis with mild spondylotic changes at the C5/C6 level (Fig. 2). In view of patient's symptom severity and persistent reduction in right shoulder movement, a magnetic resonance imaging (MRI) of the shoulder was performed (Fig. 3). MRI of the right shoulder was unremarkable and did not demonstrate any shoulder synovitis, effusion, rotator cuff tendonitis, tears, or any significant bony pathology. Dermatologist was referred and polymerase chain reaction swab was performed on the vesicular rash which turned out positive for varicella zoster viral DNA.

On discovering these findings, patient's analgesia was titrated and optimized, a 7-day course of oral acyclovir was prescribed under the advice of a dermatologist, and she was discharged to primary care for the continued care of the zoster.

Discussion

This case is particularly unique as classic cutaneous herpes zoster infection does not classically affect the cervical region. This confounded the management plans for the patient as it was thought to be that of rotator cuff pathology in nature and thus admitted to the care of the orthopedic department. Varicella-

zoster viral infection usually results in symptoms of a vesicular itchy and painful rash, malaise as well as fever [6]. However, symptoms may be worse in adults compared to children. The mechanism of how zoster results in paresis is unclear but assumed to be due to the spread of the virus along the nerves with underlying inflammation [7,8]. This may thus explain the weakness that the patient reported on examination. Zoster is usually managed as self-limiting condition with analgesia but anti-virals such as acyclovir can also be used as adjuncts in management [9].

The main pearls of diagnosis come from good clinical history and physical examination. Clinical history should include asking the patient the site, onset, character of pain, radiation of pain, alleviating factors, time of symptoms, exacerbating factors, and pain score. Important considerations to take note would also be the hand dominance, occupation, presence of any trauma or precipitating injury, previous shoulder or spine surgeries, as well as the presence of any other pain or stiffness in other joints to exclude polyarticular disease [6]. In the presence of trauma or injury, additional details on the mechanism and force of injury are crucial as well. Red flags include symptoms such as fever, weight loss, night sweats, respiratory symptoms, and trauma [10].

The patient needs to be adequately exposed for a proper and complete physical examination. Examination of the skin includes looking for rash, masses or swellings, and localized erythema [10]. Assessment includes patient's active and passive range of movement. Special attention should be given to the muscle strength of the rotator cuffs during each movement. The rotator cuffs should also be evaluated through a series of special tests that evaluate the movement of the glenohumeral joint in the anterior, posterior, and lateral directions. Special attention should be paid to the muscle strength of the rotator cuffs during

each movement. Belly lift-off test is commonly done to evaluate the strength of the subscapularis, while Jobe’s and external rotation lag sign evaluates the supraspinatus and infraspinatus. Hornblower’s sign is used to determine teres minor and infraspinatus insufficiency. These tests are further supported by Hawkin’s and Neer’s tests for impingement testing as well as anterior apprehension test for shoulder instability. Patients with diffuse tenderness or global reduction in range of movement in the shoulder tend to be associated with capsulitis or frozen shoulder. Symptoms associated with exquisite tenderness and fever raise the suspicion of septic arthritis. When the pain or stiffness is more gradual in onset, we consider the possibility of glenohumeral osteoarthritis as a differential. Pain at rest or associated weakness in the rotator cuffs increases the likelihood of rotator cuff tears or tendinopathy. When patients report associated symptoms of numbness, paraesthesia, or shooting electric pain down the upper limbs, clinicians should also consider a cervical spine origin.

Rotator cuff impingement syndrome is a clinical diagnosis. In

this case, since the biochemical markers, X-rays and MRI imaging were not suggestive of an active subacromial or glenohumeral pathology to explain the patient’s symptoms; her symptoms were attributed to the ongoing herpes zoster infection.

We performed a detailed literature search on the PubMed database to review other articles of a similar nature. The search interval was set up until 1st January 2024. The search was done using the keywords in English: “herpes zoster shoulder” and “cervical zoster shoulder.” Shortlisted papers were reviewed for their relevance to the subject, namely, on the presence of cervical zoster symptoms with correlation to shoulder pain in the patient. Any studies dated before January 2000 were excluded from the study.

A total of 69 articles were identified for initial screening. After duplicate records and records not available in English were removed, 49 records underwent a title screening process. Thirty-four records were excluded based on a title screening process as they were not relevant to the topic discussed. The

S/N	Title	Main author	Year	Country	Number of cases	Study design	Summary	Learning points
1	An unusual case of shoulder pain; herpes induced brachial plexopathy.	Melikoglu [11]	2013	Turkey	1	Case Report	66-year-old man with skin rash over the left shoulder, with vesicular eruptions. Involved weakness in the left upper limb. Eventually diagnosed with left brachial plexus neuritis after an electromyography scan.	Zoster closely mimics several conditions including rotator cuff tears, acute calcifying tendinitis, impingement syndromes, cervical radiculopathy, and tumors. Electromyography scans are useful in helping to make the diagnosis.
2	Transient motor paresis caused by herpes zoster.	Park SE [12]	2016	South Korea	2	Case Series	73-year-old man with right shoulder pain, weakness and skin rash diagnosed with herpes zoster and treated conservatively. Atrophy of supraspinatus and infraspinatus muscles noted with large full-thickness rotator cuff tear seen on MRI. Arthroscopic repair eventually performed as symptoms not improving. 76-year-old female with vesicular rash over right shoulder, affecting range of movement of shoulder. MRI also showing small full-thickness rotator cuff tear and type 3 acromion spur. Treated with physiotherapy.	Describes the importance of full history-taking and clinical examination of the shoulder in both cases. Both cases were initially managed as herpes zoster alone of the cervical region but eventually needed further investigation with radiology or nerve studies to unveil other rotator cuff injuries. The presence of a rotator cuff tear further complicated the management of the first case, which eventually required surgery.
3	Segmental Zoster Paresis of unilateral upper extremity: A case report and literature review.	Chen GB [13]	2020	Taiwan	1	Case report	72-year-old man with left shoulder pain and weakness with previous history of vesicular rash 10 days prior. Left biceps and brachioradialis reflexes hypoaactive with weakness noted in left deltoid, biceps, supraspinatus, subscapularis, and infraspinatus muscles. Needle electromyography showed denervation activity, diagnosed as segmental zoster paresis.	The time interval between the occurrence of a skin rash in zoster and the development of muscle weakness varies from case to case. The use of an antiviral treatment following herpes zoster infection may reduce the chances of segmental zoster paresis. Zoster paresis secondary to a previous/ongoing herpes zoster should be considered a differential diagnosis of any acute paresis in the upper limb.
4	Axillary mononeuropathy after herpes zoster infection mimicking subacromial impingement syndrome.	Aktas [14]	2008	Turkey	1	Case Report	75-year-old female with right shoulder pain of 3 months duration with positive MRI finding of subacromial impingement of the supraspinatus tendon. Limited range of movement in active forward elevation and abduction with severe shoulder abductor and external rotator muscle weakness. Subacromial lidocaine test was negative with absence of complete rotator tendon rupture on MRI to explain the weakness noted. History then revealed that patient had a painful dermatomal vesicular rash in her shoulder 3 months prior.	Reinforces the need for a good history taking in an approach to a patient with shoulder pain. The dermatomal rash occurred 3 months prior to presentation in clinic but matched the timing of onset of symptoms.
5	Segmental Zoster paresis of the upper extremity: A case report.	Yoleri [8]	2005	Turkey	1	Case Report	Elderly patient with right shoulder pain and weakness with history of vesicular rash 6 weeks prior, diagnosed to be herpes zoster without administration of antivirals. Range of movement in shoulder limited throughout with sulcus sign positive in right shoulder. Weakness noted in right deltoid, biceps and infraspinatus and nerve conduction studies showed upper truncus brachial plexopathy.	Provides an insight on the wide spectrum of presentation that zoster may present with. Highlights that likelihood of zoster paresis increases with the lack of antiviral agents given during previous herpes zoster infection.
6	Zoster paresis of shoulder: Case report and literature.	Yaszay [15]	2000	United States	1	Case Report	73-year-old man with left shoulder pain and weakness who was treated as per rotator cuff inflammation and given a corticosteroid injection with no relief. Developed a rash over the left biceps and brachioradialis 2 days later, diagnosed as herpes zoster. Limited active range of movement with negative provocative testing and reduced biceps and brachioradialis reflexes. Cervical causes were also considered, with an MRI showing C5/C6 mild disc bulge without spinal cord or nerve compression. Needle electromyography showed acute axonal nerve dysfunction in the C5/C6 spinal motor distribution.	Allows an appreciation of the different possible differentials for the cause of shoulder pain. Negative provocative testing and lack of relief from the steroid injection reduces the possibility of rotator cuff tear. The presence of weakness and muscle atrophy in the left biceps, deltoid, and infraspinatus was thus attributed to a nerve disorder rather than a case of disc atrophy if it was rotator cuff disorder. Highlights the importance of also considering cervical causes of the shoulder pain.

MRI: Magnetic resonance imaging

Table 1: A summary of relevant literature.



remainder of the 15 records underwent an abstract screening process and a further nine records were removed due to irrelevance to the topic. The remainder of the six studies is summarized in Table 1.

Table 1 demonstrates the current literature around the topic discussed. We have included a summary of the article as well as pertinent learning outcomes from each article in the table. As seen from the table, most of the existing relevant literature to the report consists of isolated case reports or short case series with a considerable lack of empirical studies or systematic reviews. In the absence of empirical data, case reports or series are the main resource for clinicians with their ability to provide an accurate description of patient experience, clinical manifestations, diagnostic challenges faced, and treatment outcomes with important pearls of knowledge for future decision-making. Within the context of the limited literature that surrounds the topic as such, our case report adds to the repertoire of knowledge and brings about valuable insights into an effective clinical examination of the shoulder.

Declaration of patient consent: The authors certify that they have obtained all appropriate patient consent forms. In the form, the patient has given the consent for his/ her images and other clinical information to be reported in the journal. The patient understands that his/ her names and initials will not be published and due efforts will be made to conceal their identity, but anonymity cannot be guaranteed.

Conflict of interest: Nil **Source of support:** None

Conclusion

A thorough history and physical examination must remain the cornerstone of a clinician's diagnostic algorithm. Zoster neuropathy at the level of the cervical spine is a rare entity whose manifestation can outfox even the most experienced clinicians. Shoulder pain disproportionate to the history with cutaneous signs should always prompt the consideration of a herpes zoster infection. This case report also emphasizes the need for cognizance of local traditional remedies practiced and their interactions with clinical diagnosis and treatment.

Clinical Message

This case study clearly underlines the need for a proper diagnostic approach to a patient presenting with shoulder pain. The need for accurate triage, history-taking, and physical examination could have reduced the chances of an initial misdiagnosis and management of the patient under a different discipline.

References

1. Sampathkumar P, Drage LA, Martin DP. Herpes zoster (shingles) and postherpetic neuralgia. *Mayo Clin Proc* 2009;84:274-80.
2. Dayan RR, Peleg R. Herpes zoster-typical and atypical presentations. *Postgrad Med* 2017;129:567-71.
3. Koshy E, Mengting L, Kumar H, Jianbo W. Epidemiology, treatment and prevention of herpes zoster: A comprehensive review. *Indian J Dermatol Venereol Leprol* 2018;84:251-62.
4. Ayoade F, Kumar S. *Varicella-Zoster*. Treasure Island, FL: StatPearls Publishing; 2022.
5. Nair PA, Patel BC. *Herpes Zoster*. Treasure Island, FL: StatPearls Publishing; 2022.
6. Yang S, Kim TU, Kim DH, Chang MC. Understanding the physical examination of the shoulder: A narrative review. *Ann Palliat Med* 2021;10:2293-303.
7. Liu Y, Wu BY, Ma ZS, Xu JJ, Yang B, Li H, et al. A retrospective case series of segmental zoster paresis of limbs: Clinical, electrophysiological and imaging characteristics. *BMC Neurol* 2018;18:121.
8. Yoleri O, Olmez N, Oztura I, Sengül I, Günaydin R, Memiş A. Segmental zoster paresis of the upper extremity: A case report. *Arch Phys Med Rehabil* 2005;86:1492-4.
9. Opstelten W, Eekhof J, Neven AK, Verheij T. Treatment of herpes zoster. *Can Fam Physician* 2008;54:373-7.
10. Artus M, Holt TA, Rees J. The painful shoulder: An update on assessment, treatment, and referral. *Br J Gen Pract* 2014;64:e593-5.
11. Melikoglu M, Melikoglu MA. An unusual cause of shoulder pain; Herpes zoster induced brachial plexopathy, a case report and review of the literature. *J Back Musculoskeletal Rehabil* 2013;26:243-5.
12. Park S, Ganji P, Ji J, Park SH. Transient motor paresis caused by herpes zoster. *J Shoulder Elbow Surg* 2016;25:e309-12.
13. Chen G, Tuan S, Liou I, Huang H, Hu Y, Wu S. Segmental zoster paresis of unilateral upper extremity. A case report and literature review. *Medicine (Baltimore)* 2020;99:e20466.
14. Aktas I, Akgun K, Gunduz OH. Axillary mononeuropathy after herpes zoster infection mimicking subacromial

impingement syndrome. *Am J Physical Med Rehabil* 2008;87:859-61.

15. Yaszay B, Jablecki CK, Safran MR. Zoster paresis of the

shoulder. Case report and review of the literature. *Clin Orthop Relat Res* 2000;377:112-8.

Conflict of Interest: Nil

Source of Support: Nil

Consent: The authors confirm that informed consent was obtained from the patient for publication of this case report

How to Cite this Article

Aurangzeb A, Chong EY, Yuen PWL, Koh DTS, Kuo CL. Case Report of Herpes Zoster Infection of the Cervical Dermatome – A Rare Cause of Acute Shoulder Pain. *Journal of Orthopaedic Case Reports* 2024 August;14(8): 89-94.