

Spontaneous Osteonecrosis of Knee: A Complication of COVID-19 or An Iatrogenic Side Effect of Steroid Use?

Sohail Ahmad¹, Faisal Harun¹, Adnan Anwer¹, Kaustubh Hari¹, Tyson Rana¹, Areeb Asif²

Learning Point of the Article:

Idiopathic pain in joints of the hip and knee in patients with a history of COVID-19 infection, with or without steroid use, should raise suspicion of spontaneous osteonecrosis of the bone, and it can be managed satisfactorily using conservative methods.

Abstract

Introduction: Spontaneous osteonecrosis of bones is a relatively well-studied entity, which has been linked to both COVID-19 as well as the “wonder drug” used to treat it: steroids. The disease is said to occur within 2 months of COVID-19 infection and the clinical picture is usually of a painful joint with a history of COVID-19 which may be associated with management using steroids. The report highlights the importance of clinical discretion while administering steroids as well as the increasing number of such cases of osteonecrosis of bones post the COVID-19 pandemic.

Case Report: In this case report, we present the case of a young female who presented to us with complaints of spontaneous onset pain in her left knee, which the patient could trace back to when she got infected with the COVID-19 virus. Radiological investigations confirmed the clinical suspicion of osteonecrosis of knee joints secondary to steroid use for the management of COVID-19. The patient was managed conservatively with satisfactory results on follow-up.

Conclusion: Painful knee joints are a common complaint in outpatient orthopedic clinics, but the presence of idiopathic knee pain, especially in young patients, with a prior history of COVID-19 should raise the suspicion of spontaneous osteonecrosis of the knee. The results of the condition are excellent using conservative management.

Keywords: Spontaneous osteonecrosis of knee, COVID-19, steroids, knee pain.

Introduction

The COVID-19 pandemic was caused by Novel Coronavirus, the origins of which could be traced back to Wuhan in China. The disease was declared a pandemic by the World Health Organization (WHO) in March 2020 [1]. While the disease manifested in most cases as a flu-like illness with symptoms consisting of fever, cough, and shortness of breath, the disease is well documented to affect nearly every organ system in the human body. This is attributed to its ability to cause endothelial damage in blood vessels, which leads to a hypercoagulable state

in the body [2]. This, in addition to the dysregulated immune response and the hyperinflammatory state, may affect nearly every organ system in the body as Virchow’s triad of stasis, hypercoagulability, and endothelial injury is completed. The resulting micro as well as macro thrombosis may cause pulmonary embolism when in the lungs, and also has the potential to cause multiple organ dysfunction syndrome, as well as death [3].

As the world still recovers from COVID-19, the long-term complications of the disease are still largely unknown, and the

Author's Photo Gallery



Dr. Sohail Ahmad



Dr. Faisal Harun



Dr. Adnan Anwer



Dr. Kaustubh Hari



Dr. Tyson Rana



Dr. Areeb Asif

Access this article online

Website:
www.jocr.co.in

DOI:
<https://doi.org/10.13107/jocr.2024.v14.i08.4664>

¹Department of Orthopaedic Surgery, Jawaharlal Nehru Medical College, Aligarh Muslim University, Aligarh, Uttar Pradesh, India,

²Final year MBBS Student, Jawaharlal Nehru Medical College, Aligarh Muslim University, Aligarh, Uttar Pradesh, India.

Address of Correspondence:

Dr. Adnan Anwer,
Department of Orthopaedic Surgery, Jawaharlal Nehru Medical College, Aligarh Muslim University, Aligarh, Uttar Pradesh, India.
E-mail: dr.adnan.amu@gmail.com

Submitted: 21/05/2024; Review: 18/06/2024; Accepted: July 2024; Published: August 2024

DOI: <https://doi.org/10.13107/jocr.2024.v14.i08.4664>

This is an open access journal, and articles are distributed under the terms of the Creative Commons Attribution-NonCommercial-ShareAlike 4.0 License <https://creativecommons.org/licenses/by-nc-sa/4.0/>, which allows others to remix, tweak, and build upon the work non-commercially, as long as appropriate credit is given and the new creations are licensed under the identical terms

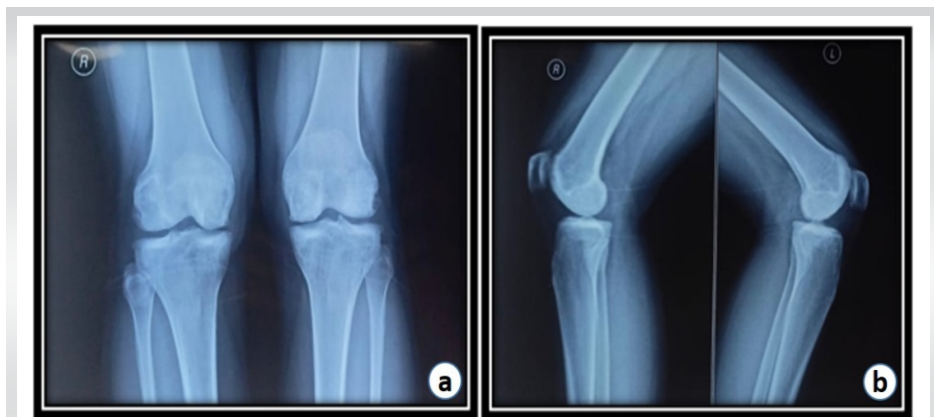


Figure 1: Radiographic image of the knee joint in anteroposterior (a) and lateral view (b), showing lucent areas in the distal femur, and proximal tibia and fibula

complaints of pain in both her knees, with the left knee being more painful than the right. The pain was insidious in onset, dull aching in nature, mild-to-moderate in intensity, with no aggravating or relieving factors, not radiating to any other site and not relieved by rest. There was no history of trauma as well. There was no family history of hypercoagulability or recent travel. There is no history of any prior surgery to any of the knees and similar pain in either of the knees. Furthermore, no history of birth control measures was present.

Clinical examination revealed a complete range of motion in both knees. Both knees were stable and there was no local rise in temperature or any tenderness. X-rays (Fig. 1) and magnetic resonance imaging (MRI) were advised as X-rays revealed lucent areas in the distal femur and proximal tibia and fibula. Conservative management was started.

methods used to treat it remain a subject of study as well. While most people recover completely from the disease, some people may have symptoms that linger for weeks or even months after they recover from the acute infection. There is no universally agreed-upon definition of the condition, which is labeled post-COVID syndrome by the WHO and is also referred to as chronic COVID syndrome, long COVID, long-term COVID-19, post-acute COVID-19, and post-COVID syndrome among many other names [4]. The symptoms may be respiratory, such as shortness of breath and cough, gastrointestinal such as diarrhea, dermatologic such as rashes, neurogenic such as loss of taste and smell, and sleep disturbances, as well as psychiatric such as depression and anxiety. The most common musculoskeletal symptoms of the condition are fatigue, back pain, arthralgia, myalgia, and neck pain [5].

MRI (Fig. 2) of the right knee was done using the spin echo sequence technique, which showed multiple confluent altered signal intensity lesions involving the subchondral and metaphyseal region of medial and lateral condyles of the tibia, head of fibula, and femur, appearing hypointense on T1- as well as T2-weighted imaging with a serpiginous peripheral hyperintense rim on PD sequence, suggestive of bone infarcts with areas of subchondral bone defects leading to flattening of lateral femoral condyle. There was thinning of articular cartilage present at femoral condyles. Screening the right knee showed similar multiple subchondral bony infarcts involving the femoral and tibial condyle and head of the fibula.

Osteonecrosis of bones is a multifactorial condition most commonly affecting the hip and knee joints. Spontaneous osteonecrosis of the knee (SPONK) is the most common form of osteonecrosis of the knee joint, and the underlying pathology is believed to be vascular in origin. The alteration in blood flow may be caused by drugs such as steroids, renal disease, and hematological disorders and may also be post-arthroscopic [6]. Thus, COVID-19 itself being a hypercoagulable state as well as a known factor for causing bone resorption through angiotensin-converting enzyme-2 (ACE-2) receptors, the use of steroids in its treatment adds another risk factor for SPONK [7].

The patient had been diagnosed with COVID-19 2 years before evaluation, around 6 months before the symptoms of knee pain first began to appear. The patient had flu-like symptoms 4 days before diagnosis. Still, the disease did not resolve spontaneously as in most cases, and the patient required hospitalization and admission to the intensive care unit (ICU), where intravenous corticosteroids were administered for a period of 2 weeks. The patient was admitted to ICU as she did not maintain saturation on room air but no other complications such as deep vein thrombosis were there. The patient was discharged under satisfactory clinical condition after recovery.

Investigating SPONK as a potential musculoskeletal complication of post-COVID syndrome, this report delves into the possible roles of the virus and corticosteroids, individually or combined, in its development. It proposes including SPONK in the differential diagnosis for knee pain in recovered COVID-19 patients and briefly touches on management strategies.

The patient was prescribed oral calcium supplements, Vitamin D capsules, and non-steroidal anti-inflammatory drugs. Along with these medications, physiotherapy of both knees was initiated. The patient showed significant relief in pain after 1 month and a near-complete resolution of symptoms at 2 months.

Case Report

A 22-year-old female, otherwise healthy, presented with

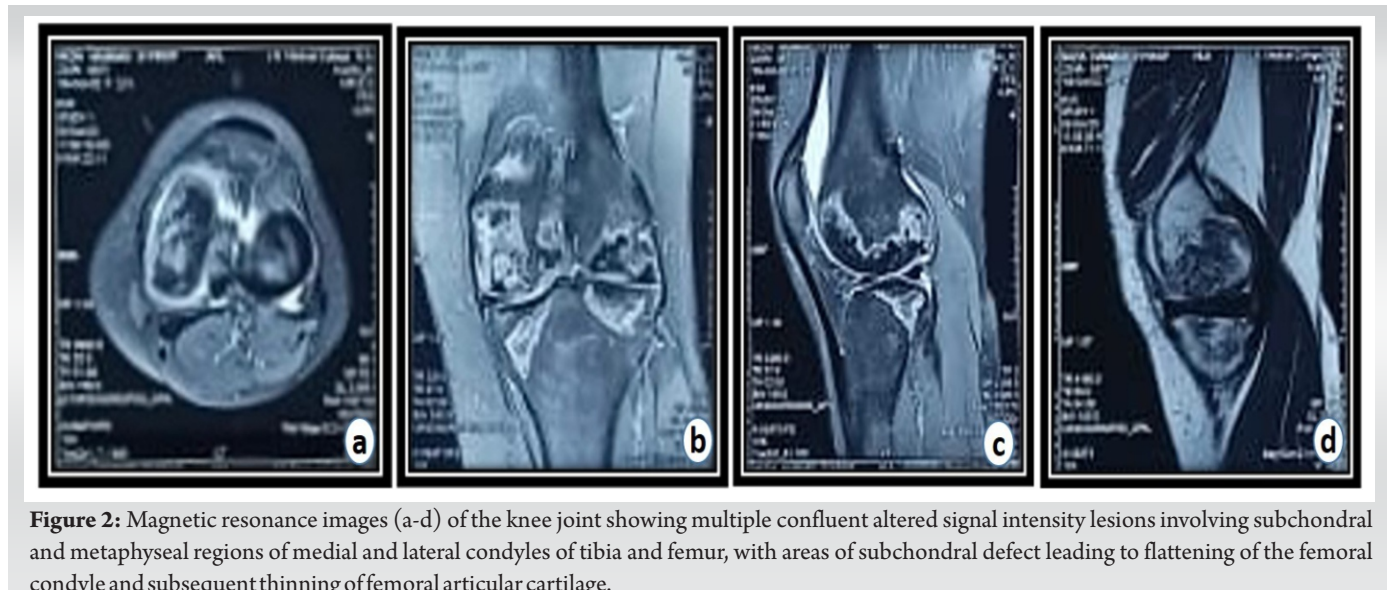


Figure 2: Magnetic resonance images (a-d) of the knee joint showing multiple confluent altered signal intensity lesions involving subchondral and metaphyseal regions of medial and lateral condyles of tibia and femur, with areas of subchondral defect leading to flattening of the femoral condyle and subsequent thinning of femoral articular cartilage.

Discussion

The long-term effects of COVID-19 have just begun to be documented and studied. While the disease had a predilection for the elderly, the long-term effects of post-COVID syndrome affect both the young and elderly [4]. Most of these changes can be attributed to the ability of the virus to cause endothelial damage via ACE-2 receptors, and thus, the disease is able to have a lasting impact on virtually every organ system [3, 7]. As the disease had over 771 million documented cases of COVID as of November 8, 2023, the number of people expected to have post-COVID syndrome is expected to be quite significant [1].

A study by Karaarslan et al. noted the most common long-term symptoms in COVID-19 patients after 1 month to be respiratory symptoms such as shortness of breath (26.3% of patients), loss of taste (15.0%), cough (14.0%), loss of smell (12.3%), loss of appetite (10.3%), headache (8.7%), sore throat (3.0%), diarrhea (1.30%), dizziness (1.3%), and fever (0.3%). If only musculoskeletal symptoms are taken into account, 92.30% of the patients had reported any musculoskeletal symptom at hospitalization, 72.7% at 2 weeks, and 56.3% at one month. The single-center cohort study, which involved prospective follow-up using phone interviews, found the most common musculoskeletal symptoms to be myalgia (64.0% at the end of 2 weeks and 44.3% at 1 month), myalgia (36.7% at 2 weeks and 21.0% at 1 month), arthralgia (35.0% at 2 weeks and 22.0% at 1 month), back pain (32.3% at 2 weeks and 22.7% at 1 month), and neck pain (15.7 at 2 weeks and 10.3% at 1 month) [5].

Corticosteroids proved to be a life-saving drug during the COVID-19 pandemic and reduced the inflammatory response responsible for complications such as acute respiratory distress syndrome, disseminated intravascular coagulation, and

multiple organ dysfunction syndromes. Their effectiveness in treating COVID-19 patients led to their widespread use as well as rampant misuse, as physicians struggled to find a cure for the condition. While steroids have been long known to be a cause of osteonecrosis, there is no consensus regarding the cumulative dose of steroids as well as the duration required to cause the same [7]. Apart from corticosteroids, antivirals tried in the treatment of COVID-19 infections, such as lopinavir and ropinavir have also been implicated in causing osteonecrosis of bones, however, their use in the pandemic was quite limited [8].

The incidence of osteonecrosis after corticosteroid therapy in COVID-19 is on the rise, with the condition being referred to as a “syndemic” [9]. A study conducted by Veizi et al. found that 5% of patients who had received various doses of corticosteroids may develop osteonecrosis. However, none of the many studies conducted on the topic have found a relation between the cumulative dose of corticosteroids and the incidence of osteonecrosis. This is further complicated by the fact that both steroids and the COVID-19 virus have the ability to lead to conditions that may predispose to the development of osteonecrosis [10].

It was noted, however, that the dose of steroids required to cause osteonecrosis in COVID-19 patients was less than the cumulative dose when compared to osteonecrosis caused by steroids alone. A study conducted by Dhanasekararaja et al. on 22 patients who developed osteonecrosis of the femoral head after being administered corticosteroids for the treatment of COVID-19 found the average onset of symptoms after infection to be 7.5 months, the average cumulative dose of steroid to be 811 mg, and the average duration of steroid tale to be 2.8 weeks. They concluded that the low cumulative dosage of

steroids makes COVID-19 vasculitis a possible factor for the development of osteonecrosis of the femoral head [11]. Malinowski et al. have also reported SPONK in two patients with COVID-19 which neither required hospitalization nor had any history of corticosteroid administration [12].

The case reported as well as the literature available on the topic highlights the role of COVID-19 infection in causing osteonecrosis, synergistically with steroids if not independently. Thus, practitioners should be cautious when coming across a case of joint pain and enquire about the history of COVID-19 infection, its duration, and treatment modalities used. Since most of the patients demonstrated satisfactory results with conservative treatment, clinical suspicion remains the most important factor in the management of the condition. The judicious use of corticosteroids in the treatment of COVID-19 as well as other diseases needs to be emphasized as well, to prevent osteonecrosis and other steroid-related complications in the long term.

Conclusion

SPONK can be considered to be a component of the post-COVID syndrome, according to our case part as well as the pre-existing literature. Practitioners need to be judicious when prescribing steroids for the treatment of COVID-19. A reasonable amount of clinical suspicion should also be employed when coming across a case of knee pain in a patient with a history of COVID-19, with or without a history of hospitalization or steroid use. Most patients can be managed successfully using conservative treatments and aggressive surgical modalities are rarely warranted.

Clinical Message

This article highlights the increasing number of cases of osteonecrosis of bones post-COVID-19 pandemic. A proper history and sufficient clinical suspicion may help in making the diagnosis and the management of the condition.

Declaration of patient consent: The authors certify that they have obtained all appropriate patient consent forms. In the form, the patient has given the consent for his/ her images and other clinical information to be reported in the journal. The patient understands that his/ her names and initials will not be published and due efforts will be made to conceal their identity, but anonymity cannot be guaranteed.

Conflict of interest: Nil **Source of support:** None

References

1. Cucinotta D, Vanelli M. WHO Declares COVID-19 a Pandemic. *Acta Biomed.* 2020 Mar 19;91(1):157-160. doi: 10.23750/abm.v91i1.9397. PMID: 32191675; PMCID: PMC7569573.
2. Lippi G, Sanchis-Gomar F, Favaloro EJ, Lavie CJ, Henry BM. Coronavirus disease 2019-associated coagulopathy. *Mayo Clin Proc* 2021;96:203-17.
3. Datta PK, Liu F, Fischer T, Rappaport J, Qin X. SARS-CoV-2 pandemic and research gaps: Understanding SARS-CoV-2 interaction with the ACE2 receptor and implications for therapy. *Theranostics* 2020;10:7448-64.
4. Lechner-Scott J, Levy M, Hawkes C, Yeh A, Giovannoni G. Long COVID or post COVID-19 syndrome. *Mult Scler Relat Disord* 2021;55:103268.
5. Karaarslan F, Demircioğlu Güneri F, Kardeş S. Postdischarge rheumatic and musculoskeletal symptoms following hospitalization for COVID-19: Prospective follow-up by phone interviews. *Rheumatol Int* 2021;41:1263-71.
6. Sibilska A, Góralczyk A, Hermanowicz K, Malinowski K. Spontaneous osteonecrosis of the knee: What do we know so far? A literature review. *Int Orthop* 2020;44:1063-9.
7. Guo KJ, Zhao FC, Guo Y, Li FL, Zhu L, Zheng W. The influence of age, gender and treatment with steroids on the incidence of osteonecrosis of the femoral head during the management of severe acute respiratory syndrome: A retrospective study. *Bone Joint J* 2014;96-B:259-62.
8. Patel MS, Gutman MJ, Abboud JA. Orthopaedic considerations following COVID-19: Lessons from the 2003 sars outbreak. *JBJS Rev* 2020;8:e2000052.
9. Baimukhamedov C, Botabekova A, Lessova Z, Abshenov B, Kurmanali N. Osteonecrosis amid the COVID-19 pandemic. *Rheumatol Int* 2023;43:1377-78.
10. Veizi E, Erdoğan Y, Sezgin BS, Karaman Y, Kılıçarslan K, Fırat A. The painful joint after COVID-19 treatment: A study on joint osteonecrosis following COVID-19-related corticosteroid use. *Jt Dis Relat Surg* 2023;34:75-83.
11. Dhanasekararaja P, Soundararajan D, Kumar KS, Pushpa BT, Rajkumar N, Rajasekaran S. Aggressive presentation and rapid



progression of osteonecrosis of the femoral head after COVID-19. *Indian J Orthop* 2022;56:1259-67.

12. Malinowski K, Skowronek P, Hirschmann M, Kim DW, Henry BM, Ebisz M, et al. Transient spontaneous

osteonecrosis of the knee (SONK) shortly after SARS-CoV-2 infection: A report of 2 cases. *Adv Clin Exp Med* 2022;31:1035-41.

Conflict of Interest: Nil

Source of Support: Nil

Consent: The authors confirm that informed consent was obtained from the patient for publication of this case report

How to Cite this Article

Ahmad S, Harun F, Anwer A, Hari K, Rana T, Asif A. Spontaneous Osteonecrosis of Knee: A Complication of COVID-19 or An Iatrogenic Side Effect of Steroid Use? *Journal of Orthopaedic Case Reports* 2024 August;14(8): 105-109.

