

# Spontaneous Bilateral Patellar Tendon Rupture in Patient with Ehlers–Danlos Syndrome: A Case Report

Helena Franco<sup>1</sup>, David Fraser<sup>1</sup>

## Learning Point of the Article:

This case report describes a 45-year-old male with Ehlers–Danlos syndrome who sustained bilateral patellar tendon ruptures and obtained a good functional post-operative outcome following operative management through primary patellar tendon repair.

## Abstract

**Introduction:** Bilateral spontaneous patellar tendon ruptures are rare, though it is hypothesized to be more common in patients with risk factors such as connective tissue disorders such as Ehlers–Danlos syndrome (EDS), systemic disorders weakening collagen structures, chronic stress around the patellar tendon, medications, and obesity or sedentary lifestyles. Clinicians should maintain a high degree of clinical suspicion for concerning features on clinical examination and radiological investigations to facilitate prompt diagnosis and operative management. This case report describes the first documented case of an adult patient with EDS who sustained bilateral spontaneous patellar tendon ruptures. There is one previously reported acute bilateral patellar tendon rupture occurring in a pediatric patient with EDS. Within the adult literature, two case reports have reported patients with EDS: One acute unilateral patellar tendon rupture who underwent operative management and one chronic patellar tendon tear requiring reconstruction 2.5 years following initial end-to-end repair.

**Case Report:** A 45-year-old male sustained bilateral patellar tendon ruptures after falling onto his knees while pushing a heavy cart. The patient reported a giving-way sensation and was unable to mobilize independently. On presentation to the emergency department, the patient was noted to have an absent straight-leg raise and a palpable gap between the distal pole of the patella and patellar tendon. Plain radiograph and ultrasound investigations confirmed bilateral complete patellar tendon ruptures. The patient underwent operative management 5 days following injury through bilateral direct patellar tendon repair utilizing the Krackow technique with transosseous fixation. Twelve months post-operatively, the patient had returned to pre-injuries activities of daily living, a full active range of motion without extensor lag, and recorded “fair knee function” on the Lysholm Knee Scoring Scale.

**Conclusion:** This case report described the first reported bilateral spontaneous patellar tendon rupture in an adult patient with EDS, who underwent operative management and achieved a return to pre-injury function. Furthermore, this case report summarizes the pre-existing literature on spontaneous bilateral patellar tendon ruptures and patellar tendon ruptures in patients with EDS.

**Keywords:** Spontaneous patellar tendon rupture; bilateral patellar tendon rupture; Ehlers–Danlos syndrome tendon rupture.

## Introduction

Patellar tendon ruptures are the third most common cause of disruption to the knee extensor mechanism [1]. Ruptures may occur through trauma or spontaneously, defined as activities that

should not disrupt the musculotendinous unit [2]. Two theories exist on the pathogenesis of spontaneous ruptures: first, a microtrauma mechanical theory with traumatic bleeding into the synovial sheath with an intact fibrous sheath leading to increased intrasynovial pressure and hypoxia [3] and second, a vascular

Access this article online

Website:  
[www.jocr.co.in](http://www.jocr.co.in)

DOI:  
<https://doi.org/10.13107/jocr.2024.v14.i10.4834>

## Author's Photo Gallery



Dr. Helena Franco



Dr. David Fraser

<sup>1</sup>Department of Orthopaedic Surgery, The Prince Charles Hospital, Brisbane, Queensland, Australia.

### Address of Correspondence:

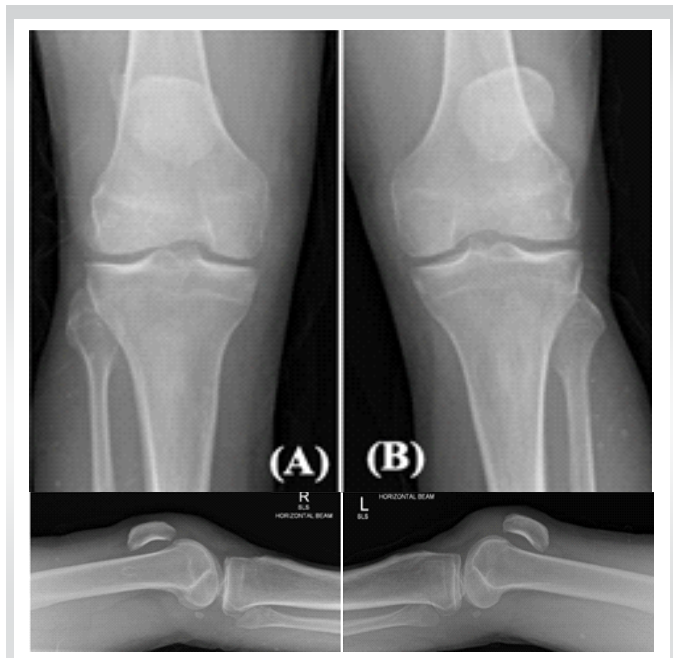
Dr. David Fraser,  
Department of Orthopaedic Surgery, The Prince Charles Hospital, Brisbane, Queensland, Australia.  
E-mail: David.Fraser@health.qld.gov.au

Submitted: 25/07/2024; Review: 14/08/2024; Accepted: September 2024; Published: October 2024

DOI: <https://doi.org/10.13107/jocr.2024.v14.i10.4834>

This is an open access journal, and articles are distributed under the terms of the Creative Commons Attribution-NonCommercial-ShareAlike 4.0 License <https://creativecommons.org/licenses/by-nc-sa/4.0/>, which allows others to remix, tweak, and build upon the work non-commercially, as long as appropriate credit is given and the new creations are licensed under the identical terms





**Figure 1:** Anteroposterior and lateral radiograph of (a) right knee and (b) left knee demonstrating patella alta.

theory based on age-related changes and sedentary lifestyle [4, 5]. Patellar tendon ruptures are typically unilateral and traumatic, occurring in younger patients [6]. Bilateral ruptures may be associated with systemic disorders that weaken collagen structures, such as renal failure [7], systemic lupus erythematosus [8], rheumatoid arthritis [9], hyperparathyroidism [10], and diabetes mellitus, connective tissue disorders, and medications including corticosteroids and anabolic hormones [11, 12]. Patients may present with weak or absent active knee extension, difficulty weight-bearing, generalized knee pain, significant effusion, palpable infrapatellar soft tissue defect, or high-riding patella [13]. Radiological investigations confirm the diagnosis including ultrasound and plain radiograph demonstrating a patella alta, indicated by the Insall-Salvati ratio more than 1.2 as calculated by the position of the patella relative to the tibial tuberosity [13]. Non-operative management may be considered in cases of partial rupture or low-mobility patients with medical comorbidities [14]. Surgical management options include primary repair and reconstruction. The location determines the type of primary repair: Ruptures at the origin (type 1) may have transosseous repair, mid-substance tears may have end-to-end repair (type 2), and distal avulsion tears (type 3) may require anchor repair [15]. Reconstruction with autograft or allograft may be required in severe or subacute cases [16]. Ehlers–Danlos syndrome (EDS), a genetic connective tissue disorder leading to altered fibrillar collagen metabolism [17], is diagnosed through examination, family history, and genetic

testing. There are six subtypes: Classical, hypermobility, vascular, kyphoscoliosis, arthrochalasia, and dermatosparaxis [18]. EDS is characterized by generalized joint hypermobility, atrophic scarring, excessive bruising, delayed wound healing, and increased skin elasticity [19]. Knee instability is the most commonly involved joint, possibly contributed to by quadriceps and hamstring weakness [20]. Collagen fibers constitute 70–80% of the patellar tendon dry weight [2], with EDS patellar tendons demonstrating lower biomechanical properties compared to controls [21]. Healthy patellar tendons which require a force of 17.5 times the patient's body weight to rupture [22], though EDS patients may require less force.

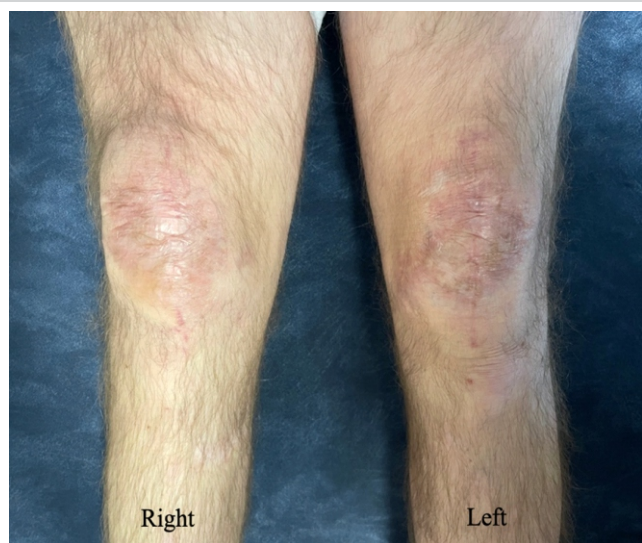
There have been three cases of spontaneous patellar tendon rupture in patients with EDS reported in the literature. First, Moretti et al. reported a 13-year-old child with EDS who sustained bilateral spontaneous patellar tendon ruptures after a fall while walking and underwent primary tendon repair 72 h following the injury [23]. Takata et al. reported a 27-year-old male with classic EDS who sustained a unilateral spontaneous patellar tendon rupture while walking downstairs and underwent primary repair with semitendinosus and gracilis augmentation 5 days following the injury [24]. Finally, Iacono et al. reported a 23-year-old man with vascular EDS who sustained a chronic patellar tendon tear 2.5 years following primary tendon repair [25]. The reported case describes an adult patient with classical EDS who sustained bilateral spontaneous patellar tendon ruptures while pushing a heavy trolley. The patient underwent direct tendon repair and obtained good post-operative recovery at 12-month follow-up.

### Case Report

A 45-year-old male presented to the Emergency Department after falling while pushing a heavy trolley. The reported mechanism involved the trolley beginning to fall, with the patient attempting to balance the trolley, leading to eccentric contraction of quadriceps muscles. Immediately following the injury, the patient was unable to mobilize. He was diagnosed with classical EDS on genetic testing as a child, presenting with skin hyperextensibility, joint hypermobility, and hypertrophic scars on bony protrusions. He did not have any other medical conditions or take regular medications. He worked as a retail assistant at a variety of department stores and was independent with activities of daily living.

### Clinical presentation

On examination of the right and left knee, there were palpable effusions, inability to actively straight leg raise, high riding patellae, and a palpable gap distal to the inferior pole of the patellae. Neurovascular examination was unremarkable. There



**Figure 2:** Clinical photograph demonstrating right and left knee wounds 3 months following surgery.

was a high clinical suspicion of bilateral patellar tendon ruptures given the palpable gaps, though differential diagnoses included patella fractures.

**Radiological features**

Plain radiographs (Fig. 1) of the knees demonstrated bilateral effusions, patella alta, and no fractures. Diagnosis of proximal patellar tendon tears was confirmed on ultrasound: The right knee ultrasound was reported to have a hematoma within the right patellar tendon, with a near complete loss of normal

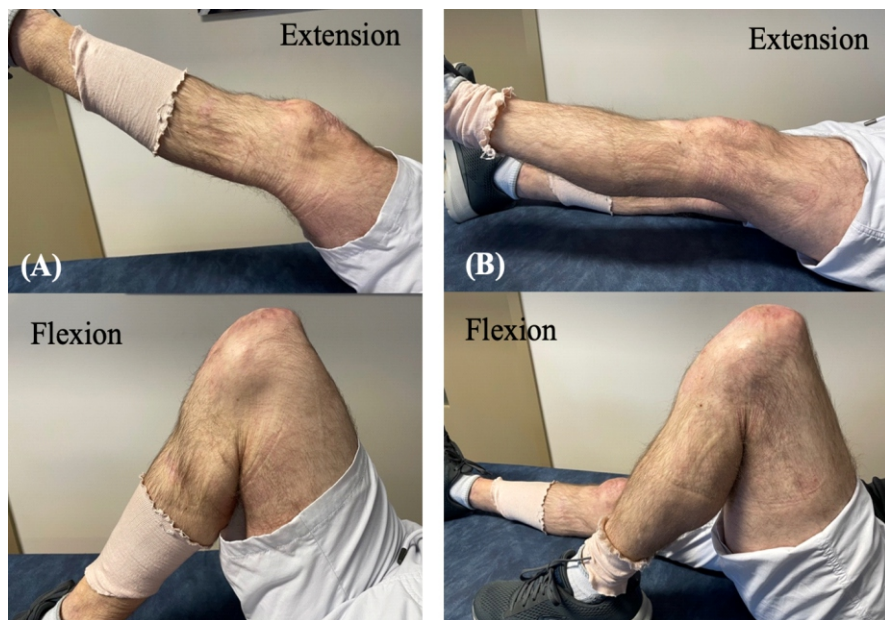
tendon fibers proximally and the left knee ultrasound was reported to show a complete tear involving the proximal aspect of the patellar tendon.

**Management and post-operative recovery**

The patient received temporary immobilization with bilateral knee splints in extension and underwent bilateral patellar tendon repairs 5 days following the injury. The patient underwent a general anesthetic and was positioned supine on a standard operating room table with a thigh tourniquet inflated to 300 mmHg. A midline incision was made with an anterior approach to the patella and patellar tendon. Intra-operatively, it was noted that the majority of the right patellar tendon was ruptured at the inferior pole of the patella and remained intact distally, while the left patellar tendon was completely avulsed from the inferior pole of the patella. Both sides were repaired with a braided polyblend suture, size 5 Fibrewire (Arthrex, Florida, USA) utilizing the Krackow technique and reinforced with transosseous fixation. The repair was ranged under direct visualization to ensure no gapping with flexion to 90°. The paratenon and retinaculum were repaired with a dissolvable suture, Vicryl (Ethicon, New Jersey, USA), and the skin was closed with non-absorbable nylon sutures (Ethicon, New Jersey, USA). The patient was immobilized in a DonJoy X-ROM post-operative knee brace (DJO Global, California, USA) locked in full extension for 1 week to protect the patient’s skin.

The patient was able to weight bear as tolerated and began supervised rehabilitation with physiotherapists on a graded

range of motion program: 0–30° flexion from 1 to 3 weeks post-operatively, 0–60° flexion from 3 to 5 weeks, and 0–90° from 5 to 7 weeks. On review 7 weeks post-operatively, the patient was able to straight leg raise without extensor lag and actively flex both knees to 105°, though was noted to have decreased quadriceps strength. He remained in the brace with unrestricted range and began quadriceps strengthening exercises. At 3 months post-operatively, his wounds were completely healed (Fig. 2), and he could achieve 135° flexion bilaterally. Following the wound healing, he commenced hydrotherapy and continued quadriceps strengthening exercises. At 6 months post-operatively, the patient could walk 100 m without crutches and 30 min with crutches, limited by quadriceps fatigue. On examination of



**Figure 3:** Clinical photograph of (A) right knee and (B) left knee demonstrating extension and maximum flexion 6 months following surgery.

his gait, he was noted to have a slight back knee gait due to quadriceps weakness on the right leg, though a normal left leg gait. Both knees had no palpable defect in the patellar tendon and achieved 140° flexion (Fig. 3a and b). He underwent an ultrasound which demonstrated both patellar tendons were intact. At 12 months, the patient achieved a full active range of motion without extensor lag. He had returned to pre-injury activities of daily living. He scored “fair” knee function on the Lysholm Knee Scoring Scale (score: 74 right; 69 left) [26] and 66.7% (right) and 67.8% (left) on the International knee documentation committee knee Score, with a higher score indicating better overall knee function [27].

**Discussion**

This reports the first adult EDS patient who sustained bilateral patellar tendon ruptures and describes the operative management through direct repair. Furthermore, the case expands on the paucity of literature surrounding operative management for EDS patients with patellar tendon ruptures and post-operative outcomes.

A literature review of unilateral or bilateral patellar tendon ruptures in pediatric or adult patients with EDS using PubMed, MEDLINE, and Scopus was conducted. The search was limited to full text and English language, which yielded three suitable case reports as summarized in Table 1. All three patients were male, with an average age of 21 years (range, 13–27 years). Two cases were acute patellar tendon ruptures, after a fall while walking (bilateral) and a fall down stairs (unilateral). One case

was a unilateral chronic patellar tendon tear diagnosed 2.5 years following initial bilateral patellar tendon ruptures managed with primary end-to-end repairs. All patients underwent surgical management, with the two acute cases undergoing primary repair ± augmentation with autograft and the chronic tear undergoing reconstruction with allograft.

The patient in the presented case report was 45 years old at the time of injury, which is higher than the previously reported cases in EDS patients (average: 21 years). However, the patient’s age is similar to the average age of 37.1 years reported by Fernandes et al. in a systematic review of simultaneous bilateral patellar tendon ruptures [28]. Previous literature has hypothesized age-related histological changes that may predispose patellar tendon ruptures, such as decreased elasticity, altered osteotendinous junction blood supply, and collagen degeneration [23]. While the low-energy mechanism of injury reported by the patient was similar to past case reports, age-related changes in conjunction with predisposition secondary to EDS may contribute to bilateral patellar tendons rupturing during eccentric contraction.

Acute patellar tendon ruptures often undergo surgical management. Fernandes et al. reviewed 45 cases of spontaneous bilateral patellar tendon ruptures managed surgically, with 88.9% (40/45) patients receiving direct primary repair and 11.1% (5/45) patients undergoing reconstruction [28]. However, there is no consensus in the literature on surgical techniques in patients with connective tissue abnormalities [20], with differences in management noted between the previously reported case studies of EDS patients with acute

Reference	Age (years)	Gender	Unilateral or bilateral	Mechanism of injury	Management	Follow-up
Iacono et al. [25]	23	Male	Unilateral	Fall walking downstairs	Chronic tear 2.5 years following initial injury requiring reconstruction with allograft. Post-operative immobilization in long-leg cylinder cast	6 months: active range of motion 10–120° flexion, walking without crutches
Moretti et al. [23]	13	Male	Bilateral	Fall while walking	Primary repair within 72 h using Vicryl suture through modified Bunnell technique and reinforced with wire cerclage. Post-operative immobilization: brace locked at 0 degrees extension	12 months: gradual resumption of athletic activities.
Takata et al. [24]	27	Male	Unilateral	Fall walking downstairs	Primary repair within 5 days using FibreWire suture through Krackow’s technique reinforced with transosseous sutures and augmentation with semitendinosus and gracilis. Post-operative immobilization: long-leg cylinder cast	12 months: walk without crutche, active range of motion 0-145° flexion, straight leg raise without extension lag

**Table 1: Cases of unilateral or bilateral patellar tendon ruptures in patients with Ehlers–Danlos syndrome reported in the literature.**



patellar tendon ruptures. Moretti et al., described primary repair in a pediatric EDS patient 72 h following injury with primary repair utilizing a Vicryl suture (Johnson and Johnson, Bruxelles, Belgium) through a modified Bunnell technique and reinforced with wire cerclage, followed by post-operative immobilization with a brace locked at full extension [23]. Takata et al., described primary repair in an adult patient 5 days following unilateral patellar tendon rupture using FiberWire (Arthrex, Munich, Germany) transosseous sutures through a Krackow's technique and augmented with semitendinosus and gracilis muscle, followed by post-operative immobilization in a long-leg cylinder cast [24]. At 12 months, the patient was able to walk without crutches and obtained an active range of motion to 145° flexion without extension lag. In comparison, the reported case describes an acute primary patellar tendon repair with utilizing the Krackow technique, reinforced with transosseous tunnels without autograft or allograft augmentation, and post-operative immobilization with a brace locked at full extension. At 12 months, the patient achieved similar clinical outcomes as the two previous case reports. While there is no reported medium or long-term follow-up for bilateral patellar tendon repairs in the literature [28], it is interesting to note Iacono et al., reported an EDS patient diagnosed with a unilateral chronic patellar tendon tear 2.5 years following bilateral primary end-to-end repairs at another

institution [25]. Further research is required to explore surgical repair and reconstruction techniques for patients with connective tissue disorders and subsequent post-operative outcomes.

### Conclusion

This case reports the first bilateral spontaneous patellar tendon rupture in an adult patient with EDS, who underwent operative management through primary tendon repair and returned to pre-injury function. As there is insufficient evidence for comparison between operative techniques, it is recommended that management should be individualized based on patient factors, concomitant injuries, and pre-injury functional capacity.

### Clinical Message

Spontaneous patellar tendon ruptures may be rare; however, clinicians should maintain a high degree of clinical suspicion with clinical examination and radiological features, particularly in patients with pertinent risk factors, such as EDS. The case report describes a 45-year-old male who sustained bilateral patellar tendon ruptures following a fall, underwent operative management utilizing the Krackow technique with transosseous fixation and obtained good functional outcome at 12 months.

**Declaration of patient consent:** The authors certify that they have obtained all appropriate patient consent forms. In the form, the patient has given the consent for his/ her images and other clinical information to be reported in the journal. The patient understands that his/ her names and initials will not be published and due efforts will be made to conceal their identity, but anonymity cannot be guaranteed.

**Conflict of interest:** Nil **Source of support:** None

### References

1. Enad JG. Patellar tendon ruptures. *South Med J* 1999;92:563-6.
2. Savarese E, Bisicchia S, Amendola A. Bilateral spontaneous concurrent rupture of the patellar tendon in a healthy man: Case report and review of the literature. *Musculoskelet Surg* 2010;94:81-8.
3. Knorz E, Folkhard W, Geercken W, Koch MH, Hilbert B, Krahl H, et al. New aspects of the etiology of tendon rupture. An analysis of time-resolved dynamic-mechanical measurements using synchrotron radiation. *Arch Orthop Trauma Surg* (1978) 1986;105:113-20.
4. Kannus P, Józsa L. Histopathological changes preceding spontaneous rupture of a tendon. A controlled study of 891 patients. *J Bone Joint Surg Am* 1991;72:1507-5.
5. Engkvist O, Lundborg G. Rupture of the extensor pollicis longus tendon after fracture of the lower end of the radius--a clinical and microangiographic study. *Hand* 1979;11:76-86.
6. Tarazi N, O'loughlin P, Amin A, Keogh P. A rare case of bilateral patellar tendon ruptures: A case report and literature review. *Case Rep Orthop* 2016;2016:6912968.
7. Caldas MT, Barbara GH, Barbara MB. Simultaneous bilateral rupture of the patellar ligament in chronic renal patient. A case report. *Rev Bras Ortop* 2013;48:455-9.
8. Lu M, Johar S, Veenema K, Goldblatt J. Patellar tendon rupture with underlying systemic lupus erythematosus: A case report. *J Emerg Med* 2012;43:e35-8.

9. Peiro A, Ferrandis R, Garcia L, Alcazar E. Simultaneous and spontaneous bilateral rupture of the patellar tendon in rheumatoid arthritis. A case report. *Acta Orthop Scand* 1975;46:700-3.
10. Chen CH, Niu CC, Yang WE, Chen WJ, Shih CH. Spontaneous bilateral patellar tendon rupture in primary hyperparathyroidism. *Orthopedics* 1999;22:1177-9.
11. Clark SC, Jones MW, Choudhury RR, Smith E. Bilateral patellar tendon rupture secondary to repeated local steroid injections. *J Accid Emerg Med* 1995;12:300-1.
12. Stinner DJ, Orr JD, Hsu JR. Fluoroquinolone-associated bilateral patellar tendon rupture: A case report and review of the literature. *Mil Med* 2010;175:457-9.
13. Rose PS, Frassica FJ. A traumatic bilateral patellar tendon rupture, a case report and review of the literature. *J Bone Joint Surg Am* 2001;83:1382-86.
14. Murphy SM, McAleese T, Elghobashy O, Walsh J. Bilateral patellar tendon rupture following low-energy trauma in a young patient without predisposing risk factors. *Trauma Case Rep* 2022;40:100643.
15. Courtney PM, Edmiston TA, Pflederer CT, Levine BR, Gerlinger TL. Is there any role for direct repair of extensor mechanism disruption following total knee arthroplasty? *J Arthroplasty* 2018;33:S244-8.
16. Camarda L, D'Arienzo A, Morello S, Guarneri M, Balistreri F, D'Arienzo M. Bilateral ruptures of the extensor mechanism of the knee: A systematic review. *J Orthop* 2017;14:445-53.
17. Byers PH. Inherited disorders of collagen gene structure and expression. *Am J Med Genet* 1989;34:72-80.
18. Beighton P, Paepe AD, Steinmann B, Tsipouras P, Wenstrup RJ. Ehlers-Danlos syndromes: Revised nosology, Villefranche, 1997. Ehlers-danlos national foundation (USA) and ehlers-danlos support group (UK). *Am J Med Genet* 1998;77:31-7.
19. Jensen JK, Nygaard RH, Svensson RB, Hove HD, Magnusson SP, Kjær M, et al. Biomechanical properties of the patellar tendon in children with heritable connective tissue disorders. *Eur J Appl Physiol* 2018;118:1301-7.
20. Homere A, Bolia IK, Juhan T, Weber AE, Hatch GF. Surgical management of shoulder and knee instability in patients with ehlers-danlos syndrome: Joint Hypermobility syndrome. *Clin Orthop Surg* 2020;12:279-85.
21. Nielsen RH, Couppe C, Jensen JK, Olsen MR, Heinemeier KM, Malfait F, et al. Low tendon stiffness and abnormal ultrastructure distinguish classic Ehlers-Danlos syndrome from benign joint hypermobility syndrome in patients. *FASEB J* 2014;28:4668-76.
22. Zernicke RF, Garhammer J, Jobe FW. Human patellar-tendon rupture. *J Bone Joint Surg Am* 1977;59:179-83.
23. Moretti B, Notarnicola A, Moretti L, Garofalo R, Patella V. Spontaneous bilateral patellar tendon rupture: A case report and review of the literature. *Chir Organi Mov* 2008;91:51-5.
24. Takata Y, Nakase J, Numata H, Oshima T, Tsuchiya H. Repair and augmentation of a spontaneous patellar tendon rupture in a patient with Ehlers-Danlos syndrome: A case report. *Arch Orthop Trauma Surg* 2015;135:639-44.
25. Iacono V, Cigala F, Fazioli F, Rosa D, Maffulli N. Reconstruction of chronic patellar tendon tear with allograft in a patient with Ehlers-Danlos syndrome. *Knee Surg Sports Traumatol Arthrosc* 2010;18:1116-8.
26. Lysholm J, Gillquist J. Evaluation of knee ligament surgery results with special emphasis on use of a scoring scale. *Am J Sports Med* 1982;10:150-4.
27. Irrgang JJ, Anderson AF, Boland AL, Harner CD, Kurosaka M, Neyret P, et al. Development and validation of the international knee documentation committee subjective knee form. *Am J Sports Med* 2001;29:600-13.
28. Fernandes A, Rufino M, Hamal D, Mousa A, Fossett E, Cheema KS. Simultaneous bilateral patellar tendon rupture: A systematic review. *Cureus* 2023;15:e41512.

**Conflict of Interest:** Nil  
**Source of Support:** Nil

**Consent:** The authors confirm that informed consent was obtained from the patient for publication of this case report

#### How to Cite this Article

Franco H, Fraser D. Spontaneous Bilateral Patellar Tendon Rupture in Patient with Ehlers–Danlos Syndrome: A Case Report.. *Journal of Orthopaedic Case Reports* 2024 October;14(10):124-129.

