Case Report | Journal of Orthopaedic Case Reports 2022 March:12(3):Page 104-108

Surgical Dislocation of the Hip through Lateral Approach for the Treatment of Synovial Chondromatosis

Sarthak Parikh[1], Mitchell Hunter[1], Eric Heidemann[1], Stephen Forro[1], Ty Davis[1], Arturo Corces[1]

Learning Point of the Article:

The surgical treatment through the lateral approach for synovial chondromatosis is described in this paper and has been shown to have positive outcomes.

Abstract

Introduction: Synovial chondromatosis is a condition where the cells lining a joint form benign cartilaginous tumors. This benign cartilage metaplasia results in the formation of multiple intra-articular loose bodies within a joint.

Case Report: This case is a 59-year-old female that presented with constant, severe left hip pain that was localized to the groin and began 2 years ago. There were severe limitation of hip flexion, extension, pain on internal rotation, and a half inch left leg shortening. Radiographs demonstrated multiple round opacities surrounding the left femoral neck. MRI showed numerous, small rounded intra-articular loose bodies, measuring about 5–6 mm each within the left hip joint.

Surgical Technique: A lateral approach toward the hip was used to perform an osteotomy at the portion of the greater trochanter. The hip capsule was identified and an S-shaped incision was then made through the capsule. Repetitive hip dislocations allowed for improved visualization making further removal of the difficult fragments much easier. The capsule was closed and the osteotomy was reattached. Range of motion was found to be significantly improved compared to preoperatively. No further fixation was necessary and the patient's subcutaneous tissue was closed in normal fashion.

Conclusion: The technique used in our case involves a lateral approach with a trochanteric flip osteotomy to preserve the medial femoral circumflex artery and external rotators. This is similar to the approach described by Ganz in 2001 who used a posterior approach. Following the approach, the hip is then dislocated and exposed anteriorly with full visualization of the joint with a gap of about 11 cm between the femoral head and acetabulum. Surgical dislocation allows for the removal of difficult chondromas and osteophytes around the femoral head-and-neck junction. Multiple studies support the idea of surgical dislocation as an exceptional treatment method for SC.

Keywords: Synovial chondromatosis, Surgical approach, Lateral approach, Surgical dislocation, Synovial, Chondromatosis, Osteochondromatosis, Chondrosis, Reichel syndrome, Chondrometaplasia.

Introduction

Synovial chondromatosis (SC) – also known as synovial osteochondromatosis, synovial chondrosis, Reichel syndrome, or synovial chondrometaplasia – is a condition where the cells lining a joint form benign cartilaginous tumors. This benign cartilage metaplasia results in the formation of multiple intra-articular loose bodies within a joint. Rarely, they may have extra-articular manifestations in tenosynovial structures such as bursae or tendon sheaths [1]. SC typically involves diarthrodial weight-bearing joints in young adults ages 30–50 with a 2-to-1 predominance in males. The exact incidence and prevalence of this disease are unknown, however, approximately 70% of SC

Access this article online

Website: www.jocr.co.in

DOI: 10.13107/jocr.2022.v12.i03.2738

Author's Photo Gallery

Dr. Sarthak Parikh | Dr. Mitchell Hunter | Dr. Eric Heidemann | Dr. Stephen Forro | Dr. Ty Davis | Dr. Arturo Corces

[1]Department of Orthopaedic Surgery, Larkin Community Hospital, South Miami, Florida.

Address of Correspondence:
Dr. Arturo Corces,
Department of Orthopaedic Surgery, Larkin Community Hospital, South Miami, Florida.
E-mail: corces@bellsouth.net

Submitted: 10/10/2021; Review: 18/12/2021; Accepted: February 2022; Published: March 2022

DOI:10.13107/jocr.2022.v12.i03.2738

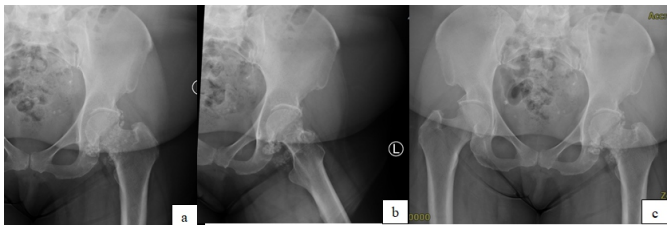

Figure 1: Pre-operative imaging from clinical encounter. Anteroposterior (a), frog-leg lateral left hip (b), and anteroposterior pelvis (c) radiographic views demonstrate multiple left hip intra-articular calcifications surrounding the femoral neck. There is also noted to be left hip joint space narrowing.

cases involve the knee joint and 20% manifest in the hip joint. More than 30 other joints, including the shoulder, TMJ, elbow, ankle, and wrist, have also been reported [1]. The exact pathophysiology has not been identified, however, high levels of BMP-2 and BMP-4 have been isolated from diseased synovium and free bodies [2].

SC can be separated into primary and secondary conditions. Primary SC represents idiopathic chondroid metaplasia in the synovium of a joint with formation of multiple intra-articular chondral bodies. Secondary SC is more common and is associated with joint abnormalities and pre-existing conditions such as osteoarthritis, rheumatoid arthritis, osteonecrosis, osteochondritis dissecans, neuropathic osteoarthropathy, tuberculosis, or osteochondral fractures [1, 2, 3, 4]. In 1977, Milgram studied the pathologic process of SC and described the progression of primary SC as three phases; Phase 1 represents active intrasynovial disease without loose bodies. Phase 2 is characterized by transitional lesions with osteochondral nodules in the synovial membrane and osteochondral bodies lying free in the joint cavity. Phase 3 has multiple osteochondral bodies with latent intra-synovial disease [2, 5].

Patients with SC typically experience insidious onset of symptoms such as decreased range of motion, pain, swelling, crepitus, as well as locking and stiffness that are worse with activity. Physical examination may present with warmth, effusion, erythema, or tenderness without obvious deformity. Histologic evaluation may show hyaline cartilage nodules in various stages of calcification and ossification [2]. Chondrocytes with mild atypia, binucleate cells, and occasional mitosis may be seen. This pathology may resemble synovial chondrosarcoma, however, SC rarely has malignant transformation (5%) [6]. Radiologic findings are pathognomonic for SC. In 70–95% of cases, radiographs will show multiple intra-articular calcifications of similar size, shape, and distribution throughout the joint. Stippling calcification and a "ring and arc" chondroid mineralization may also be present. Extrinsic bone erosions are seen in 20–50% of cases [4]. MRI of SC may show intermediate signal intensity on T1-weighted imaging and high signal intensity on T2-weighted imaging [2].

SC management is determined by the patient's severity of symptoms. Patients may undergo observation and pain management with anti-inflammatory medications when their symptoms are mild with little to no motion restriction. Operative intervention with synovectomy and loose body resection is indicated in patients with severe symptoms and range of motion impairment. Arthroplasty is another option in patients with severe symptoms and coinciding osteoarthritis [2, 7, 8, 9].

The purpose of this case report is to present a case of SC of the hip joint which was treated operatively with the use of a novel technique utilizing a lateral approach combined with surgical dislocation of the hip.

Case Report

A 59-year-old female with a medical history of hypertension and hyperlipidemia presented to the joint reconstruction clinic with a chief complaint of the left hip pain that began 2 years ago. She described the pain as severe and constant. It was localized to the groin and worse with ambulation and standing for long periods of time. She was only able to ambulate 1–2 blocks with an assistive device. She denied any history of trauma. She had no previous surgery to the left hip. Physical examination demonstrated an antalgic gait. Lower left extremity range of motion decreased with extension to 0 degrees. There was severe limitation of hip flexion as well as limitation and pain with

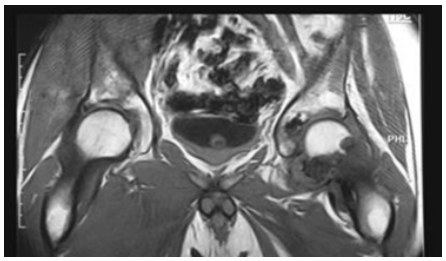

Figure 2: Pre-operative MRI imaging of B/L hip.

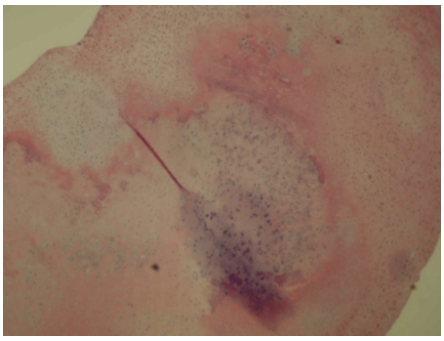

Figure 3: Actual pathological slide demonstrating synovial chondromatosis.

Figure 4: Post-operative radiograph of the left hip at 2 weeks.

nternal rotation. Approximately a half inch shortening of the left leg was also noted. Radiographic examination demonstrated multiple round opacities surrounding the left femoral neck without any fractures or dislocations (Fig. 1). The left hip MRI showed mild marginal osteophyte formation at the femoral head and neck junction (Fig. 2). There was also noted to be numerous, small rounded intra-articular loose bodies, measuring about 5–6 mm each within the left hip joint. There was thinning of the articular cartilage without significant fissuring or fraying.

In a patient such as this with refractory severe symptoms, surgical management was chosen. Due to the patient's young age and preserved joint surface, we opted for open radical removal of the synovium and loose bodies.

Surgical technique

The patient was placed in the lateral decubitus position on a radiolucent table with a peg board for positioning. A lateral approach was performed. An incision was made on the lateral aspect of the hip, which was taken down through the subcutaneous tissue. The fascia was cut and the Charnley retractor was inserted to protect the blood supply to the femoral head. Surgical dislocation of the hip was performed using a modified lateral approach with an anterior osteotomy and retention of the gluteus medius. Hemostasis was achieved and the superior gluteal nerve was identified to prevent any damage.

The anterior edge of the gluteus medius was identified and a retractor was inserted. The anterior portion of the greater trochanter incorporating the insertion of the gluteus minimus was identified. An osteotomy was performed at this portion of the greater trochanter with an oscillating saw. The osteotomy fragment was then retracted anteriorly. The hip capsule was identified. An S-shaped incision was then made through the capsule and the hip joint was entered. Immediately after the arthrotomy of the hip, numerous small floating fragments consistent with SC erupted through the arthrotomy site and were carefully removed. It was noted that dislocation of the hip allowed for improved visualization making further removal of the fragments much easier. Using a variety of instruments, we located and removed multiple loose intra-articular fragments. The joint required multiple dislocations and reductions to remove any remaining fragments that were lodged deep in the sulcus.

On further evaluation, the acetabulum did not display any specific evidence of arthritis. Attention was then turned to the patients femoral neck in which an osteotome was used to remove any remaining osteophytes. Following this, the femoral head was carefully evaluated and was normal in appearance. An intraoperative radiograph of the hip was then obtained to ascertain that all of the loose bodies had been removed.

After a final evaluation of the acetabulum was performed, the hip was reduced and the capsule was repaired with non-absorbable sutures. Closure of the trochanteric osteotomy was performed using cable ties (Arthrex). The cable tie was inserted through the trochanter and around the trochanteric fragment and pulled taut to achieve reduction. Non-absorbable sutures were placed through the vastus lateralis as well as the gluteus medius which held the greater trochanter together. The patient was taken through a range of motion and noted to be extremely stable. Range of motion was found to be significantly improved compared to preoperatively. No further fixation was necessary and the patient's subcutaneous tissue was closed in normal fashion.

Loose bodies were sent for further pathologic analysis. Histologically, they displayed discrete hyaline cartilage nodules in various stages of calcification and chondrocytes with mild atypia consistent with chondromatosis and negative for malignancy (Fig. 3). Postoperatively, she was restricted to partial weight-bearing with crutches for 4 weeks followed by weight-bearing as tolerated. Post-operative X-rays at 2 weeks showed no recurrence of loose bodies (Fig. 4).

Discussion

The purpose of this case report is to present a case of SC and provide a novel surgical technique utilizing a lateral approach combined with surgical dislocation of the hip for the treatment of SC.

The exact prevalence of primary SC is unknown; however, it has an incidence of about 1:100,000 [10]. Although malignant transformation is rare, a 2015 study by Evans demonstrated that of 800 patients with chondrosarcoma, five originated from SC (0.6%) [11]. It is also important to note that recurrence of this pathology is high despite adequate surgical intervention [4].

Multiple treatment methods have been previously utilized to treat SC including radiotherapy, arthroplasty, open arthrotomy, and arthroscopy [7, 8, 12, 13]. The premise of radiotherapy as a treatment for SC parallels the treatment for heterotopic ossification (HO). Radiotherapy in HO targets what is believed to be the differentiation of pluripotent mesenchymal cells into osteoblastic stem cells. Similarly, in SC, it appears that fibroblasts in the synovial stroma are converted to a chondroblast mass with an osteocyte core. Radiotherapy may be beneficial for cases refractory to standard surgical, however, its role needs to be further explored [12, 14].

Traditionally, open arthrotomy with a removal of loose bodies with either a partial or full synovectomy was preferred. With increasing familiarity of arthroscopy, arthroscopic examination

and excision have become more popular. Arthroscopy, however, may be more technically demanding and increases the risk of intra-articular cartilage damage. More specifically, approaching the posterolateral and posteromedial areas of the peripheral compartment may be difficult [15]. In cases of patients with preexisting hip osteoarthritis, arthroscopic treatment may not even be possible. Some fragments of SC may also be too large in diameter for arthroscopically assisted removal. According to a study by Marchie et al., patients with fragments <10 mm and/or a Grade I/II cartilage change in the hip gained the most benefit from arthroscopy [16]. Overall, hip arthroscopy is linked to longer operative time, but with satisfactory patient recovery [13, 17, 18].

Hip arthroplasty may be considered if the patient has underlying moderate-to-severe osteoarthritis. Arthroplasty with simultaneous synovectomy can provide pain relief and has excellent survival at long-term follow-up; however, revision and complication rates have shown to be high [7, 19].

SC may also present simultaneously with other conditions such as femoral acetabular impingement (FAI). Although this can be treated arthroscopically, FAI can also be easily visualized through the use of open techniques such as surgical dislocation of the hip. This being said, in cases with multiple conditions that need to be addressed simultaneously, this procedure may be the most efficient [20]. This approach uses an anterior dislocation technique which protects the blood supply and allows for full visualization of the hip joint. Again, the benefit of this treatment approach is the ability to manage both intra-articular and extra-articular pathologic lesions about the hip. It has a short surgical time and produces satisfactory joint function with low recurrence rate and few complications when done meticulously [21]. Furthermore, the recurrence rate of SC is higher in those treated with synovectomy alone than with synovectomy and dislocation with the hip [17].

The technique used in our case involves a lateral approach with a trochanteric flip osteotomy to preserve the medial femoral circumflex artery and external rotators. This is similar to the approach described by Ganz in 2001, which used a posterior approach [22]. Following the approach, the hip is then dislocated and exposed anteriorly with full visualization of the joint with a gap of about 11 cm between the femoral head and acetabulum. On the contrary, an anterior approach can also allow for a safe femoral head dislocation, however, unless the tensor fascia lata and gluteus medius are extensively detached from their origins, inspection of the joint is limited [22].

Our patient with SC presented with multiple opacities around the hip which were difficult to quantify. Surgical intervention indicated for this patient as the pain was severe and range of motion was limited. The femoral head and acetabulum showed little degenerative joint disease, and therefore, arthroplasty was avoided. Instead, the surgical dislocation technique with osteotomy was used to open the hip capsule and remove loose bodies with clear visualization. Surgical dislocation also allowed for the removal of osteophytes around the femoral head and neck junction. Arthroscopy would not have allowed for better visualization of the joint and would have made removal of larger stones difficult. Furthermore, complications such as avascular necrosis of the femoral head were avoided as the obturator externus was identified and avoided. Multiple studies support the idea of surgical dislocation as an exceptional treatment method for SC [13, 17, 20, 21, 23]. Nevertheless, treatment modality should be individualized for each patient.

Conclusion

The procedure described in this case report utilizes a modified Ganz technique that involves a lateral approach with a trochanteric flip osteotomy to preserve the medial femoral circumflex artery and external rotators. The hip is then dislocated anteriorly, which allows for exception visualization of the joint and easy removal of the numerous chondromas associated with SC. This treatment modality may be better than arthroscopic treatment of SC, as it makes removal of chondromas simple and addresses multiple pathologies simultaneously. This is a novel surgical technique that has not been described in the current literature.

Clinical Message

Treatment of SC with the removal of loose bodies using a lateral incision, trochanteric flip osteotomy, and an anterior dislocation method has been described and shown to be favorable in this case report. Future surgical intervention of SC should consider using this approach as the treatment modality.

Declaration of patient consent : The authors certify that they have obtained all appropriate patient consent forms. In the form, the patient has given the consent for his/her images and other clinical information to be reported in the journal. The patient understands that his/her names and initials will not be published and due efforts will be made to conceal their identity, but anonymity cannot be guaranteed.

Conflict of interest: Nil **Source of support:** None

References

1. Bergstrand H. Uber eine eigenartige, warscheinlich bisher nicht beschriebene osteoblastische Krankheit in den langen Knochen in der Hand und des Fusses. Acta Radiol 1930;11:596-613.
2. Jaffe HL. Osteoid osteoma: A benign osteoblastic tumour composed of osteoid and atypical bone. Arch Surg 1935;31:709-28.
3. Unni KK, Dahlin DC. Osteoid osteoma. In: Dahlin's Bone Tumors. 5th ed. Philadelphia, PA: Lippincott Williams and Wilkins; 1996. p. 121-30.
4. Freiberger RH. A cause of backache and scoliosis in children and young adults. Radiol 1960;75:232-6.
5. Sim FH, Dahlin DC, Beaubout J. Osteoid-osteoma: Diagnostic problems. J Bone Joint Surg (Am) 1975;57A:154-8.
6. Girard J, Bequet E, Limousin M, Chantelot C, Fontaine C. Osteoma osteoid of trapezoid bone: A case-report and review of the literature. Chir Main 2005;24:35-8.
7. Gonzalez G, Abril JC, Mediero IG, Epeldegui T. Osteoid osteoma with a multicentric nidus. Int Orthop 1996;20:61-3.
8. Greenspan A. Benign bone-forming lesions: Osteoma, osteoid osteoma, and osteoblastoma. Clinical, imaging, pathologic and differential considerations. Skeletal Radiol 1993;22:485-500.
9. Iceton J, Rang M. An osteoid osteoma in an open distal femoral epiphysis. A case report. Clin Orthop Relat Res 1986;206:162-5.
10. Allen SD, Saifuddin A. Imaging of intra-articular osteoid osteoma. Clin Radiol 2003;58:845-52.
11. Saidi H, El Bouanani A, Ayach A, Fikry T. Ostéome ostéoïde du lunatum: À propos d'un cas. Chir Main 2007;26:173-5.
12. Soon M, Lou CK. Chew osteoid osteoma after a stress fracture of the tibia. J Ann Acad Med Singapore 1999;28:877-8.

Conflict of Interest: Nil
Source of Support: Nil

Consent: The authors confirm that informed consent was obtained from the patient for publication of this case report

How to Cite this Article

Parikh S, Hunte M, Heidemann E, Forro S, Davis T, Corces A. Surgical Dislocation of the Hip through Lateral Approach for the Treatment of Synovial Chondromatosis. Journal of Orthopaedic Case Reports 2022 March;12(3): 104-108.