

Spondyloptosis at Subaxial Cervical Spine with Minimal Neurological Compromise and Complete Recovery: A Rare Case Report

Nilesh Barwar¹, Nitish Kumar², Rajnand Kumar², Amit Sharma¹, Milind Chandra Choudhary²

Learning Point of the Article:

Early reduction, decompression and stabilization of Cervical Spine Injuries can help in neural recoveries.

Abstract

Introduction: Subaxial cervical spine (C3-7) injuries are among the most common and potentially most devastating injuries involving the axial skeleton. The treatment of fracture dislocations of the cervical spine still varies. Early operative treatment has gained increasing acceptance. This case report will discuss a case of subaxial cervical spine fracture dislocation and spondyloptosis with minimal neurological compromise and after reduction and stabilization, complete recovery of neurological functional was achieved.

Case Report: A 26-year-old male patient presented to emergency department with history of road traffic accident with injury to his neck having complain of severe neck and shoulder pain and weakness in the right upper limb. On clinical and radiological evaluation, it was diagnosed a case of high-grade anterolisthesis C5 over C6 (spondyloptosis) with neurological compromise. Surgical intervention was done within 48 h with complete neurological recovery.

Conclusion: Satisfactory clinical and good long-term outcome can be obtained in fracture dislocation of subaxial cervical spine by anterior approach, discectomy, and anterior cervical plating.

Keywords: Subaxial spine, spondyloptosis, discectomy, cervical plating.

Introduction

Injuries of the sub-axial cervical spine (C3-7) are among the most common and potentially most devastating injuries involving the axial skeleton. The cervical spine often is injured in motor vehicle accidents and falls, resulting in bony or soft-tissue injury; however, the presence of multiple traumatic injuries may distract the examiner from the cervical spine. In the evaluation of the polytrauma patient, examination of the cervical spine is of utmost priority and must take precedence, along with maintenance of airway. The treatment of fracture dislocations of the cervical spine still varies. Several reports on various treatment protocols

have been published, but surprisingly few [1, 2] have compared their benefits and drawbacks. The treatment protocol for acute cord injury has no clear consensus regarding timing of decompression, but few studies including animal studies do support early decompression for better outcome in patients with bifacetal dislocation and incomplete cord injury with deteriorating neural function.[2, 3, 4]. (I do not agree with the statement that there is controversy in management of acute traumatic fracture dislocation of spine in terms of operative management. The references quoted are for unilateral facet dislocation and not for fracture dislocation. In recent years, the early

Access this article online

Website:
www.jocr.co.in

DOI:
<https://doi.org/10.13107/jocr.2022.v12.i12.3490>

Author's Photo Gallery



Dr. Nilesh Barwar



Dr. Nitish Kumar



Dr. Rajnand Kumar



Dr. Amit Sharma



Dr. Milind Chandra Choudhary

¹Department of Orthopedics, All India Institute of Medical Sciences, Bhatinda, Punjab, India,
²Department of Orthopaedics, All India Institute of Medical Sciences, Gorakhpur, Uttar Pradesh, India.

Address of Correspondence:

Dr. Nitish Kumar,
Department of Orthopedics, All India Institute of Medical Sciences, Gorakhpur, Uttar Pradesh, India.
E-mail: nitishaiims@gmail.com

Submitted: 08/09/2022; Review: 09/10/2022; Accepted: November 2022; Published: December 2022

DOI: <https://doi.org/10.13107/jocr.2022.v12.i12.3490>

This is an open access journal, and articles are distributed under the terms of the Creative Commons Attribution-NonCommercial-ShareAlike 4.0 License <https://creativecommons.org/licenses/by-nc-sa/4.0/>, which allows others to remix, tweak, and build upon the work non-commercially, as long as appropriate credit is given and the new creations are licensed under the identical terms

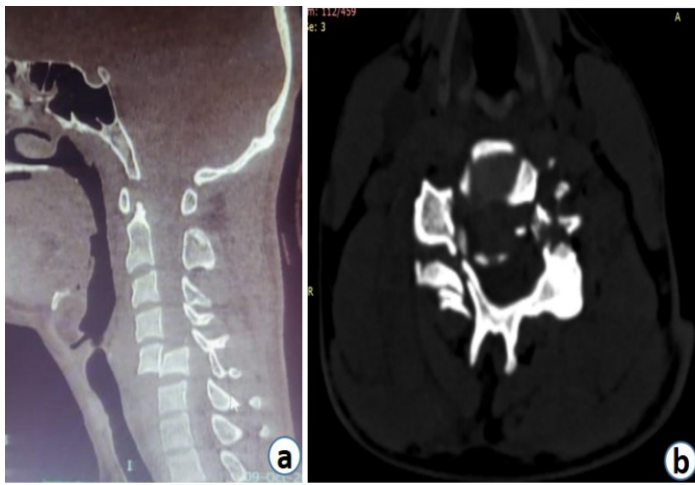


Figure 1: Figure 1: CT Mmid Ssagittal section (a) shows spondyloptosis of C5 over C6. The C5 vertebral body is lying just anterior to the C6 vertebral body. Axial CT (b) scan of the cervical spine shows right lateral mass complex is floating and left pedicle is broken for the C5 vertebral body. The remaining posterior arch is left behind. As a result, the overall spine canal size seems widened.

operative treatment has gained increasing acceptance [5]. We report a case of sub-axial cervical spine fracture dislocation and spondyloptosis with minimal neurological compromise and after reduction and stabilization, complete recovery of neurological function. (please correct the spellings).

Case Presentation

A 26-year -old ambulatory male patient presented to the emergency department with alleged history of road traffic accident with injury to his neck. He complained of severe neck and right shoulder pain along with weakness in the right upper limb.

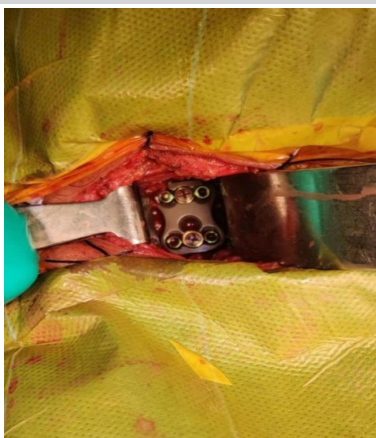

Figure 3: Intraoperative image showing reduction and fixation with anterior plate.

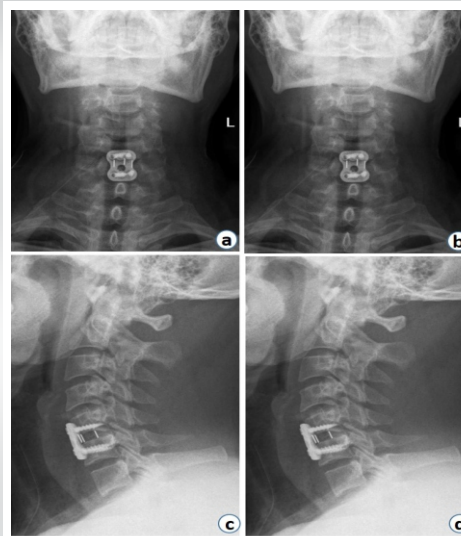


Figure 4: Post Post-operative X-rays: AP (a) and Lateral view (b) show well -aligned cervical spine with implant in-situ.

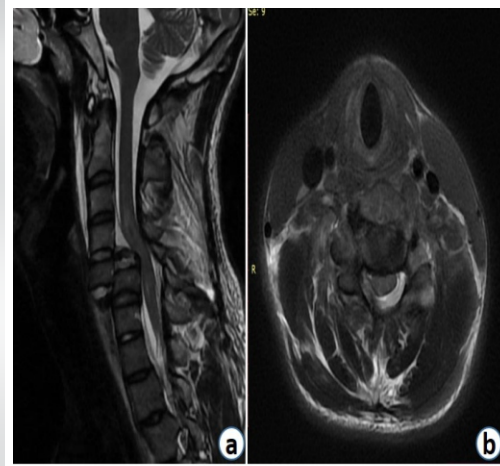


Figure 2: Figure 2: MRI T2 sagittal image (a) and T2 axial limage (b) sequence show a fracture dislocation and kinking of the cord.

He had 2 t w o episodes o f vomiting a f t e r injury. T h e patient had a history of difficulty i n micturition a n d had t o p u t pressure for voiding,; however, complete urinary retention was n'ot there. The patient was catheterized with 14 Fr Foley's Catheter to relieve of his symptoms. In addition, the patient did not pass stool since the injury.(what do you mean by altered Bowel bladder habit). On primary survey, he was conscious and oriented to place, time, and persons. His vital parameters likesuch as respiratory rate, pulse rate, blood pressure, and oxygen saturation etc. were within normal limits. There was no tenderness over chest, abdomen, pelvis, and long bones on complete systemic examination of the patient done with adequate exposure. On local examination of the neck (with head stabilized as per standard ATLS protocol), there was a midline bony tenderness with painful and restricted neck motion. As Ccervical (write full forms) spine injury was suspected, a Philadelphia collar was applied around the neck. He had weak hand grip in the right side with motor weakness in the shoulder abduction and forward flexion (Power as per Medical Research Council (write full forms) grading-2/5), with ipsilateral triceps (C7) and biceps (C5) weakness (each 3/5).(it would be better if you mention the power examination based on myotomes). The skin sensation was decreased in C5 to T1 dermatomes in the same side. On neurological examination in the lower limb, the power in hip flexor, knee extensor, ankle dorsi-flexor, and plantar-flexor was 5/5 on both side with intact sensation in each dermatome below T2 including



perianal sensation. Planter response was equivocal. The other deep tendon reflexes and superficial reflexes of both lower limbs were normal. The patient was able to feel the sensation of catheter on gentle pull on indwelling Foley's catheter (Catheter Tug Test). (Please write complete neurological exam with reflexes and if there were any other injuries seen on examination).

Investigations

Non-contrast CT Cervical spine was done (Figure. 1a and 1b). There were multiple comminuted fractures of anterior and posterior elements of C5 vertebra causing Grade V anterolisthesis of C5 over C6 (Spondyloptosis). The spinal canal at the injury level seemed to be widened because of due to injured and posteriorly displaced posterior elements.

A fracture of the left lamina of the C4 and right lamina of the C6 extending into foramen transversarium were also seen.

CT chest: B/L ribs fracture with minimal pneumothorax, minimal left-sided hemothorax, and B/L lung contusions.

CT Brain: There was no evidence of any intracranial bleeding in the CT scan.

MRI spine: Post-traumatic spondyloptosis of C5 over C6 with kinking of the cervical spine cord was seen (Figure. 2a and 2b).

Procedure:

Preoperatively, traction of 6.5 kg was applied using a Gardner-Wells tongs and slight reduction of the listhesis was noted. Complete reduction was not achieved even under general anesthesia. (no abbreviations please at least in first when you introduce the terms). Transverse incision from medial border of the right sterno-cleidomastoid to midline was given. After reaching to the injured area, the traumatized and ruptured disc at C5-C6 was removed using Kerrison rongeur. The injured PLL was also removed and complete decompression of the cord was achieved. Dislocation was reduced using Caspar pins in each body with some manipulation. During manipulation and reduction, iatrogenic dural injury occurred which was sutured by 5-0 Prolene (what suture size and make??) under microscope and fibrin glue applied. Inter body fusion was done using a PEEK cage with autologous cancellous bone graft and single level anterior cervical plate (Medtronic). Name of implant company??

Post-operative course:

No new neurological deficit was noted after surgery. The case was followed up on regular interval and the final follow-up was until 13 months after the surgery.

Neurological assessment at the final follow-up:

His right-hand grip improved and became comparable to his normal side. The weakness around his right shoulder and elbow improved and there was no apparent deficit. Deep tendon reflexes were normal in both upper and lower limbs with improvement in his sensory functions. His bowel and bladder functions became regular with time. At the operated area, an intervertebral fusion was noted at the final follow-up with intact implant assembly.

Discussion

Almost two-thirds of cervical spine injuries occur within the sub-axial cervical spine, with dislocations occurring most commonly at C5--C6 and C6--C7 levels. Cervical facet dislocation usually occurs as a result of combined flexion and distraction forces. [6].

Injury in this zone ranges from ligamentous insufficiency to unstable fracture, involving both posterior and anterior structures in the spinal column. This segment of the spine is highly vulnerable to injury as it is greatly mobile and at the proximal end it carries the weight of the head (12--15 pounds). Moreover, it has to bear great amount of force in acceleration and deceleration injuries [7].

Fracture dislocation of the cervical spine is a devastating injury and there is high probability of neurological deficit. The patient might have simple root injuries, as was in our case (C5, C6, and C7 root injuries), to a devastating complete neurological dysfunction (quadriplegia) [8].

In upper cervical spine, vertebral canal size is greater and hence neurological deficit less commonly happens. Whenever there is neural injury at that level, the patient is usually not compatible with independent life as there would be paralysis of phrenic nerves and subsequent respiratory apnea ensues [9].

In contrast, in sub-axial cervical spine, the size of the canal decreases and any dislocation has a great potential to cause severe cord injury with quadriplegia.

In our case, despite being spondyloptotic displacement at the C5 and C6 level, there were only root injuries in the right side. The spinal cord injury was not there, and hence, rest of the limbs were unaffected with preservation of

patient's ambulatory status. It was theorized that on account of the floating lateral mass in the one side and pedicle fracture in the other side, the posterior elements were separated from the vertebral body in anterior side and hence even after great displacement of the proximal vertebral body, the size of vertebral canal was paradoxically increased. The increased canal saved the patient from a major spinal cord injury.

Like any other dislocation, this injury also has to be treated with reduction (closed or open) and stabilization. There is no consensus as to conservatively manage or one should do operative stabilization of the injury. But However, scientific community is favoring operative early stabilization and rehabilitation of the patients as there are complications of chronic bed recumbencies. In our case, we could do the surgery within 48 hours of the injury and reduction was easy. Complete reduction, cord decompression, and rigid stabilization with the early start of the rehabilitation greatly helped the patient to achieve full neurological recovery without complications. This type of injury demands

diligent patient management with focus on preservation of neurological function as reduction and operative process itself is fraught with complications.

Conclusion

Subaxial cervical spine (C3-7) injuries are among the most common and devastating axial skeleton injuries associated with polytrauma patients. These patients presents to the emergency department with varying degree of neurological compromise. Management varies from conservative to surgical intervention in the form of reduction and stabilization. Early surgical intervention results in near complete neurological recovery.

Clinical Message

Early surgical intervention and stabilization is the key for neurological recovery in patients of traumatic spondyloptosis of cervical spine with neurological compromise.

Declaration of patient consent: The authors certify that they have obtained all appropriate patient consent forms. In the form, the patient has given the consent for his/ her images and other clinical information to be reported in the journal. The patient understands that his/ her names and initials will not be published and due efforts will be made to conceal their identity, but anonymity cannot be guaranteed.

Conflict of interest: Nil **Source of support:** None

References

1. Beyer CA, Cabanela ME, Berquist TH. Unilateral facet dislocations and fracture-dislocations of the cervical spine. *J Bone Joint Surg Br* 1991;73B:977-81.
2. Lee AS, MacLean JC, Newton DA. Rapid traction for reduction of cervical spine dislocations. *J Bone Joint Surg Br* 1994;76B:352-6.
3. Beyer CA, Cabanela ME. Unilateral facet dislocations and fracture-dislocations of the cervical spine: A review. *Orthopedics* 1992;15:311-5.
4. Fehlings MG, Sekhon LH, Tator C. The role and timing of decompression in acute spinal cord injury: What do we know? What should we do? *Spine (Phila Pa 1976)* 2001;26 24 Suppl:S101-10.
5. Allred CD, Sledge JB. Irreducible dislocations of the cervical spine with a prolapsed disc: Preliminary results from a treatment technique. *Spine (Phila Pa 1976)* 2001;26:1927-30; discussion 1931.
6. Zaveri G, Das G. Management of sub-axial cervical spine injuries. *Indian J Orthop* 2017;51:633-52.
7. Shafafy R, Valsamis EM, Luck J, Dimock R, Rampersad S, Kieffer W, et al. Predictors of mortality in the elderly patient with a fracture of the odontoid process. *Bone Joint J* 2019;101-B:253-9.
8. Rief M, Zoidl P, Zajic P, Heschl S, Orlob S, Silbernagel G, et al. Atlanto-occipital dislocation in a patient presenting with out-of-hospital cardiac arrest: A case report and literature review. *J Med Case Rep* 2019;13:44.
9. Clark CR, White AA 3rd. Fractures of the dens. A multicenter study. *J Bone Joint Surg Am* 1985;67:1340-8.

Conflict of Interest: Nil
Source of Support: Nil

Consent: The authors confirm that informed consent was obtained from the patient for publication of this case report

How to Cite this Article

Barwar N, Kumar N, Kumar R, Sharma A, Choudhary MC. Spondyloptosis at Sub axial Cervical Spine with Minimal Neurological Compromise and Complete Recovery: A Rare Case Report. *Journal of Orthopaedic Case Reports* 2022 December; 12(12):118-121.

