

Neglected Anterior Dislocation of Hip Managed with Total Hip Arthroplasty Using Dual Approach: A Case Report and Review of Literature

Dipun Mishra¹, Mantu Jain¹, Sujit Kumar Tripathy¹, Amit Kumar Singh¹, Avnish Kumar Singh¹

Learning Point of the Article:

Neglected anterior dislocation of the hip is a rare finding that may require total hip arthroplasty when the joint is not salvageable although hip arthrodesis and Girdlestone resection can be alternative treatment.

Abstract

Introduction: Traumatic hip dislocations frequently result from road traffic accidents and are prevalent in developing nations. Untreated dislocations either due to ignorance or lack of proper treatment become more challenging to manage and have an increased likelihood of developing avascular necrosis (AVN). Over time, closed methods of reduction become impractical, and if the waiting period surpasses 3 months, open reduction likewise becomes unworkable. Anterior dislocations are less common than posterior dislocations, accounting for a frequency of 7–13% of all hip dislocations. Neglected anterior hip dislocations are extremely rare, and therefore, there is a paucity of information about the management of these dislocations and associated injuries. The available treatment options for these particular situations are total hip arthroplasty (THA), Girdlestone surgery, or hip arthrodesis.

Case Report: We describe the case of a 49-year-old male who presented to our hospital with a neglected anterior dislocation of the hip. The patient disclosed a history of hip trauma 8 months ago, initially receiving conservative management. However, due to persistent pain and functional limitations, he sought further medical attention. A physical examination, radiographic evaluation, and computed tomography (CT) scan confirmed the diagnosis. The patient underwent THA using dual anterior and posterior approaches, followed by a comprehensive rehabilitation program.

Conclusion: Anterior dislocation of the hip is a relatively rare condition, and its neglected presentation is even rarer. This case highlights the importance of prompt diagnosis and early intervention in neglected anterior hip dislocations to minimize complications and optimize patient outcomes.

Keywords: Neglected, Anterior dislocation, Total hip arthroplasty

Introduction

Traumatic hip dislocations are often caused by road traffic accidents (high-energy trauma) and are common in developing countries [1]. Researchers describe the golden period for reduction as occurring within 6 h of injury to prevent future

complications [2]. However, these traumas often coexist with multiple injuries, which divert attention from the dislocation. Neglecting such injuries increases their difficulty in treatment and increases the risk of developing AVN. Closed reduction techniques become unfeasible as time passes, and if the wait

Access this article online

Website:
www.jocr.co.in

DOI:
<https://doi.org/10.13107/jocr.2024.v14.i08.4678>

Author's Photo Gallery



Dr. Dipun Mishra



Dr. Mantu Jain



Dr. Sujit Kumar Tripathy



Dr. Amit Kumar Singh



Dr. Avnish Kumar Singh

¹Department of Orthopaedics, All India Institute of Medical Sciences, Bhubaneswar, Odisha, India.

Address of Correspondence:

Dr. Mantu Jain,
Department of Orthopaedics, All India Institute of Medical Sciences, Bhubaneswar - 751 019, Odisha, India.
E-mail: montu_jn@yahoo.com

Submitted: 11/05/2024; Review: 24/06/2024; Accepted: July 2024; Published: August 2024

DOI: <https://doi.org/10.13107/jocr.2024.v14.i08.4678>

This is an open access journal, and articles are distributed under the terms of the Creative Commons Attribution-NonCommercial-ShareAlike 4.0 License <https://creativecommons.org/licenses/by-nc-sa/4.0/>, which allows others to remix, tweak, and build upon the work non-commercially, as long as appropriate credit is given and the new creations are licensed under the identical terms

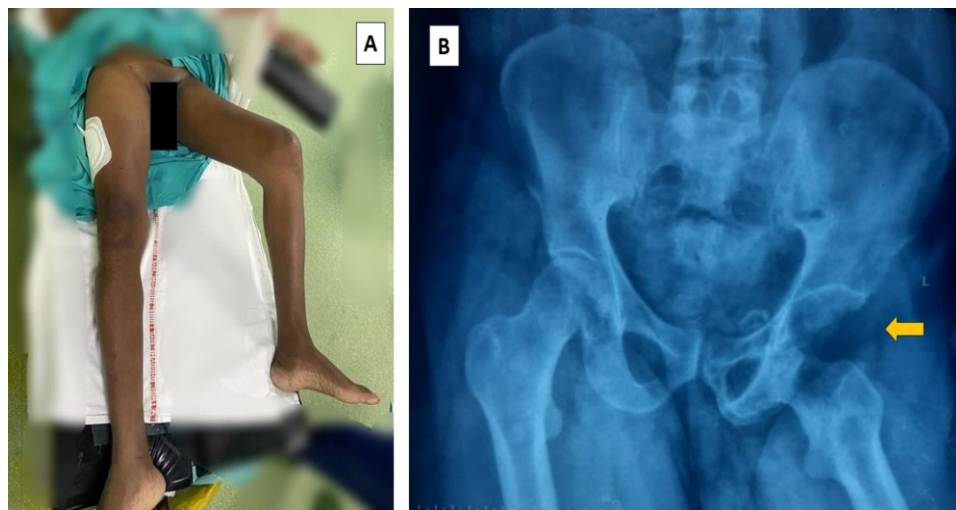


Figure 1: Clinical photo (A) showing the deformity and plain anteroposterior radiograph and (B) showing impacted obturator type anterior dislocation of hip.

only 4% of cases [8]. Neglected anterior-type dislocations are extremely rare and occur in acute settings where immediate orthopedic assistance is unavailable, particularly in rural areas. In developing countries, it is common for patients to seek alternate therapies before eventually arriving at hospitals after a prolonged period of trauma, which poses challenges in managing such cases as time progresses.

Case Report

A 49-year-old male presented to our hospital with complaints of persistent left hip pain and an inability to bear weight on the affected leg. The patient reported a history of trauma to the hip region approximately 5 months ago, following a road traffic accident. Initially, he sought some indigenous treatment and received advice on conservative management, which included pain medication and rest. Despite the initial conservative treatment, the patient continued to experience severe pain and limited mobility. He reported having difficulty walking, standing, and performing routines daily. On physical examination, we found the left lower limb externally rotated and fixed in flexion (Fig. 1a). There was tenderness over the anterior aspect of the hip joint, and any attempt at passive movement caused severe pain.

exceeds 3 months, open reduction also ceases to be viable [1, 3]. The potential options for these types of cases are total hip arthroplasty (THA), Girdlestone procedures, or hip arthrodesis [3, 4]. Trauma-induced hip dislocations fall into different categories based on their direction. Anterior dislocations are significantly less common than posterior dislocations and account for 7%–13% of all hip dislocations [5]. Reports of chronic traumatic anterior hip dislocation are extremely rare, further subdivided into superior (pubic) types and inferior (obturator) varieties, accounting for only 4% [6]. Reports indicate that injuries associated with anterior hip dislocation, such as impaction fractures of the femoral head, occur at frequencies ranging from 15% to 35% [7]. On the other hand, fractures of the acetabulum are less common, occurring in

Radiographic evaluation, including anteroposterior views of

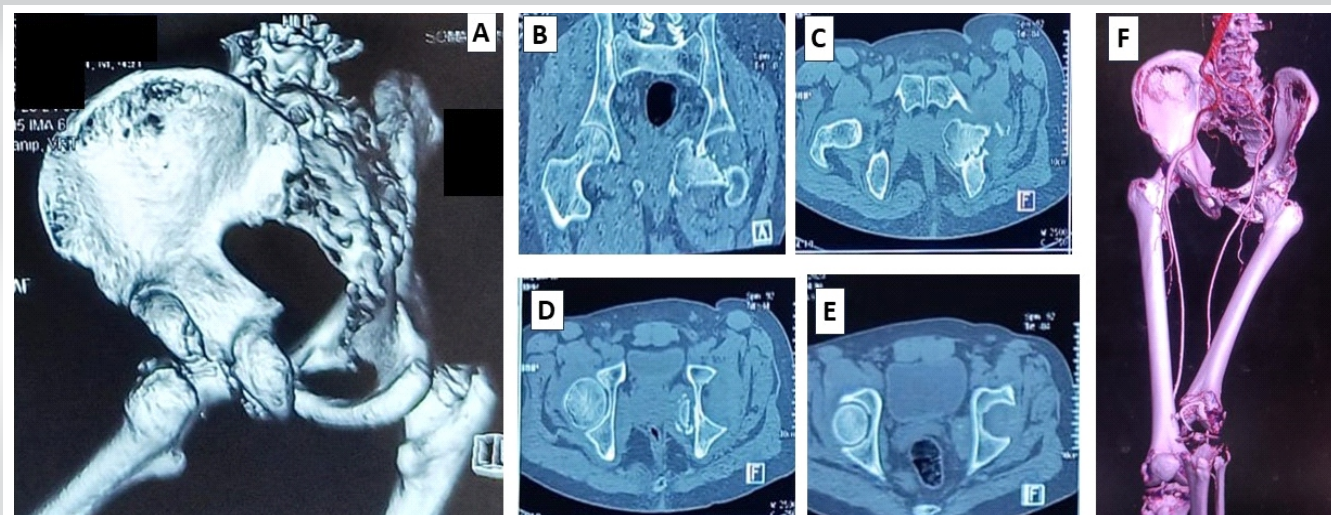


Figure 2: (A) #D reconstruction CT showing an anterior; (B-D) 2D CT showing an impacted obturator type dislocation without wall fracture; (E) the CT angiography displaying the vessels from the planned neck osteotomy site. (F) CT: Computed tomography.

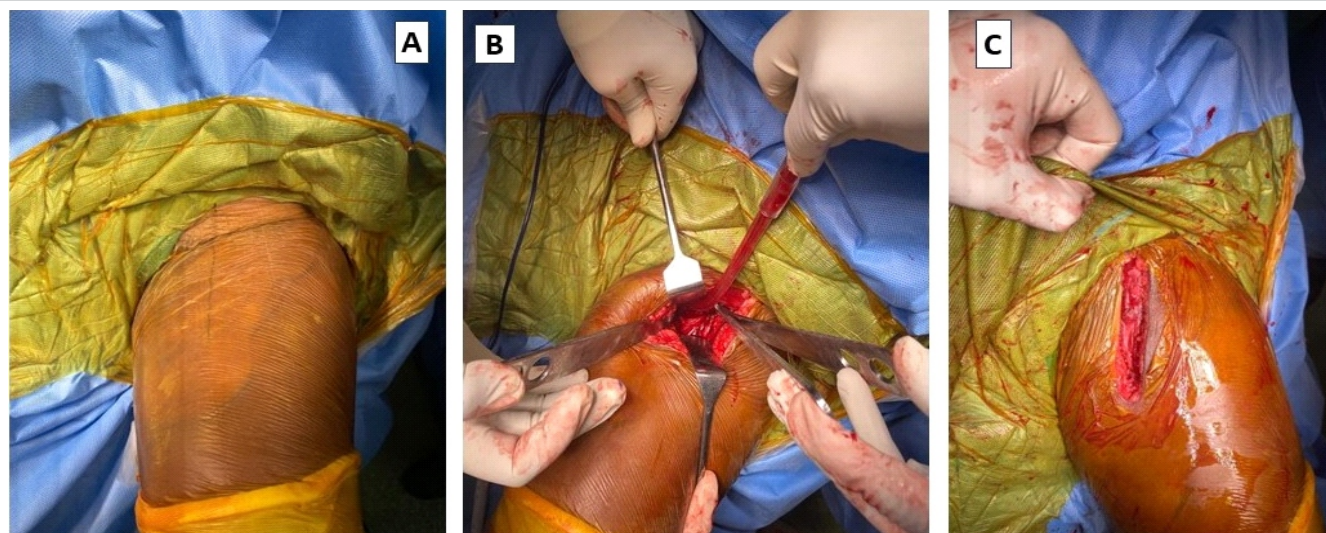


Figure 3: (A-C) Intraoperative picture of osteotomy through the Smith-Petersen approach.

the pelvis, revealed an anterior dislocation of the left hip joint (Fig. 1b). We performed a computed tomography (CT) scan to assess the extent of the bony injury and aid in surgical planning. The CT scan showed that the patient had an anterior hip dislocation of the obturator type, along with inferior acetabular rim fractures (Fig. 2). There was an impaction fracture in the femoral head, as well as a deformity in the femoral head hinging under the inferior acetabular labrum.

After obtaining informed consent, the patient underwent THA of the left hip joint. We used a Smith-Petersen approach in the supine position under spinal anesthesia to access the hip joint (Fig. 3). We exposed the femur's neck and cut it for a hip arthroplasty (Fig. 4). Next, we positioned the patient laterally and initiated the acetabular preparation using the posterior approach. We removed the dense fibrous tissue covering the

acetabulum and surrounding labrum. Next, we proceeded with serial reaming to reveal the bleeding cancellous bone, after which we positioned and secured an acetabulum shell of the appropriate size using three screws. A polyethylene liner was placed and locked. A non-cemented stem was fixed in the femur after serial broaching. The hip joint was reduced, and stability was checked throughout the range of motion and found satisfactory. The wound was thoroughly washed and closed in layers.

The patient was on immobilization with an abduction brace for 2 weeks postoperatively to facilitate the healing of the soft-tissues surrounding the hip joint. After 2 weeks, we removed the sutures and initiated a comprehensive rehabilitation program for the patient, which included range-of-motion exercises and gradual weight-bearing as tolerated. Physical therapy sessions

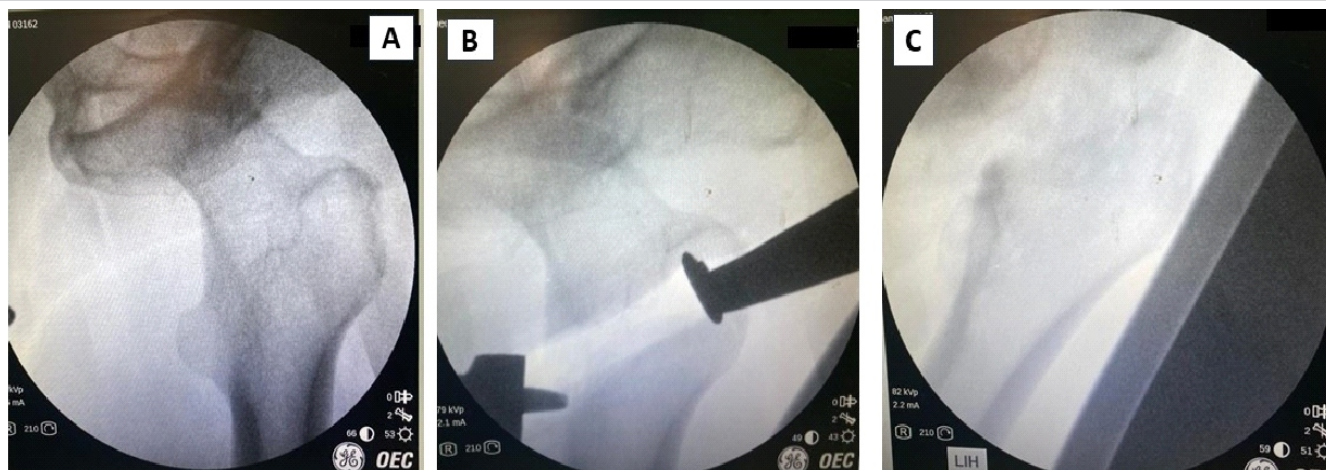


Figure 4: (A) Intraoperative C-arm image of neck, (B) planned neck cut, and [C] after osteotomy.

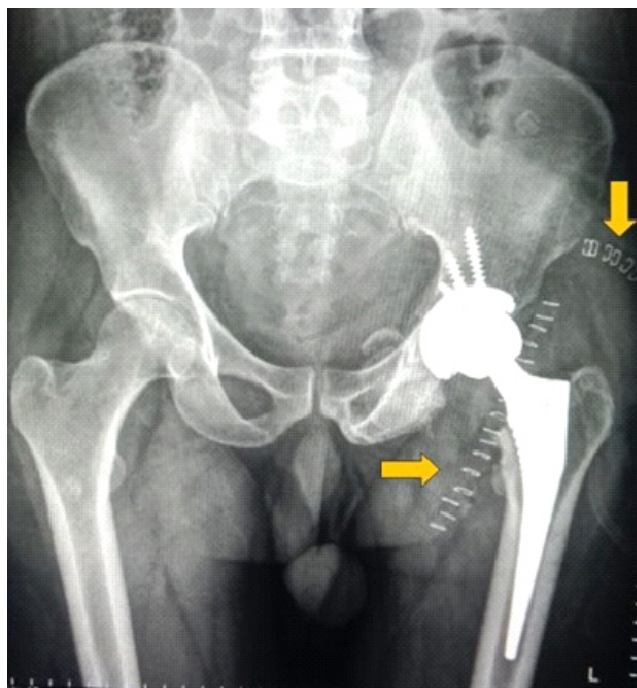


Figure 5: Post-operative radiograph after total hip arthroplasty. Two incisions can be appreciated with two suture lines (yellow arrow).

were conducted to improve muscle strength, joint stability, and functional independence. Post-operative radiograph was satisfactory (Fig. 5).

At the 1-year follow-up, the patient reported significant improvement with good functional outcomes (Harris hip score of 83). The patient regained a near-normal range of motion and was able to walk without support, although with a slight limp.

Discussion

Anterior traumatic hip dislocations are relatively less common than posterior dislocations. Information regarding these dislocations and their associated injuries is scarce. Consequently, there is a limited availability of recommendations regarding the suitable treatment approach for these fractures (operative versus non-operative) [9]. The unreduced obturator variety of anterior hip dislocation is an uncommon occurrence. Early diagnosis can effectively manage the dislocation through closed reduction and immobilization, leading to satisfactory outcomes [10]. However, the surgeon has few options if there is a delay of more than 3 months. The time between injury and reduction strongly influences the occurrence of femoral head necrosis. Failure to perform reduction within 6 h after the injury can lead to a 50% incidence of femoral head necrosis [11]. Researchers have observed impaction defects at varying frequencies, from 15% to 35%, and have linked them to a higher incidence of post-traumatic hip

osteoarthritis [12]. While THA is considered a viable treatment option in such situations, certain authors have mentioned alternative approaches such as subtrochanteric osteotomy, the Girdlestone procedure, hip arthrodesis, or hemiarthroplasty.

Closed reduction has been less commonly used compared to open reduction in cases of dislocations, mainly due to the increased difficulty of achieving reduction. Delays in receiving the appropriate treatment typically influence the success of the reduction process. Pai [13] documented three cases of neglected anterior dislocations, but they did not specify if any of these cases included obturator dislocations. In only one of these cases, closed reduction was successful, with neglect lasting <3 weeks.

The first ever reported case of neglected anterior dislocation of the hip was by Mikhail in 1956, where they used open reduction to manage a 1-year-old dislocation [14]. Although they were able to achieve hip reduction, they did not report any long-term functional results. Seven cases of old obturator dislocations that had not been reduced were studied by Scadden and Dennyson [15], Younge and Lifeso [16], Pathania et al. [17], Albayrak et al. [18], Li et al. [19], Mootha AK et al. [20], and Koshire et al. [21]. All of them were treated with open reduction. Among these patients, three showed substantial improvement and were able to perform routine work without pain. Two patients achieved relatively satisfactory results with a slight limp and some pain; one patient had a poor outcome and required hip fusion; and one patient developed AVN, necessitating THA at a later date. Hamada [22] reported in 1957 that they managed four cases with a simple corrective osteotomy to improve limb functioning. Aggarwal and Singh (1967) documented six anterior obturator dislocations, treating them with trochanteric osteotomy in five cases and open reduction in one [23]. All patients had poor outcomes, including hip flexion deformities and restricted mobility. Young and Banza used Bernese trochanteric flip osteotomy in a 6-week-old neglected anterior dislocation and reported fair outcomes [24]. Nagi et al. [25] documented two cases of unreduced obturator dislocations, in which the patients underwent a modified Girdlestone arthroplasty. To preserve the option of a THA in the future, if necessary, the procedure involved a subcapital osteotomy. Following the surgery, both patients exhibited shortened legs but showed a complete range of motion in rotation and flexion, although with restricted abduction capabilities. In their study, Alva et al. (2013) presented a case of a 5-month-old neglected anterior dislocation of the hip in a 25-year-old man [3]. Pre-operative MRI scanning detected AVN. To address the condition, they opted for a modified Girdlestone procedure following the technique described by Nagi et al. [25]. Over a 3-year period, they assessed the patient's progress and found a

S. No.	References	No. of cases	Year of publication	Age (years)	Delay in treatment (months)	Treatment	Follow-up in (months)	Outcome
1	Mikhail [14]	1	1956	24	12	Open reduction	0.5	Walking with crutches
2	Hamada [22]	3	1957	24	144	Osteotomy of femoral neck	No follow -up	Unknown
				12	12	Osteotomy of femoral neck	No follow -up	Unknown
				9	5	Osteotomy of femoral neck	No follow -up	Unknown
3	Aggarwal and Singh [23]	6	1967	45	12	Trochanteric osteotomy	48	Fixed hip in flexion of 25 °. Back to his original occupation
				55	9	Trochanteric osteotomy	39	Fixed straight hip. Walking with crutches
					5	Trochanteric osteotomy	25	Fixed hip in flexion of 15 °. Walking without support
				22	3	Trochanteric osteotomy	11	Fixed hip in flexion of 20 °. Working as a farmer again
				35	11	Open reduction	11	A painful hip with limited movements
				28	3	Trochanteric osteotomy	10	Fixed hip in flexion of 15 °. Able to do his routine work
4	Scadden and Dennyson [15]	1	1978	16	1	Open reduction	12	Walking with a slight limp but without any pain. No fixed deformities
5	Younge and Lifeso [16]	1	1988	16	72	Open reduction first, and then hip fusion	3	Walking no better than before surgery with recurrent flexion contracture
6	Nagi et al. [25]	2	1992	35	7.5	Modified Girdlestone hip arthroplasty	25	2.5 cm shortening. Full range of flexion and rotations with limited abduction of 20°. Some pain present on prolonged walking
				28	9.5	Modified Girdlestone hip arthroplasty	33	3 cm shortening. Full range of flexion and rotations with limited abduction of 20°. Some pain present on prolonged walking
7	Pai [13]	3	1992	64	<6 weeks	Closed reduction	36	Satisfactory
				35	3 months-1 year	Open reduction	36	Satisfactory
				48	>1 year	Girdlestone arthroplasty	48	Unsatisfactory
8	Pathania et al. [17]	1	1995	16	4	Open reduction	11	Almost full pain -free movement of hip
9	Albayrak et al. [18]	1	2006	5	1.5	Open reduction	12	No complaints and no functional restriction
10	Pankaj et al. [26]	1	2011	33	6	Total hip arthroplasty	18	Walking unsupported without symptom
11	Alva et al. [3]		2013	25	5	Girdlestone arthroplasty	36	Walking independently with shoe raise
12	Mootha and Mogali [20]		2016	9	1.5	Open reduction	12	Perform all activities of daily living without any difficulty
13	Young and Banza [24]		2017	51	1.5	Open reduction with bernese trochanteric flip	7	Walking without crutches, with a normal gait and without pain
14	Singh et al. [27]		2021	45	7	Total hip arthroplasty with proximal femoral reconstruction	24	Painless and mobile hip joint
15	Koshire et al. [21]		2021	35	6	Open reduction and fixation with Steinman pins	3	ambulatory with stick support with no deformity, no pain and with early radiological features of avascular necrosis

Table 1: Review of literature.

“fairly stable hip” with only 2.5 cm of shortening [3]. Pankaj et al. managed a 33-year-old male patient with an unreduced obturator dislocated hip, who had experienced a deformity in his right hip due to a road traffic accident 6 months earlier, by THA [26]. Singh et al. [27] conducted a study where they reported a 45-year-old male patient who had an anterior hip dislocation and a petrochanteric femoral fracture, both of which had gone untreated for 7 months. The management involved THA and proximal femoral reconstruction. After a follow-up period of 2 years, the hip joint became painless and mobile, indicating the success of the procedure.

Anterior hip dislocations are associated with other hip injuries such as femoral head impaction fractures or acetabulum

fractures, which can contribute to the development of post-traumatic hip osteoarthritis. The dislocation event may compress the femoral head against the anterior acetabular rim, leading to impaction defects within the femoral head or an avulsion or fracture of the anterior acetabular rim or wall. Studies have particularly reported severe osteoarthritic changes and unfavorable clinical outcomes in patients with impaction fractures deeper than 4 mm [28]. Tehranzadeh et al. [29] investigated the osteochondral impaction of the femoral head in dislocations using CT scans on a group of 35 patients. The study revealed that 67% of posterior dislocations and 100% of anterior dislocations showed femoral head impaction. In cases of anterior dislocation, the femoral head impaction occurred in the posterosuperior and lateral regions of the femoral head. This

impaction bears a resemblance to Hillsach's shoulder lesion. In addition, Dussault et al. [30] observed that contact against the anteroinferior margin of the acetabular rim caused the impaction of the femoral head in obturator dislocations. Table 1 provides the details of the literature review.

Patients with good outcomes had a relatively short neglect time, lasting up to 6 months. On the other hand, those with fair or poor outcomes had considerably longer neglect times. This is consistent with other studies' findings, which emphasize the critical role of neglect time as a prognostic factor in these cases. When the neglect extends beyond 3 months, as was the case in our situation with approximately 6 months of neglect, open reduction becomes a challenging option. Since our patient was middle age, wanted a painless, mobile, and stable hip, and there were no economic constraints, we decided to go for THA. In our case, the impaction involved the entire superolateral half of the femoral head, indicating that the inferior margin of the acetabulum was the cause of the impingement. The femoral head was hinging under the inferior acetabular labrum, and we expected difficulty in dislocating the hip joint. Therefore, we decided to use the anterior Smith-Petersen approach to open the hip joint and perform a neck cut. We decided to leave the head in its original position because the neck lodged very close to the femoral vessels. We, then, performed THA using the posterior approach.

Declaration of patient consent: The authors certify that they have obtained all appropriate patient consent forms. In the form, the patient has given the consent for his/ her images and other clinical information to be reported in the journal. The patient understands that his/ her names and initials will not be published and due efforts will be made to conceal their identity, but anonymity cannot be guaranteed.

Conflict of interest: Nil **Source of support:** None

Conclusion

The approach to treating delayed, unreduced anterior obturator dislocation has been somewhat empirical, but no definitively superior method has been proven. However, in the case of our patient, we highly recommend THA based on the increased risk of further complications, such as AVN, particularly in conjunction with an indentation fracture of the femoral head. THA is considered a suitable option to address these issues and improve the patient's overall outcome. While THA is a favorable option in current medical practice, previously described treatment methods such as trochanteric osteotomy and the modified Girdlestone procedure remain relevant in situations where access to expert medical care may be limited. In addition, these methods may be considered when dealing with sedentary patients who choose to undergo THA at a later time.

Clinical Message

A neglected anterior dislocation of the hip is a rare presentation. One can attempt an open reduction before the onset of AVN in the early period. However, neglect for longer periods and those associated with head or acetabular fractures warrant further procedures such as Girdlestone arthroplasty, arthrodesis, or THA.

References

1. Kumar S, Dahuja A, Narula MS, Garg S, Kaur R. Neglected hip dislocation: An unusual presentation, its management and review of the literature. *Strategies Trauma Limb Reconstr* 2017;12:189-92.
2. Jain M, Swaroop S, Doki SK. Neglected posterior hip dislocation in adults presenting after one year managed successfully with single stage total hip arthroplasty: A case series. *J Orthop Case Rep* 2021;11:84-8.
3. Alva A, Shetty M, Kumar V. Old unreduced traumatic anterior dislocation of the hip. *BMJ Case Rep* 2013;2013:bcr2012008068.
4. Garrett JC, Epstein HC, Harris WH, Harvey JP Jr, Nickel VL. Treatment of unreduced traumatic posterior dislocations of the hip. *J Bone Joint Surg Am* 1979;61:2-6.
5. El Masry AM. Anterior hip dislocation with ipsilateral displaced fracture neck of femur treated by open reduction and internal fixation: Case report and review of the literature. *Strategies Trauma Limb Reconstr* 2017;12:205-10.
6. Hani R, Kharmaz M, Berrada MS. Traumatic obturator dislocation of the hip joint: A case report and review of the literature. *Pan Afr Med J* 2015;21:55.
7. Erb RE, Steele JR, Nance EP Jr, Edwards JR. Traumatic anterior dislocation of the hip: Spectrum of plain film and CT findings. *AJR Am J Roentgenol* 1995;165:1215-9.
8. Epstein HC, Harvey JP Jr. Traumatic anterior dislocation of the hip, management and results - An analysis of fifty-five cases. *J Bone Joint Surg Am* 1972;43-A:1561-2.
9. Sahin V, Karakas ES, Aksu S, Atlihan D, Turk CY, Halici M.



- Traumatic dislocation and fracture-dislocation of the hip: A long-term follow-up study. *J Trauma* 2003;54:520-9.
10. Gokulprasath S, Tarun Prashanth K. Anterior hip dislocation with ipsilateral subtrochanteric femur fracture in a young adult - a rare case report. *J Orthop Case Rep* 2020;10:63-6.
 11. Tekin AÇ, Çabuk H, Büyükkurt CD, Dedeoğlu SS, İmren Y, Gürbüz H. Inferior hip dislocation after falling from height: A case report. *Int J Surg Case Rep* 2016;22:62-5.
 12. Epstein HC. Traumatic dislocations of the hip. *Clin Orthop Relat Res* 1973;92:116-42.
 13. Pai VS. The management of unreduced traumatic dislocation of the hip in developing countries. *Int Orthop* 1992;16:136-9.
 14. Mikhail IK. Unreduced traumatic dislocation of the hip. *J Bone Joint Surg Br* 1956;38-B:899-901.
 15. Scadden WJ, Dennyson WG. Unreduced obturator dislocation of the hip. A case report. *S Afr Med J* 1978;53:601-2.
 16. Younge D, Lifeso R. Unreduced anterior dislocation of the hip in a child. *J Pediatr Orthop* 1988;8:478-80.
 17. Pathania VP, Kumar A, Ghosh D. Unreduced anterior dislocation of the hip: A case report. *Med J Armed Forces India* 1995;51:72-3.
 18. Albayrak M, Doğan A, Sürel YB. Traumatic obturator hip dislocation in a five-year-old boy: Open reduction after a six-week delay in diagnosis. *Acta Orthop Traumatol Turc* 2006;40:260-3.
 19. Li WZ, Wang JJ, Ni JD, Song DY, Ding ML, Huang J, et al. Old unreduced obturator dislocation of the hip: A case report. *World J Clin Cases* 2021;9:3979-87.
 20. Mootha AK, Mogali KV. A rare case of neglected traumatic anterior dislocation of hip in a child. *J Orthop Case Rep* 2016;6:40-2.
 21. Koshire SR, Koshire RR, Jain S. A 6-month-old neglected obturator inferior variety of anterior hip dislocation in a young male managed with an intermediary salvage measure without the need for osteotomy or excision arthroplasty with a resultant ambulatory natural hip a case report. *J Orthop Case Rep* 2021;11:57-60.
 22. Hamada G. Unreduced anterior dislocation of the hip. *J Bone Joint Surg Br* 1957;39-B:471-6.
 23. Aggarwal ND, Singh H. Unreduced anterior dislocation of the hip. Report of seven cases. *J Bone Joint Surg Br* 1967;49:288-92.
 24. Young S, Banza L. Neglected traumatic anterior dislocation of the hip. Open reduction using the Bernese trochanter flip approach - a case report. *Acta Orthop* 2017;88:348-50.
 25. Nagi ON, Dhillon MS, Gill SS. Chronically unreduced traumatic anterior dislocation of the hip: A report of four cases. *J Orthop Trauma* 1992;6:433-6.
 26. Pankaj A, Sharma M, Kochar V, Naik VA. Neglected, locked, obturator type of inferior hip dislocation treated by total hip arthroplasty. *Arch Orthop Trauma Surg* 2011;131:443-6.
 27. Singh A, Kumar P, Singh S, Singh RN, Telagareddy K. Primary complex total hip arthroplasty in neglected anterior hip dislocation with comminuted pertrochanteric femur fracture. *Arthroplast Today* 2021;10:63-7.
 28. DeLee JC, Evans JA, Thomas J. Anterior dislocation of the hip and associated femoral-head fractures. *J Bone Joint Surg Am* 1980;62:960-4.
 29. Tehranzadeh J, Vanarthos W, Pais MJ. Osteochondral impaction of the femoral head associated with hip dislocation: CT study in 35 patients. *AJR Am J Roentgenol* 1990;155:1049-52.
 30. Dussault RG, Beauregard G, Fauteaux P, Laurin C, Boisjoly A. Femoral head defect following anterior hip dislocation. *Radiology* 1980;135:627-9.

Conflict of Interest: Nil
Source of Support: Nil

Consent: The authors confirm that informed consent was obtained from the patient for publication of this case report

How to Cite this Article

Mishra D, Jain M, Tripathy SK, Singh AK, Kumar A. Neglected Anterior Dislocation of Hip Managed with Total Hip Arthroplasty Using Dual Approach: A Case Report and Review of Literature. *Journal of Orthopaedic Case Reports* 2024 August;14(8): 141-147.