

# Distal Phalangeal Physeal Closure Preceding Ossification of the Thumb Adductor Sesamoid: A Case Report

Shane Ross<sup>1</sup>, Sarah Lu<sup>1</sup>, Samuel Beber<sup>1</sup>, Katherine Groff<sup>1</sup>, Diego Jaramillo<sup>1</sup>, Shevaun Doyle<sup>1</sup>

## Learning Point of the Article:

Thumb adductor sesamoid ossification may be absent despite distal phalangeal physeal closure in patients with growth hormone deficiency, underscoring the need for cautious interpretation of simplified bone age assessment methods.

## Abstract

**Introduction:** Assessment of skeletal maturity is fundamental to pediatric orthopedic practice, as remaining growth potential influences prognosis and treatment decisions. Ossification of the thumb adductor sesamoid is widely used as a pubertal landmark and is expected to precede distal phalangeal physeal closure in established bone age assessment methods. Deviation from this sequence is rarely described. We report a case of distal phalangeal physeal closure occurring in the absence of thumb adductor sesamoid ossification in a patient with growth hormone deficiency.

**Case Report:** A 15-year-old female with hypopituitarism and growth hormone deficiency was followed for adolescent idiopathic scoliosis. Despite long-term recombinant growth hormone therapy, she demonstrated delayed pubertal progression. A posteroanterior radiograph of the left hand and wrist obtained to assess skeletal maturity revealed complete distal phalangeal physeal closure across all digits without ossification of the thumb adductor sesamoid. The contralateral hand demonstrated early sesamoid ossification. At a chronological age of 15 years and 4 months, bone age was estimated at 13 years and 6 months, consistent with delayed skeletal maturation. This represents a discordant and atypical sequence of ossification.

**Conclusion:** This case demonstrates that thumb adductor sesamoid ossification may be absent despite distal phalangeal physeal closure in patients with endocrine dysfunction. Simplified skeletal maturity assessment methods that rely on sesamoid appearance may therefore be misleading in this population. Careful evaluation of the overall pattern of physeal development is essential when managing growth-dependent orthopedic conditions. This report highlights clinically relevant variability in skeletal maturation in the setting of growth hormone deficiency.

**Keywords:** Skeletal maturity, thumb adductor sesamoid, distal phalangeal physis, growth hormone deficiency, bone age assessment.

## Introduction

Assessment of skeletal maturity is fundamental to pediatric orthopedic practice, as a patient's remaining growth significantly influences prognosis and management across a wide range of conditions, particularly when planning surgeries about the knee [1]. Hand and wrist radiographs are commonly used to evaluate

skeletal age, as the appearance and fusion of secondary ossification centers and the closure of physes follow a predictable sequence during childhood and adolescence in the hand [2]. The most commonly used assessment of bone age is the Greulich and Pyle Method (GPM), introduced in the Radiographic Atlas of the Hand and Wrist, which remains the gold standard among

Access this article online

Website:  
www.jocr.co.in

DOI:  
<https://doi.org/10.13107/jocr.2026.v16.i07.7622>

## Author's Photo Gallery



Mr. Shane Ross



Miss. Sarah Lu



Mr. Samuel Beber



Miss. Katherine Groff



Dr. Diego Jaramillo



Dr. Shevaun Doyle

<sup>1</sup>Hospital for Special Surgery, 535 E 70th Street, New York, NY 10021, United States.

### Address of Correspondence:

Dr. Shevaun Doyle,  
Hospital for Special Surgery, 535 E 70th Street, New York, NY 10021, United States. Phone: 646-797-8816.  
E-mail: [doyles@hss.edu](mailto:doyles@hss.edu)

Submitted: 30/04/2026; Review: 25/05/2026; Accepted: June 2026; Published: July 2026

DOI: <https://doi.org/10.13107/jocr.2026.v16.i07.7622>

© The Author(s). 2026 Open Access. This article is distributed under the terms of the Creative Commons Attribution 4.0 International License (<https://creativecommons.org/licenses/by-nc/4.0/>), which permits unrestricted use, distribution, and non-commercial reproduction in any medium, provided you give appropriate credit to the original author(s) and the source, provide a link to the Creative Commons license, and indicate if changes were made. The Creative Commons Public Domain Dedication waiver (<http://creativecommons.org/publicdomain/zero/1.0/>) applies to the data made available in this article, unless otherwise stated.

orthopedic surgeons. More recent methods, such as the Shorthand Bone Age (SBA) assessment, are derived from the GPM but offer a simplified approach [3]. In normal skeletal development, the final ossification center to appear in the hand is the adductor sesamoid of the thumb. In the SBA, the thumb sesamoid typically ossifies and becomes visible on radiographs at approximately 11 years in females and 13 years in males, preceding physeal closure of the thumb and index finger distal phalanges. Closure of the thumb distal phalanx occurs at approximately 13 years in females and 15 years in males, followed by closure of the index finger distal phalanx at approximately 13.5 and 15.5 years, respectively. This sequence is also consistent with skeletal maturation patterns described by the GPM [4, 5].

Few cases in the literature describe deviation from this expected temporal sequence of ossification and physeal closure. We report the case of a 15-year-old female patient with a history of hypopituitarism and delayed puberty on growth hormone (GH) therapy, who demonstrated closure of the thumb distal phalangeal physis in the absence of thumb sesamoid ossification.

### Case Report

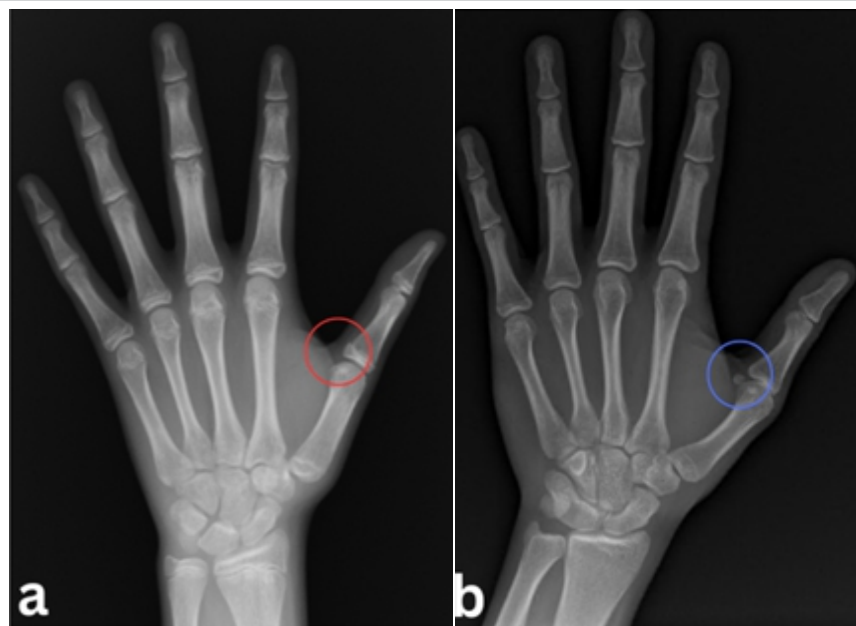
A 10-year-old female was referred to pediatric endocrinology for evaluation of pathologic short stature when her pediatrician

noticed a declining growth trajectory. Her medical history was significant for isolated premature thelarche diagnosed at 10 months of age, characterized by bilateral breast development with a Tanner stage 3 appearance in the absence of other pre-pubertal features. There was no known family history of early epiphyseal closure or abnormalities of skeletal maturation. Further laboratory evaluation demonstrated decreased insulin-like growth factor (IGF-1), GH, thyroid hormone, T4, and T3 levels. Magnetic resonance imaging revealed a small-volume pituitary gland, consistent with pituitary hypoplasia. These findings supported a diagnosis of hypopituitarism with associated growth hormone deficiency. Given her short stature and the presence of open physes with evidence of remaining growth potential, confirmed on hand radiography, treatment with recombinant human growth hormone (somatotropin) was initiated.

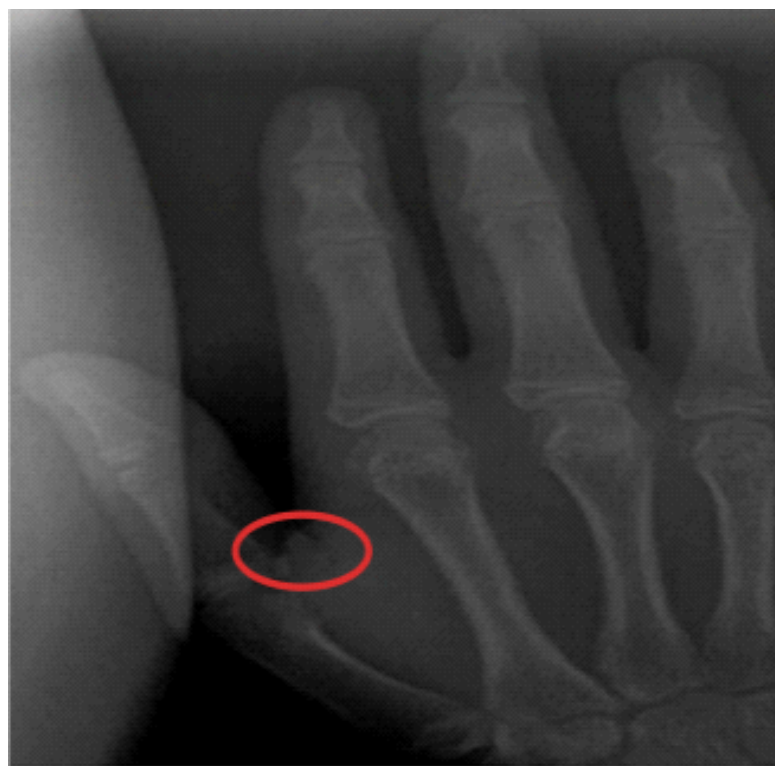At 11 years of age, the patient presented to the orthopedic surgery clinic for evaluation of scoliosis following observation of shoulder asymmetry on the Adams forward bend test at a routine pediatric visit. Plain radiographic evaluation demonstrated a left T3–T12 curve measuring 12° and a right T12–L4 curve measuring 14°, consistent with a diagnosis of adolescent idiopathic scoliosis (IS). Serial standing pelvic radiographs showed persistent Risser stage 0, with absent iliac apophyseal ossification findings, which indicate substantial

remaining growth potential. Throughout orthopedic follow-up, the patient exhibited persistent delayed pubertal progression, while physical examinations remained unremarkable, with no dysmorphic features or neurologic abnormalities. As part of routine scoliosis management to assess skeletal maturity and remaining growth potential, particularly in the context of persistent Risser stage 0 and premenarchal status, a hand and wrist radiograph was obtained at 15 years of age.

A posteroanterior radiograph of the left hand and wrist demonstrated complete fusion of the distal phalangeal physes across all digits, along with absence of ossification of the thumb adductor sesamoid (Fig. 1a). In contrast, the right hand showed early ossification of the thumb sesamoid (Fig. 2). At a chronological age of 15 years and 4 months, bone age was estimated at 13 years and 6 months according to the Greulich and Pyle atlas, consistent with delayed skeletal maturation. The absence of sesamoid ossification despite closure of the distal phalangeal physes represents a notable



**Figure 1:** Absence of thumb adductor sesamoid ossification in the patient's left hand compared with reference radiograph. Anteroposterior radiographs of the left hand and wrist, (a) Radiograph of the patient obtained at 15 years and 4 months of age demonstrating absence of thumb adductor sesamoid ossification at the first metacarpophalangeal joint (red circle). Skeletal age was estimated at 13 years and 6 months using the Greulich and Pyle atlas, (b) Anteroposterior radiograph of a reference pediatric left hand demonstrating the presence of the thumb adductor sesamoid (blue circle). Image (b) adapted from Montgomery, Understanding Growth: The role of hand X-rays in Scoliosis Care. Washington University Pediatric Spinal Deformity Blog, 2024 [6].



**Figure 2:** Anteroposterior radiograph demonstrating expected thumb adductor sesamoid ossification. Anteroposterior radiograph of the patient's right hand obtained at 15 years and 4 months of age on the same date as the left hand radiograph was taken. An ossific nucleus of the thumb adductor sesamoid is present at the first metacarpophalangeal joint (circled). The distal phalangeal physes are fused. This radiograph demonstrates the expected appearance of sesamoid ossification at this stage of skeletal maturation.

deviation from the expected, consistent maturation sequence outlined in the GPM (Fig. 1b). The patient was treated with a thoracolumbosacral orthosis nocturnal back brace, and had correction of her scoliosis over the course of 2 years.

### Discussion

In this case report, we describe an adolescent patient with an aberrant sequence of hand ossification, characterized by distal phalangeal physal closure and the absence of thumb adductor sesamoid ossification. The appearance of the adductor sesamoid and physal closure of the distal phalanx of the thumb are widely regarded as the two major landmarks in evaluating skeletal maturity during puberty and early adolescence. The sequence of hand and wrist ossification is well characterized and predictable, with the progressive appearance and fusion of multiple ossification centers that form the basis of established bone age assessment methods [7].

Accurate assessment of skeletal maturity is critical for guiding management of adolescent IS and predicting the risk of curve progression. Sanders et al. demonstrated that metacarpal and phalangeal development, specifically, in the Tanner-

Whitehouse method, was highly correlated with curve progression in prepubescent females with IS amongst skeletal maturity parameters [8]. In maxillofacial surgery, ossification of the thumb adductor sesamoid has been extensively utilized as a marker of pubertal onset to guide the timing of growth-dependent surgical decision making [9,10]. Previously, Hung et al. proposed the Thumb Ossification Composite Index (TOCI) as a simplified staging system for assessing skeletal maturity in patients with IS [11]. The components of the TOCI include the adductor sesamoid bone, distal phalanges of the thumb, and the lateral corner of proximal phalangeal epiphyses of the thumb to stage skeletal development. This highlights the clinical importance of individual hand ossification centers, particularly the thumb adductor sesamoid and the proximal and distal phalangeal physes, as key indicators in the assessment of skeletal maturation.

The patient's endocrinologic history of hypopituitarism provides important context for her atypical ossification pattern. Though many hormonal signals are involved in physal maturation, including GH, IGF, thyroid hormone, estrogen, and androgens, estrogen primarily regulates physal closure [12,13,14,15]. Sesamoid ossification involves Type II collagen and proteoglycans, which contribute to mineral deposition and ossification. Their growth is

regulated by transforming growth factor beta and bone morphogenetic protein-2. Mechanical factors, such as shear forces and stress, can contribute to sesamoid ossification. Previous literature demonstrates that while skeletal maturity might be delayed in those with GH deficiency, bone age can be within the normal range or accelerated after patients begin GH supplementation [16,17,18,19]. Bone age progression rate is also affected by sex, GH dose, duration of GH treatment, and pubertal status. Kang et al. investigated bone age progression in 78 patients with idiopathic GH deficiency during the first 3 years of recombinant GH therapy [20]. The authors found that GH treatment was associated with accelerated skeletal maturation, with bone age advancing at a rate of approximately 1.28 years for every 1 year of chronological age. However, in the present case, the patient had been receiving GH therapy for nearly 10 years and nevertheless demonstrated absent thumb sesamoid ossification, highlighting an atypical pattern of skeletal development despite long-term treatment. Due to the complex interactions of the hypothalamic-pituitary-adrenal axis and sex hormones (estrogens and androgens) on physal maturation, it is difficult to determine whether GH alone contributed to the absence of sesamoid ossification in this

patient. One plausible explanation suggested by Cho et al. is that GH therapy may have preferentially accelerated linear growth, while persistent deficiency of sex steroids (particularly estrogen) selectively delayed ossification of the smaller sesamoid center [21].

Furthermore, this patient demonstrated asymmetric development, as the right hand showed early sesamoid ossification while the left remained unossified. This case highlights the intricate relationship between growth hormone therapy and skeletal maturation, which remains important to understand when managing adolescent IS. As simplified and shorthand methods of skeletal age assessment based on hand radiographs become increasingly common, clinicians must remain attentive to potential variation in metacarpal and sesamoid development [22]. This is especially true in patients with underlying endocrine disorders. With the growing use of GH therapy, awareness of both focal and global abnormalities in skeletal maturation is essential. In summary, we report an unusual case of discordant hand ossification patterns in the setting of IS and GH deficiency.

### Conclusion

We present the case of a patient with a medical history of hypopituitarism who was followed in the orthopedic clinic for

adolescent IS and was found to have absent ossification of the thumb adductor sesamoid despite distal phalangeal physal closure, an uncommon and discordant finding. To the best of our knowledge, this represents the first reported case describing this atypical sequence of skeletal maturation in the setting of prolonged growth hormone therapy. In patients with a phalangeal–sesamoid discrepancy, physicians should rely more heavily on patterns of physal closure rather than isolated ossification landmarks when assessing skeletal maturity. In pediatric growth assessment, particularly in patients monitored for orthopedic conditions such as scoliosis, this case illustrates that the sequence of ossification events may be as clinically informative as their timing. Careful attention to deviations from expected maturation patterns may therefore provide important diagnostic insight and influence growth-dependent clinical decision-making in both orthopedic and endocrine practice.

### Clinical Message

In patients with endocrine dysfunction, particularly those receiving growth hormone therapy, the sequence of hand ossification may not follow established norms. Distal phalangeal physal closure can precede thumb adductor sesamoid ossification. Skeletal maturity assessment should therefore prioritize comprehensive physal evaluation rather than isolated ossification landmarks.

**Declaration of patient consent:** The authors certify that they have obtained all appropriate patient consent forms. In the form, the patient has given the consent for his/ her images and other clinical information to be reported in the journal. The patient understands that his/ her names and initials will not be published and due efforts will be made to conceal their identity, but anonymity cannot be guaranteed.

**Conflict of interest:** Nil **Source of support:** None

### References

1. Fabricant PD, Bram JT. Methods of assessing skeletal maturity when planning surgeries about the knee. *J Am Acad Orthop Surg* 2025;33:457-66.
2. Creo AL, Schwenk WF 2nd. Bone age: A handy tool for pediatric providers. *Pediatrics* 2017;140:e20171486.
3. Heyworth BE, Osei DA, Fabricant PD, Schneider R, Doyle SM, Green DW, et al. The shorthand bone age assessment: A simpler alternative to current methods. *J Pediatr Orthop* 2013;33:569-74.
4. Greulich WW, Pyle SI. *Radiographic Atlas of Skeletal Development of the Hand and wrist*. 2nd ed. Stanford: Stanford University Press; 1959.
5. Gilsanz V, Ratib O. *Hand Bone Age: A Digital Atlas of Skeletal Maturity*. Berlin: Springer-Verlag; 2005.
6. Montgomery. *Understanding Growth: The Role of Hand X-Rays in Scoliosis Care*. Washington University Pediatric Spinal Deformity Blog; 2024. Available from: <https://sites.wustl.edu/pediatricspinaldeformity/understanding-growth-the-role-of-hand-x-rays-in-scoliosis-care> [last accessed 15 Mar 2024].
7. Satoh M. Bone age: Assessment methods and clinical applications. *Clin Pediatr Endocrinol* 2015;24:143-52.
8. Sanders JO, Browne RH, McConnell SJ, Margraf SA, Cooney TE, Finegold DN. Maturity assessment and curve progression in girls with idiopathic scoliosis. *J Bone Joint Surg Am* 2007;89:64-73.
9. Sidlauskas A, Zilinskaite L, Svalkauskiene V. Mandibular pubertal growth spurt prediction. Part one: Method based on



the hand-wrist radiographs. *Stomatologija* 2005;7:16-20.

10. Chapman SM. Ossification of the adductor sesamoid and the adolescent growth spurt. *Angle Orthod* 1972;42:236-44.

11. Hung AL, Chau WW, Shi B, Chow SK, Yu FY, Lam TP, et al. Thumb ossification composite index (TOCI) for predicting peripubertal skeletal maturity and peak height velocity in idiopathic scoliosis: A validation study of premenarchal girls with adolescent idiopathic scoliosis followed longitudinally until skeletal maturity. *J Bone Joint Surg Am* 2017;99:1438-46.

12. Nilsson O, Marino R, De Luca F, Phillip M, Baron J. Endocrine regulation of the growth plate. *Horm Res* 2005;64:157-65.

13. Stagi S, Scalini P, Farello G, Verrotti A. Possible effects of an early diagnosis and treatment in patients with growth hormone deficiency: The state of the art. *Ital J Pediatr* 2017;43:81.

14. Shim KS. Pubertal growth and epiphyseal fusion. *Ann Pediatr Endocrinol Metab* 2015;20:8-12.

15. Sarin VK, Carter DR. Mechanobiology and joint conformity regulate endochondral ossification of sesamoids. *J Orthop Res* 2000;18:706-12.

16. Lesage C, Walker J, Landier F, Chatelain P, Chaussain JL, Bougnères PF. Near normalization of adolescent height with growth hormone therapy in very short children without growth hormone deficiency. *J Pediatr* 1991;119:29-34.

17. Frindik JP, Kemp SF, Sy JP. Effects of recombinant human growth hormone on height and skeletal maturation in growth hormone-deficient children with and without severe pretreatment bone age delay. *Horm Res* 1999;51:15-9.

18. Wilson DM. Regular monitoring of bone age is not useful in children treated with growth hormone. *Pediatrics* 1999;104:1036-9.

19. Hopwood NJ, Hintz RL, Gertner JM, Attie KM, Johanson AJ, Baptista J, et al. Growth response of children with non-growth-hormone deficiency and marked short stature during three years of growth hormone therapy. *J Pediatr* 1993;123:215-22.

20. Kang MJ, Kim EY, Shim YS, Jeong HR, Lee HJ, Yang S, et al. Factors affecting bone age maturation during 3 years of growth hormone treatment in patients with idiopathic growth hormone deficiency and idiopathic short stature: Analysis of data from the LG growth study. *Medicine (Baltimore)* 2019;98:e14962.

21. Cho JH, Jung HW, Shim KS. Growth plate closure and therapeutic interventions. *Clin Exp Pediatr* 2024;67:553-9.

22. Zverev S, Tenner ZM, Coladonato C, Lazar-Antman M. The rising popularity of growth hormone therapy and ensuing orthopedic complications in the pediatric population: A review. *Children (Basel)* 2024;11:1354.

**Conflict of Interest:** Nil

**Source of Support:** Nil

**Consent:** The authors confirm that informed consent was obtained from the patient for publication of this article

**How to Cite this Article**

Ross S, Lu S, Beber S, Groff K, Jaramillo D, Doyle S. Distal Phalangeal Physeal Closure Preceding Ossification of the Thumb Adductor Sesamoid: A Case Report. *Journal of Orthopaedic Case Reports* 2026 July;16(07): 161-165.