

Post-Traumatic Turret Exostosis of the Proximal Phalanx of the Middle Finger: A Rare Case Report and Review of Literature

Samyabrata Das¹, Soumya Biswas¹, Subrata Mondal¹, Kallol Banerjee¹, Partha Sarathi Sarkar¹

Learning Point of the Article:

Turret exostosis of the proximal phalanx, though rare, should be considered in patients with post-traumatic finger swellings, and complete surgical excision guided by histopathology ensures excellent functional recovery with minimal recurrence.

Abstract

Introduction: Turret exostosis is an uncommon benign osteocartilaginous lesion that originates from the cortical surface of bone, most commonly affecting the phalanges of the hand. It is considered a reactive subperiosteal bone proliferation that typically develops following minor trauma. Because its clinical and radiological appearance may resemble other surface bone lesions such as osteochondroma and bizarre parosteal osteochondromatous proliferation (Nora's lesion), accurate diagnosis is important. Involvement of the proximal phalanx is particularly uncommon.

Case Report: A 32-year-old male reported with a progressively growing swelling on the dorsal surface of his right middle finger for 1 year following trauma, which was accompanied by pain and discomfort for 8 months. Radiographs demonstrated a surface-based ossified lesion arising from the proximal phalanx without continuity with the medullary canal. Magnetic resonance imaging revealed an osteocartilaginous lesion without intramedullary extension. The lesion was treated with complete surgical excision. Histopathological examination confirmed the diagnosis of turret exostosis. The patient showed no signs of recurrence at 1-year follow-up and continued to be asymptomatic with a full range of motion.

Conclusion: Turret exostosis of the proximal phalanx is an uncommon lesion that can mimic other periosteal tumors. Careful clinicoradiological evaluation with histopathological confirmation is essential for accurate diagnosis. Complete surgical excision results in excellent functional recovery with minimal recurrence.

Keywords: Turret exostosis, osteocartilaginous lesion, proximal phalanx, Nora's lesion, periosteal tumor.

Introduction

Turret exostosis is an uncommon benign osteocartilaginous lesion arising from the cortical surface of bone and most frequently involving the phalanges of the hand. It is believed to represent a reactive subperiosteal ossification that occurs following minor or repetitive trauma to the digits [1,2]. Patients typically present with a gradually growing firm swelling over the

finger, which may be accompanied by stiffness, pain, or limitation of joint mobility, depending upon the extent and location of the lesion.

Radiographically, turret exostosis typically appears as a well-defined ossified mass arising from the cortical surface of bone without continuity with the medullary canal. This feature helps differentiate it from conventional osteochondroma [3].

Author's Photo Gallery



Dr. Samyabrata Das



Dr. Soumya Biswas



Dr. Subrata Mondal



Dr. Kallol Banerjee



Dr. Partha Sarathi Sarkar

Access this article online

Website:
www.jocr.co.in

DOI:
<https://doi.org/10.13107/jocr.2026.v16.i07.7630>

¹Department of Orthopedic Surgery, North Bengal Medical College and Hospital, Siliguri, West Bengal, India.

Address of Correspondence:

Dr. Samyabrata Das,
Department of Orthopedic Surgery, North Bengal Medical College and Hospital, Siliguri, West Bengal, India.
E-mail: sam.orthopaedics04@gmail.com

Submitted: 21/04/2026; Review: 12/05/2026; Accepted: June 2026; Published: July 2026

DOI: <https://doi.org/10.13107/jocr.2026.v16.i07.7630>

© The Author(s). 2026 Open Access. This article is distributed under the terms of the Creative Commons Attribution 4.0 International License (<https://creativecommons.org/licenses/by-nc/4.0/>), which permits unrestricted use, distribution, and non-commercial reproduction in any medium, provided you give appropriate credit to the original author(s) and the source, provide a link to the Creative Commons license, and indicate if changes were made. The Creative Commons Public Domain Dedication waiver (<http://creativecommons.org/publicdomain/zero/1.0/>) applies to the data made available in this article, unless otherwise stated.

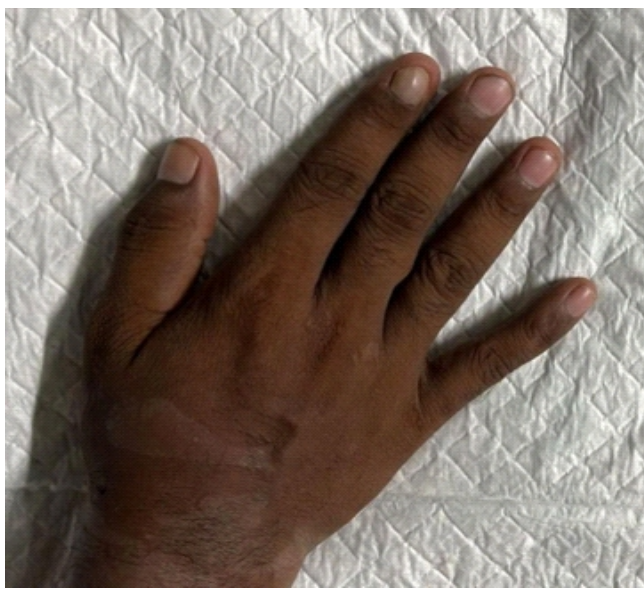

Figure 1: Clinical photograph at presentation showing a firm swelling over the dorsal aspect of the proximal phalanx of the right middle finger.

However, the clinical and radiological findings may overlap with other periosteal lesions such as periosteal chondroma and bizarre parosteal osteochondromatous proliferation (BPOP), commonly referred to as Nora’s lesion [4,5]. Therefore, histopathological examination is essential for establishing the definitive diagnosis.

Most reported cases involve the distal or middle phalanges of the hand, whereas involvement of the proximal phalanx is relatively rare [1,6]. Due to its rarity and potential for misdiagnosis, awareness of this entity is important for appropriate management. Complete surgical excision is the preferred treatment, with excellent functional results and a low chance of recurrence [1,6].

We present a rare case of turret exostosis arising from the proximal phalanx of the middle finger and discuss its clinical features, radiological findings, surgical management, and histopathological characteristics.

Case Report

Patient information

A 32-year-old male patient who predominantly used his right hand presented with a progressively growing swelling on the dorsal part of his right middle finger’s proximal phalanx (Fig. 1). There were no noteworthy comorbidities or prior medical history for the patient.

History of present illness

The swelling had been present for approximately 1 year and was initially painless. Pain developed about 4

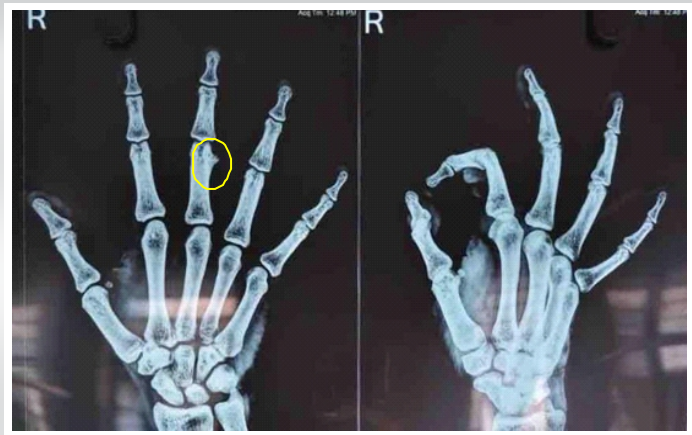

Figure 2: Plain radiograph of the right hand showing a bony outgrowth arising from the cortex of the proximal phalanx of the middle finger (yellow circle).

months after the onset of swelling and gradually increased in intensity. The pain was aggravated by finger movements. The patient reported a history of trivial trauma to the affected finger approximately 1 year before presentation. Mild restriction of flexion at the proximal interphalangeal (PIP) joint was noted.

Clinical examination

On examination, a firm, non-mobile swelling measuring approximately 2 × 1 cm was present over the dorsal surface of the proximal phalanx of the right middle finger. The lesion was tender on palpation. There were no visible signs of inflammation, and the skin above seemed normal. Mild

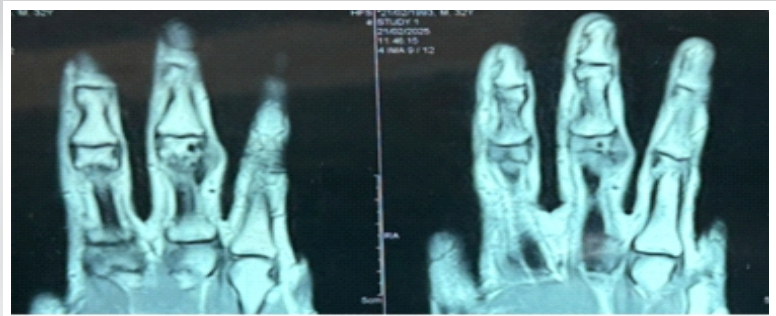


Fig. 3(a)

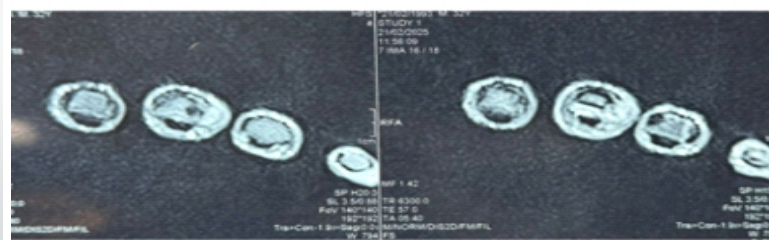


Fig. 3(b)

Figure 3: MRI of the lesion. (a) Coronal section demonstrating a surface-based osteocartilaginous lesion with a visible cartilage cap and no intramedullary extension. (b) Axial section showing the relationship of the lesion to the surrounding soft tissues.



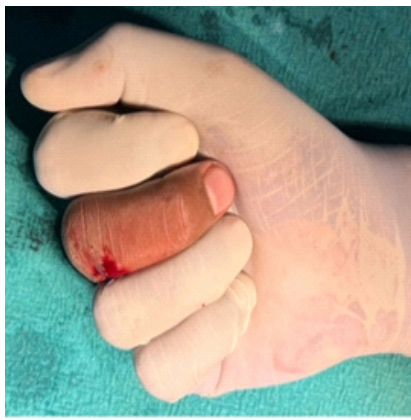

Fig. 4(a)

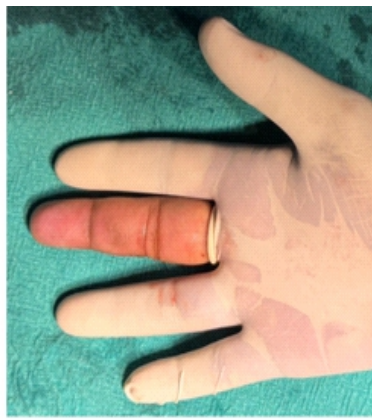

Fig. 4(b)

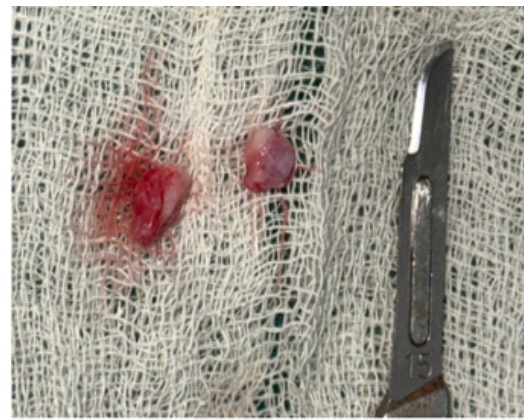


Fig. 4(c)

Figure 4: Intraoperative images. 4(a and b) Surgical exposure and excision of the bony lesion from the dorsal cortex of the proximal phalanx. (4c) Excised osteocartilaginous mass sent for histopathological examination.

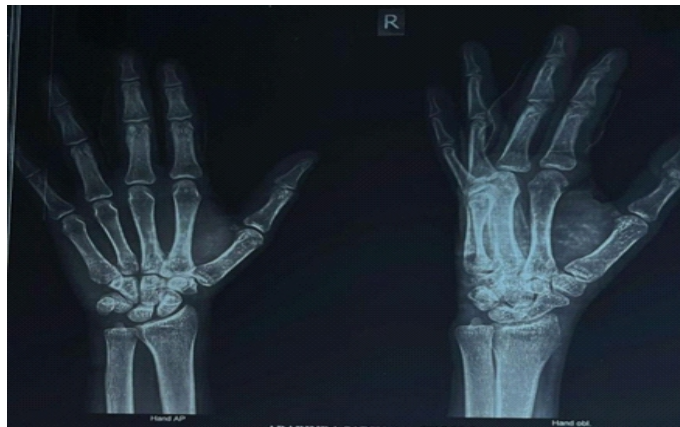

Figure 5: Immediate post-operative radiograph of the right hand demonstrating complete excision of the lesion from the proximal phalanx of the middle finger.

restriction of PIP joint flexion was observed, whereas extension was preserved. Neurovascular examination of the finger was normal.

Investigations

Plain radiographs of the hand (anteroposterior and oblique views) demonstrated a well-defined ossified lesion arising from the cortical surface of the proximal phalanx without continuity with the medullary canal (Fig. 2). Magnetic resonance imaging (MRI) showed a surface-based osteocartilaginous lesion with a thin cartilage cap and no intramedullary extension (Fig. 3). Based on these findings, the differential diagnoses included turret exostosis, osteochondroma [3], periosteal chondroma, and BPOP [4,5].

Treatment

Surgical excision of the lesion was performed under regional anesthesia. Intraoperatively, a well-circumscribed bony mass that measured approximately 2 × 1 cm was identified arising from the dorsal cortex of the proximal phalanx. The lesion was completely excised along with its base (Fig. 4). There was no involvement of the extensor tendon or surrounding soft tissues.

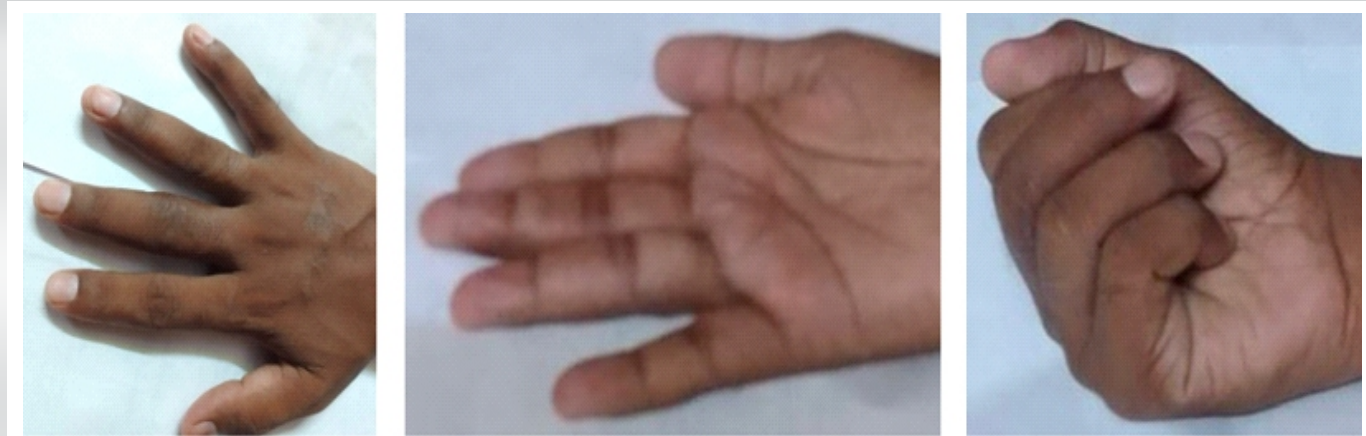


Figure 6: Clinical photograph at 3-month follow-up showing a good range of motion of the right middle finger.

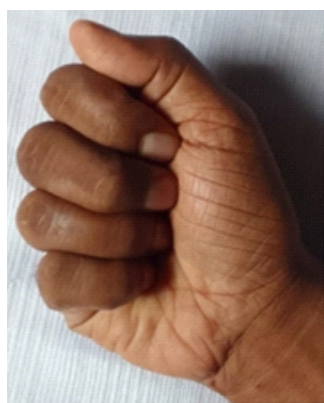

Fig. 7(a)

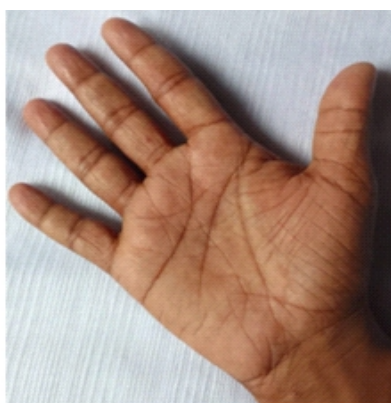

Fig. 7(b)

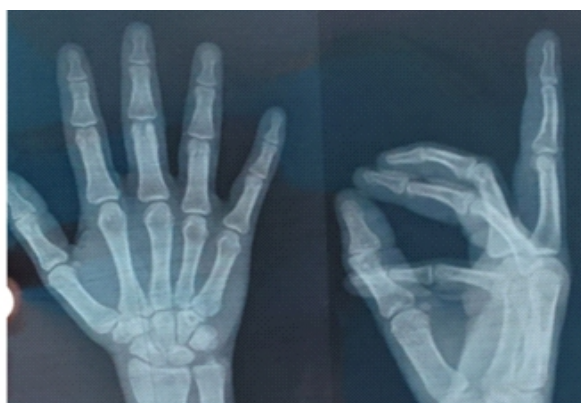

Fig. 7(c)

Figure 7: One-year follow-up images. (a and b) Clinical photographs demonstrating the full range of motion at the proximal and distal interphalangeal joints. (c) Radiograph of the right hand showing no evidence of recurrence.

Post-operative radiographs confirmed complete removal of the lesion (Fig. 5).

Histopathological findings

The diagnosis of turret exostosis was confirmed by histopathological analysis, which demonstrated a cartilage cap made of mature hyaline cartilage with fibrous perichondrium and underlying mature trabecular bone [2].

Follow-up and outcome

The post-operative period was uneventful. At 3-month follow-up, the patient demonstrated good finger mobility. The patient showed no signs of recurrence at the 1-year follow-up, and both the proximal and distal interphalangeal joints had a full range of motion (Fig. 6 and 7).

Discussion

Turret exostosis is a rare benign osteocartilaginous lesion believed to arise from ossification of a subperiosteal hematoma following trauma [1]. Most frequently, the hand's phalanges are affected, particularly the distal and middle phalanges, whereas involvement of the proximal phalanx is relatively uncommon [1,6]. The literature has also included a number of case reports detailing turret exostosis affecting various digits and anatomical locations [7,8,9,10]. The presence of preceding trauma in our patient further supports the reactive nature of this lesion.

A distinct ossified mass that emerges from the cortical surface of the bones, lacking corticomedullary continuity, is the radiographic hallmark of turret exostosis, which helps distinguish it from conventional osteochondroma [3]. MRI is helpful in evaluating the cartilage cap and ruling out intramedullary extension.

An important differential diagnosis is BPOP, also known as Nora's lesion, which typically demonstrates more aggressive growth and has a higher recurrence rate following excision [4, 5]. Distinguishing between these entities may be challenging on imaging alone, making histopathological examination crucial for definitive diagnosis.

Turret exostosis is still best treated with complete surgical excision. Adequate removal of the lesion along with its base reduces the risk of recurrence and restores normal finger function [1,6]. In the present case, complete excision resulted in excellent functional recovery with no recurrence during 1 year of follow-up.

Conclusion

Turret exostosis is an uncommon benign osteocartilaginous lesion that may develop following minor trauma and can present as a dorsal finger swelling. Because its clinical and radiological features may mimic other periosteal lesions, accurate diagnosis requires careful clinicoradiological assessment and histopathological confirmation. Complete surgical excision results in excellent functional recovery with minimal recurrence.

Clinical Message

A slowly enlarging dorsal finger swelling following trauma should prompt consideration of turret exostosis in the differential diagnosis. Awareness of this entity and timely surgical excision after appropriate imaging can prevent diagnostic confusion and ensure good functional recovery.

Declaration of patient consent: The authors certify that they have obtained all appropriate patient consent forms. In the form, the patient has given the consent for his/ her images and other clinical information to be reported in the journal. The patient understands that his/ her names and initials will not be published and due efforts will be made to conceal their identity, but anonymity cannot be guaranteed.

Conflict of interest: Nil **Source of support:** None

References

1. Cañueto J, Santos-Briz A, Yuste-Chaves M, Nieto G, Unamuno P. Turret exostosis or acquired osteochondroma. *Actas Dermosifiliogr* 2011;102:474-5.
2. Mruthyunjaya M, Nekkanti S, Venkateshaiah S. Turret exostosis with swan neck deformity: An unusual presentation. *Arch Hand Microsurg* 2018;23:277-80.
3. Murphey MD, Choi JJ, Kransdorf MJ, Flemming DJ, Gannon FH. Imaging of osteochondroma: Variants and complications with radiologic-pathologic correlation. *Radiographics* 2000;20:1407-34.
4. Nora FE, Dahlin DC, Beabout JW. Bizarre parosteal osteochondromatous proliferations of the hands and feet. *Am J Surg Pathol* 1983;7:245-50.
5. Meneses MF, Unni KK, Swee RG. Bizarre parosteal osteochondromatous proliferation of bone (Nora's lesion). *Am J Surg Pathol* 1993;17:691-7.
6. Ababneh FA, Essa MM, Qasaimeh MA, Khub RA, Beidas MJ. Case report of a rare thumb exostosis. *Int J Res Med Sci* 2022;10:728-30.
7. Kang ST, Kim TH, Kim HW. Huge turret exostosis of metacarpus: A case report. *J Korean Bone Joint Tumor Soc* 2012;18:109-12.
8. Baidriss Y, Moudoud Y, Serraji A, Aguenau O, Fekhouai MR, Bassir RA, *et al.* Solitary osteochondroma of the metacarpal: A case report. *MedPeer* 2025;2(3).
9. Mohanna PN, Moiemmen NS, Frame JD. Turret exostosis of the thumb. *Br J Plast Surg* 2000;53:629-31.
10. Kontogeorgakos VA, Lykissas MG, Mavrodontidis AN, Sioros V, Papachristou D, Batistatou AK, *et al.* Turret exostosis of the hallux. *J Foot Ankle Surg* 2007;46:130-2.

Conflict of Interest: Nil
Source of Support: Nil

Consent: The authors confirm that informed consent was obtained from the patient for publication of this article

How to Cite this Article

Das S, Biswas S, Mondal S, Banerjee K, Sarkar PS. Post-Traumatic Turret Exostosis of the Proximal Phalanx of the Middle Finger: A Rare Case Report and Review of Literature. *Journal of Orthopaedic Case Reports* 2026 July;16(07): 180-184.