

# Intertrochanteric Fracture Secondary to Solitary Osteochondroma: A Case Report and Literature Review

Nabil Alassaf<sup>1</sup>, Turki Alhumaidi Alshammari<sup>1</sup>, Ahmed Essa<sup>1</sup>

## Learning Point of the Article:

Patients with pathologic intertrochanteric hip fractures and a background of osteochondroma can be managed via surgical stabilization as per standard treatment in addition to tumor resection through the most feasible and safe approach based on tumor extension.

## Abstract

**Introduction:** Solitary femoral neck osteochondroma (SFNO) usually presents with pain, impingement, or sciatic neuropathy. Concomitant fracture on presentation is rare. This paper describes the treatment approach in such a situation.

**Case Report:** A 23-year-old male presented after a motor vehicle collision and complained of right hip pain. Clinical assessment and radiological investigations revealed an isolated intertrochanteric femoral fracture adjacent to a posteromedial SFNO. The lesion was resected through a lateral approach, which facilitated simultaneous fracture stabilization with a cephalomedullary nail. A histological sample confirmed the diagnosis. The fracture healed uneventfully with no recurrence of the lesion.

**Conclusion:** Asymptomatic posteromedial SFNO presenting with a fracture may respond well to fixation and removal through a lateral approach.

**Keywords:** Osteochondroma, intertrochanteric fracture, pathologic fracture, cephalomedullary nail.

## Introduction

Osteochondroma is the most common benign bone tumor. In 85% of patients, it manifests as a solitary lesion, and in 15% of patients, it presents with hereditary multiple exostoses (HME). Approximately 50% of osteochondromas are located around the knee. Resection is indicated only for symptomatic compressive lesions or when the adjacent joints are in jeopardy. Malignant transformation and cosmetic factors are infrequent indications for surgical intervention [1]. The overall recurrence rate is about 2%. Interestingly, spontaneous resolution of solitary osteochondromas has been reported [2].

Solitary femoral neck osteochondroma (SFNO) is rare; it requires special attention and careful surgical planning owing to

its proximity to neurovascular structures and vulnerable femoral head blood supply, and the variety of operative corridors for tumor resection in this area. SFNO may present with pain, neuropathy, limp, limited hip range of motion, and ischiofemoral impingement. Impingement can be exaggerated by the presence of thoracolumbar kyphosis and secondary hip extension [3]. Femoral head osteochondroma likely represents another neoplastic process, namely, Trevor's disease, which is approached differently [4]. Juxta-articular, extraskelatal osteochondroma has been reported to float in muscles surrounding the femoral neck [5,6].

In this report, we describe a patient with SFNO who presented with an intertrochanteric fracture. We also aimed to review the

## Author's Photo Gallery



Dr. Nabil Alassaf



Dr. Turki Alhumaidi Alshammari



Dr. Ahmed Essa

Access this article online

Website:  
www.jocr.co.in

DOI:  
<https://doi.org/10.13107/jocr.2026.v16.i07.7634>

<sup>1</sup>Department of Orthopedic Surgery, Hail Health Cluster, Hail, Saudi Arabia.

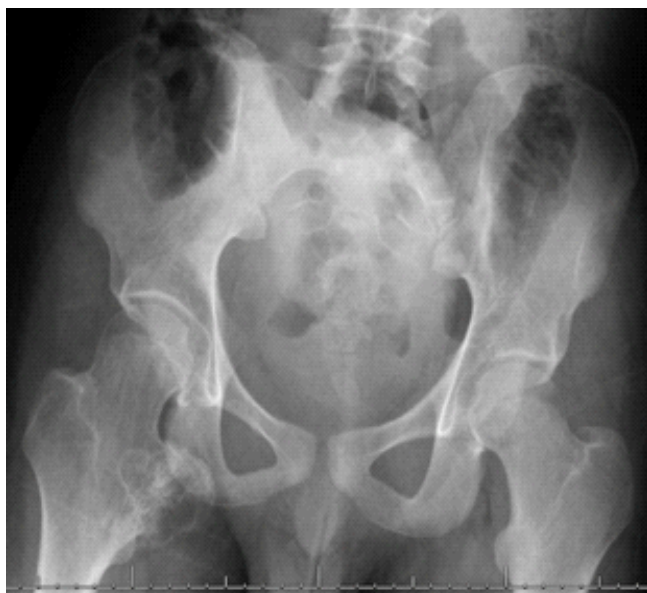### Address of Correspondence:

Dr. Nabil Alassaf,  
Department of Orthopedic Surgery, Hail Health Cluster, Hail, Saudi Arabia.  
E-mail: dr.nabil.alassaf@gmail.com

Submitted: 27/04/2026; Review: 08/05/2026; Accepted: June 2026; Published: July 2026

DOI: <https://doi.org/10.13107/jocr.2026.v16.i07.7634>

© The Author(s). 2026 Open Access. This article is distributed under the terms of the Creative Commons Attribution 4.0 International License (<https://creativecommons.org/licenses/by-nc/4.0/>), which permits unrestricted use, distribution, and non-commercial reproduction in any medium, provided you give appropriate credit to the original author(s) and the source, provide a link to the Creative Commons license, and indicate if changes were made. The Creative Commons Public Domain Dedication waiver (<http://creativecommons.org/publicdomain/zero/1.0/>) applies to the data made available in this article, unless otherwise stated.



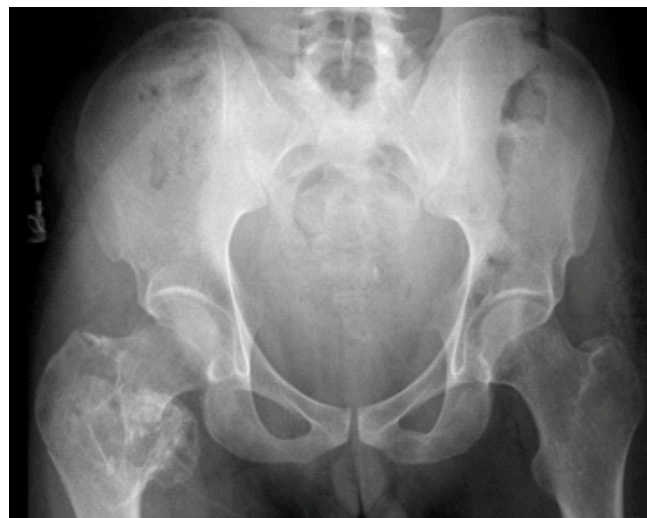**Figure 1:** Pelvic radiograph showing right proximal femur lesion 6 years prior to the current presentation.

literature for appropriate treatment methods that may improve decision-making.

### Case Report

A 23-year-old male was brought to the emergency department of our institution after a head-on motor vehicle collision in February 2021. His Glasgow Coma Scale score was 15, with no evidence of hemodynamic instability. His chief complaint was right hip pain and inability to walk. He had been an unbelted front-seat passenger and had been forced under the dashboard, where he felt a snap in his right hip. There were no other injuries. The patient was completely asymptomatic before this presentation and had no medical illness. He underwent surgery for a right proximal humerus fracture that resulted from a high-energy fall 6 years earlier, and which had healed uneventfully.

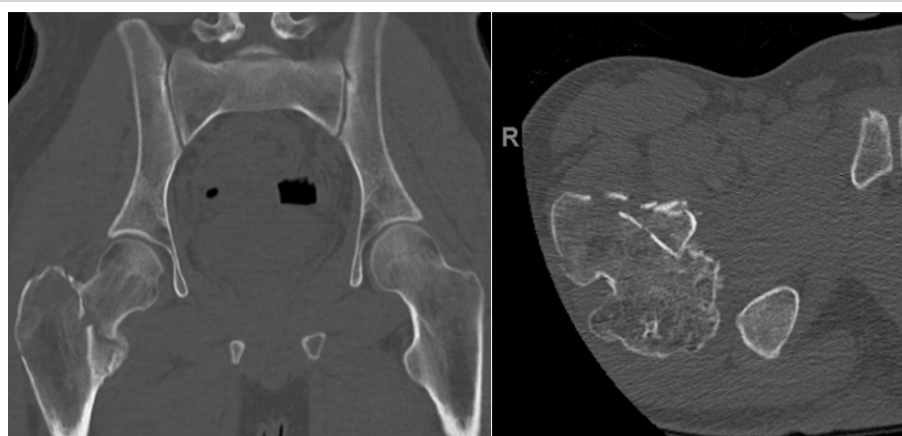An anteroposterior pelvic radiograph at that time was performed as a part of the Advanced Trauma Life Support guidelines, and an asymptomatic right proximal femur lesion, which the patient was not aware of, was noted (Fig. 1). On examination, right hip tenderness was detected, and minimal hip range of motion was painful. The motor, sensory, and vascular exams were normal. New radiographs revealed a right hip intertrochanteric fracture, in addition to the preexisting mass (Fig. 2). A computed tomography (CT) scan established the diagnosis of SFNO, which was continuous



**Figure 2:** Pelvic radiograph obtained in the emergency department revealing right hip intertrochanteric fracture and osteochondroma.

with the displaced fracture (Fig. 3). The tumor arose from the femoral neck just proximal to the lesser trochanter, projecting posteromedially.

We believe that the priority in this case was to address the fracture and resect as much of the asymptomatic lesion as possible, mainly for histologic diagnosis and better healing. This was achieved in the operating room under general anesthesia after admission and preparation. To maintain simplicity and ease, we chose the lateral approach in the supine position. The reduction and fixation were aided by a fracture table and a short dual-screw cephalomedullary nail. The tumor was removed in a piecemeal fashion under fluoroscopy. Adequacy of resection was based on clinical and radiographic assessment of the ischiofemoral space. Histopathologic examination confirmed the diagnosis of osteochondroma. The patient was discharged on post-operative day 2 in good condition. He was allowed partial weight bearing for 6 weeks,



**Figure 3:** Coronal (left image) and axial (right image) computed tomography views outlining the fracture.

**Table 1: Published reports describing solitary femoral neck osteochondroma treatment**

Study	Year	n	Presentation	Excision approach	Outcome
Tschokanow [19]	1969	2	Hip pain	Anterior and lateral	Femoral vein and sciatic nerve injury, AVN in both hips
Griffiths <i>et al.</i> [20]	1991	1	Enlarging mass and pain	Posterior	No further symptoms
Siebenrock and Ganz [21]	2002	2	Pain, restricted range of motion and limp	Surgical hip dislocation	No or minimal symptoms
Jones and Kinninmonth [22]	2005	1	Low energy hip dislocation	Posterior	Not reported
Feeley and Kelly [23]	2009	1	Hip pain	Arthroscopic	Pain improved
Hussain <i>et al.</i> [24]	2010	1	Groin pain	Posterior, followed by arthroscopic osteochondroplasty and labral repair for persistent symptoms	Symptoms improved after the 2 <sup>nd</sup> surgery
Yu <i>et al.</i> [25]	2010	1	Sciatic neuropathy	Posterior with prophylactic percutaneous screws	Resolution of neurologic findings
Chana-Rodríguez <i>et al.</i> [26]	2011	1	Groin pain	Medial	Asymptomatic patient
Muzaffar <i>et al.</i> [27]	2012	1	Hip and leg pain with restricted movements of the hip	Posterior	symptoms relieved
Ramos-Pascua <i>et al.</i> [17]	2012	6	Sciatica, inguinal, gluteal and thigh pain	Anterior or posterior en-bloc resection, based on location of the mass	Excellent, one intraoperative basicervical fracture fixed and healed uneventfully
Li <i>et al.</i> [28]	2012	1	Groin pain	Surgical hip dislocation	No pain
Kanauchi <i>et al.</i> [29]	2012	2	Hip pain	Posterior	Pain improved
Nisar <i>et al.</i> [30]	2014	2	Groin pain	Surgical hip dislocation	No recurrence of symptom
Aguiar and Dantas [31]	2014	1	Femoroacetabular impingement	Arthroscopic	Not reported
Jung <i>et al.</i> [32]	2015	1	Inguinal pain and internal hip snapping	Arthroscopic	Symptoms resolved
Yu <i>et al.</i> [33]	2015	2	Hip pain, lesser trochanter mass extending anteriorly	Anterior between the femoral artery and nerve	Satisfactory pain relief
Sharfman <i>et al.</i> [34]	2016	1	Groin pain and clicking	Arthroscopic	Complete recovery
Aldashash and Elraie [35]	2017	1	Gluteal pain and sciatica	Posterior	Neuropathy resolved, mild residual pain
Kingma <i>et al.</i> [8]	2017	1	Recurrent hematoma and left leg tingling	Observation without intervention	Symptoms disappeared

Wang <i>et al.</i> [36]	2017	1	Limp and inguinal pain	Arthroscopic	Patient improved
Jeon <i>et al.</i> [9]	2017	13	Pain and neuropathy	Posterior, anterior and medial based on lesion location	One transient Sciatic nerve palsy
Yadav <i>et al.</i> [37]	2018	1	Swelling, pain and sciatic neuropathy	Posterior	Resolution of symptoms
Keny <i>et al.</i> [38]	2020	1	Pain and swelling	Posterior	No complications or recurrence
Hammad <i>et al.</i> [39]	2021	1	Posterior hip pain and lump	Lateral with prophylactic screws	Symptoms resolved
Sun <i>et al.</i> [15]	2022	8	Sciatica, impingement and pain	Navigation assisted, 3 had posterior, 5 underwent anterior, 2 prophylactic fixation, one nail and one DHS	No complications or recurrence
Corpus-Zuñiga <i>et al.</i> [3]	2023	1	Posterior hip pain	Posterior	Complete pain relief
Present study	2026	1	Hip fracture	Lateral with cephalomedullary fixation	Intermittent lateral thigh pain
<b>AVN: Avascular necrosis, DHS: Dynamic hip screw</b>					

followed by full weight bearing. At 3 years and 8 months of follow-up (October 2024), the patient reported mild activity-related right lateral thigh pain. However, he demonstrated a full range of motion, had a healed fracture on radiographs, and no evidence of recurrence (Fig. 4). We believe that the treatment goals were achieved.

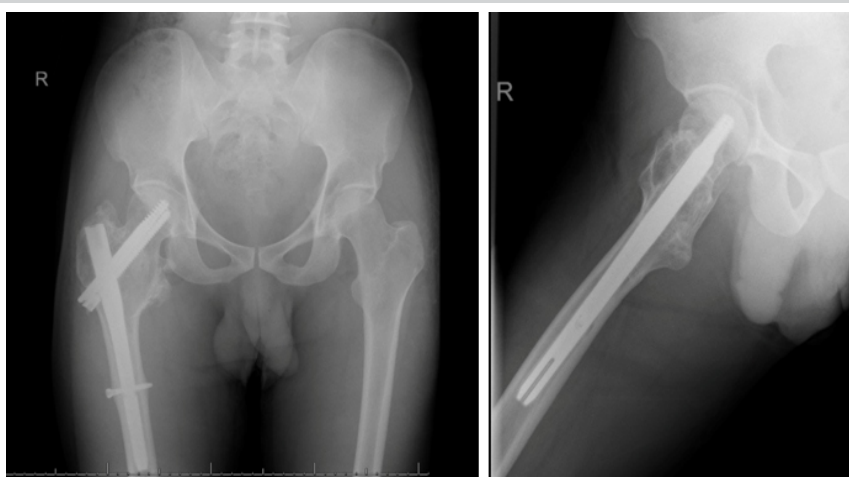
**Discussion**

The lateral approach is probably less tedious because it allows for convenient simultaneous reduction and fixation of the fracture with easy intraoperative imaging. However, it does not allow for thorough medial resection. A cephalomedullary nail provides a reliable form of stabilization but may cause irritation to the iliotibial band. It is probably advantageous to use intra-medullary fixation compared to extra-medullary plates, especially when the femoral calcar area and the lateral wall are compromised. The tumor in this patient originated from the medial femoral neck. In a study of 100 hips with HME, 79% of proximal femur osteochondromas were found medially [7].

Conservative treatment has been described in patients with minimal symptomatology [8]. After the patient developed post-operative complete sciatic nerve palsy, Jeon et al. warned against approaching a posteriorly protruding tumor through the anterior approach; the patient underwent immediate post-operative

exploration, and the nerve recovered 6 months postoperatively [9]. Ghoti et al. excised a posterior femoral neck osteochondroma through a posterior approach in a patient with HME, which resulted in the resolution of symptoms and no recurrence on follow-up after 3 years [10]. Sorel et al. have used surgical hip dislocation to treat femoral neck osteochondroma in 20 hips of HME patients; there was significant improvement in pain and range of motion at the expense of four notable complications: One fibrous nonunion of the trochanteric osteotomy, another osteotomy fixation failure, a pertrochanteric fracture, and avascular necrosis [11].

Small intracapsular lesions are likely amenable to arthroscopic resection. Hip arthroscopy has been used in patients with HME and other hip afflictions such as synovial chondromatosis [12].



**Figure 4:** Anteroposterior and lateral follow-up radiographs showing residual medial tumor tissue.



Mansor et al. resected a metachondromatosis femoral neck lesion in a child arthroscopically [13]. Alter et al. described arthroscopic hip extended capsulotomy for a 2.2 cm osteochondroma, which was distal to the capsular attachment [14]. Sun et al. used intraoperative CT navigation in 13 patients with femoral neck osteochondroma, 8 of whom were solitary; 9 patients had posterior exposure, whereas four hips were operated on through the anterior approach [15].

We are not aware of any published case of SFNO that presented with a hip fracture. Schubert et al. described posteromedial femoral neck osteochondroma in a 53-year-old woman who was known to have HME. She presented initially with symptoms of ischiofemoral impingement, and 3 months later she was referred with a displaced intracapsular hip fracture that was treated with a total hip replacement [16]. In the series reported by Ramos-Pascua et al., a 66-year-old male patient was noted to have an iatrogenic basicervical femoral neck fracture during excision through an anterior approach of a medial SFNO that was treated by a short cephalomedullary nail [17]. Bottner et al. reported an intraoperative femoral neck fracture during

osteochondroma removal in a 44-year-old patient whose osteosynthesis failed and who required total hip arthroplasty [18].

The risk of recurrence after resection of SFNO is low, as there is no single case of recurrence in the relevant papers as summarized in Table 1.

### Conclusion

The treatment of osteochondroma is based on the presenting symptoms, and the surgical approach is best dictated by the location of the lesion within the femoral neck. Associated actual or impending fractures are fixed through standard techniques and implants.

### Clinical Message

A lateral approach to surgical fixation and tumor removal can be used to treat extracapsular hip fractures caused by posteromedial SFNO.

**Declaration of patient consent:** The authors certify that they have obtained all appropriate patient consent forms. In the form, the patient has given the consent for his/ her images and other clinical information to be reported in the journal. The patient understands that his/ her names and initials will not be published and due efforts will be made to conceal their identity, but anonymity cannot be guaranteed.

**Conflict of interest:** Nil **Source of support:** None

### References

1. Tepelenis K, Papatianos G, Kitsouli A, Troupis T, Barbouti A, Vlachos K, et al. Osteochondromas: An updated review of epidemiology, pathogenesis, clinical presentation, radiological features and treatment options. *In Vivo* 2021;35:681-91.
2. Passanise AM, Mehlman CT, Wall EJ, Dieterle JP. Radiographic evidence of regression of a solitary osteochondroma: A report of 4 cases and a literature review. *J Pediatr Orthop* 2011;31:312-6.
3. Corpus-Zuñiga FM, Muramatsu K, Yamashita Y, Mervyn Tec L. Unusual ischiofemoral impingement secondary to osteochondroma in an elderly patient with thoracolumbar kyphosis: A case report. *J Orthop Rep* 2023;2:100223.
4. Calafiore F, Fidanza A, Venosa M, Fabiani R, Logroscino G. Hip joint osteochondroma treated with short stem total hip arthroplasty: A case report. *Acta Biomed* 2023;94:e2023188.
5. Liu ZJ, Zhao Q, Zhang LJ. Extracapsular osteochondroma near the hip: A pediatric case. *J Pediatr Orthop B* 2010;19:524-8.
6. Kanwat M, Jangira V, Sharma B, Chauhan D. Can an exostosis be free floating without any continuity to the underlying bone: A diagnostic dilemma. *J Clin Orthop Trauma* 2017;8:S87-9.
7. Matsumoto K, Ogawa H, Akiyama H. Radiographic characteristics of the hip joint in skeletally mature patients with multiple hereditary exostoses. *Skeletal Radiol* 2020;49:1773-9.
8. Kingma BF, Knobben BA, Somford MP. A Motorcyclist with hematomas and tingling in his leg. *Ned Tijdschr Geneesk* 2017;161:D633.
9. Jeon DG, Cho WH, Song WS, Kong CB, Lee SY, Kim DY. The optimal surgical approach and complications in resecting osteochondroma around the lesser trochanter. *J Korean Orthop Assoc* 2017;52:33-9.
10. Ghoti S, Mahajan NP, Kondewar P, Pande KP, Chaudhari K. A case report on surgical excision of intracapsular osteochondroma of femur neck using mini-arthrotomy without hip dislocation in a young female with hereditary multiple exostoses. *J Orthop Case Rep* 2022;12:66-9.
11. Sorel JC, Façee Schaeffer M, Homan AS, Scholtes VA, Kempen DH, Ham SJ. Surgical hip dislocation according to Ganz for excision of osteochondromas in patients with multiple hereditary exostoses. *Bone Joint J* 2016;98-B:260-5.
12. Bonnomet F, Clavert P, Abidine FZ, Gicquel P, Clavert JM,

Kempf JF. Hip arthroscopy in hereditary multiple exostoses: A new perspective of treatment. *Arthroscopy* 2001;17:E40.

13. Mansor N, Saisu T, Kakizaki J, Oikawa Y, Kamegaya M. Arthroscopic resection of femoral neck osteochondroma: Report of a pediatric case of metachondromatosis. *J Orthop Sci* 2022;27:739-42.

14. Alter T, Okoroha KR, Kunze KN, Beck EC, Nho SJ. Arthroscopic femoral osteochondroplasty with capsular plication for osteochondroma of the femoral neck. *Arthrosc Tech* 2019;8:e1353-9.

15. Sun Y, Chan CM, Yu F, Li Y, Niu X. Computer navigation-aided excision of proximal femoral osteochondroma: Surgical technique. *Comput Math Methods Med* 2022;2022:7635945.

16. Schubert T, Navez M, Galant C, Docquier PL, Acid S, Lecouvet FE. Femoral osteochondroma responsible for ischiofemoral impingement, bursitis, and secondary lipoma arborescens mimicking malignant transformation. *Acta Radiol Open* 2019;8:1-7.

17. Ramos-Pascua LR, Sánchez-Herráez S, Alonso-Barrio JA, Alonso-León A. Osteocondromas solitarios del extremo proximal del fémur. Indicación y resultados de la resección en bloque sin luxación de la cadera [TPS1.1]. *Rev Esp Cir Ortop Traumatol* 2012;56:24-31.

18. Bottner F, Rodl R, Kordish I, Winklemann W, Gosheger G, Lindner N. Surgical treatment of symptomatic osteochondroma. A three- to eight-year follow-up study. *J Bone Joint Surg Br* 2003;85:1161-5.

19. Tschokanow K. Two cases of osteochondroma of the femur neck. *Beitr Orthop Traumatol* 1969;16:751-2.

20. Griffiths HJ, Thompson RC Jr, Galloway HR, Everson LI, Suh JS. Bursitis in association with solitary osteochondromas presenting as mass lesions. *Skeletal Radiol* 1991;20:513-6.

21. Siebenrock KA, Ganz R. Osteochondroma of the femoral neck. *Clin Orthop Relat Res* 2002;394:211-8.

22. Jones BG, Kinninmonth AW. Low-energy hip dislocation in the young. *J Trauma Inj Infect Crit Care* 2005;58:638-9.

23. Feeley BT, Kelly BT. Arthroscopic management of an intraarticular osteochondroma of the hip. *Orthop Rev (Pavia)* 2009;1:e2.

24. Hussain W, Avedian R, Terry M, Peabody T. Solitary osteochondroma of the proximal femur and femoral acetabular impingement. *Orthopedics* 2010;33:51.

25. Yu K, Meehan JP, Fritz A, Jamali AA. Osteochondroma of the femoral neck: A rare cause of sciatic nerve compression. *Orthopedics* 2010;33:625-6.

26. Chana-Rodríguez F, López-Capapé D, Rojo-Manaute J, Vaquero-Martín J, Alonso-Martín JM, González-Santander M, et al. Ludloff approach for osteochondroma in the lesser trochanter in a young

middle-distance runner. *Eur Orthop Traumatol* 2011;2:83-5.

27. Muzaffar N, Bashir N, Baba A, Ahmad A, Ahmad N. Isolated osteochondroma of the femoral neck presenting as hip and leg pain. A case study. *Ortop Traumatol Rehabil* 2012;14:183-7.

28. Li M, Luettringhaus T, Walker KR, Cole PA. Operative treatment of femoral neck osteochondroma through a digastric approach in a pediatric patient: A case report and review of the literature. *J Pediatr Orthop B* 2012;21:230-4.

29. Kanauchi T, Suganuma J, Kawasaki T, Mochizuki R, Inoue Y, Uchikawa S, et al. Fracture of an osteochondroma of the femoral neck caused by impingement against the ischium. *Orthopedics* 2012;35:e1438-41.

30. Nisar A, Gulhane S, Mahendra A, Meek RM, Patil S. Surgical dislocation of the hip for excision of benign tumours. *J Orthop* 2014;11:28-36.

31. Aguiar T, Dantas P. Arthroscopic resection of intra-articular osteochondromas of the hip. *Arthrosc Tech* 2014;3:e347-50.

32. Jung HT, Hwang DS, Jeon YS, Kim PS. Arthroscopic resection of osteochondroma of hip joint associated with internal snapping: A case report. *Hip Pelvis* 2015;27:43-8.

33. Yu Y, Sun X, Song X, Tian Z, Zhou Y. A novel surgical approach for the treatment of tumors in the lesser trochanter. *Exp Ther Med* 2015;10:201-6.

34. Sharfman ZT, Atzmon R, Gortzak Y, Rotem G, Drexler M, Haviv B, et al. Hip arthroscopy for intra-capsular benign tumors: A case series. *J Hip Preserv Surg* 2016;3:312-7.

35. Aldashash F, Elraie M. Solitary osteochondroma of the proximal femur causing sciatic nerve compression. *Ann Saudi Med* 2017;37:166-9.

36. Wang SI, Park EH, Yoon SJ, Kim JR. Intra-articular osteochondroma of the posteroinferior femoral neck associated with hip joint osteochondromatosis: A case report. *Mol Clin Oncol* 2017;7:915-8.

37. Yadav S, Maurya P, Kumar M, Arya R. Osteochondroma of the posterior femoral neck: A rare cause of sciatic nerve compression. *Global J Res Anal* 2018;7:48-9.

38. Keny S, Dahapute A, Shah S, Marathe N. Surgical excision of a solitary osteochondroma arising from the lesser trochanter in an adult: A case report. *Int J Res Orthop* 2020;6:1112-6.

39. Hammad Y, Saleh HA, Aburumman IF, Balasim M, Al-Hyari MI, Al-Ajlouni J. A rare case of intra-articular osteochondroma of the femoral neck: A case report. *J Ortho Case Rep* 2021;11:91-6

**Conflict of Interest:** Nil

**Source of Support:** Nil

**Consent:** The authors confirm that informed consent was obtained from the patient for publication of this article

**How to Cite this Article**

Alassaf N, Alshammari TA, Essa A. Intertrochanteric Fracture Secondary to Solitary Osteochondroma: A Case Report and Literature Review. *Journal of Orthopaedic Case Reports* 2026 July;16(07):192-197.

