

# Arthroscopic Reconstruction of Injured Anterior Cruciate Ligament Using Peroneus Longus Graft With Fixed Loop Endobutton – A Prospective Study

Subodh B Shetty<sup>1</sup>, Powdhan H Prabhakar<sup>1</sup>, Vachan Kajava P.<sup>1</sup>, Harsh Kirthi Rao<sup>1</sup>, Lokesh Sarma M. K.<sup>1</sup>

## Learning Point of the Article:

Functional outcome of the graft and implant.

## Abstract

**Introduction:** ACL injuries are more common amongst active young people where RTA and sports injuries predominate as the most common methods of injury ACL reconstruction with peroneus longus graft method have been used more frequently nowadays. The advantages of peroneus longus graft are, Adequate graft length of minimum of 25 to 30 cm. Adequate thickness of minimum 8.5 to 9mm, Less incidence of graft thinning, Lesser hamstring and quadriceps weakness, Minimal donor site morbidity. Minimal restriction of ankle movements.

**Materials and Methods:** A prospective study of 25 patients with injured anterior cruciate ligament without meniscal injury within the age group of 18-55 years managed with arthroscopic reconstruction of anterior cruciate ligament with peroneus longus graft and fixed loop endobutton at femoral side and interference screw at tibial side. Functional outcome was assessed using clinical examination, International Knee Documentation committee and Lysholm knee scoring scale, FADI score (foot and ankle disability index score). Patients were followed up at 2, 4, 8, 12 weeks and 6, 8 months post-operatively.

**Results:** This study consists of 25 cases of Anterior Cruciate Ligament injury. ACL rupture was common in second and third decade of life. In our study, 18(63.34%) were sports related injuries, 5(26.66%) were due to road traffic accidents and 2(10%) were atraumatic degenerations. 22(80%) showed excellent results and 3(20%) showed good results

**Conclusions:** Arthroscopic ACL reconstruction using peroneus longus graft and Fixed-loop Endobutton and interference screws provided excellent post-operative clinical outcome in terms of knee stability, subjective knee and ankle function and range of movements of the knee and ankle in our study.

**Keywords:** Arthroscopic surgery, Anterior cruciate ligament, Fixed-loop Endobutton, interference screws peroneus longus graft.

## Introduction

The anterior cruciate ligament (ACL) is well known for its primary restraint on the anterior translation of tibia on femur. It also prevents hyperextension of knee during full extension. It is a secondary stabilizer of the knee against rotational and varus and valgus stress. The ACL injury is one of the most common serious

ligament injuries of the knee due to its primary role in knee stabilization and its role in knee biomechanics [1]. The ACL rupture being the one of the most common cause for visit to the orthopedic clinic and its reconstruction is strongly recommended for an active patient as it prevents any knee instability, further knee injuries, meniscal damage, and early

## Author's Photo Gallery



Dr. Subodh B Shetty



Dr. Powdhan H Prabhakar



Dr. Vachan Kajava P.



Dr. Harsh Kirthi Rao



Dr. Lokesh Sarma M.K.

Access this article online

Website:  
www.jocr.co.in

DOI:  
<https://doi.org/10.13107/jocr.2024.v14.i10.4872>

<sup>1</sup>Department of Orthopaedic Surgery, J.J.M. Medical College, Davangere, Karnataka, India.

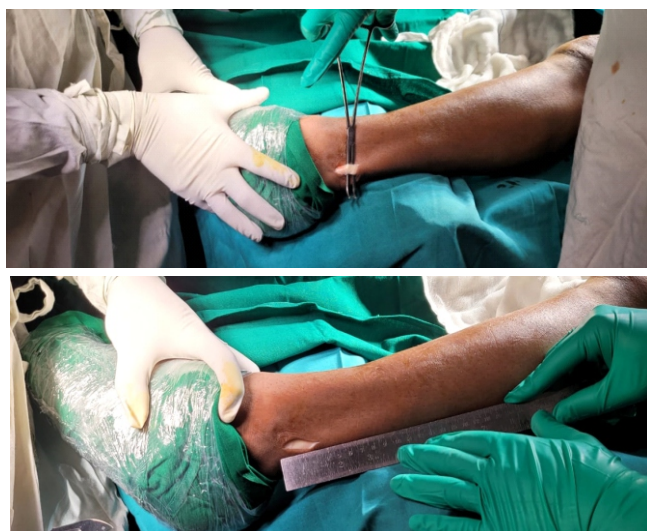### Address of Correspondence:

Dr. Subodh B Shetty,  
Department of Orthopaedic Surgery, J.J.M Medical College, Davangere-577004, Karnataka, India.  
E-mail: drbsshetty@gmail.com

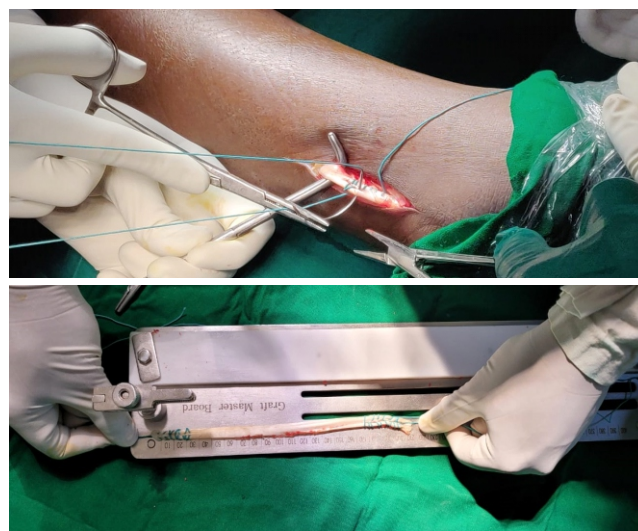
Submitted: 22/07/2024; Review: 09/08/2024; Accepted: September 2024; Published: October 2024

DOI: <https://doi.org/10.13107/jocr.2024.v14.i10.4872>

This is an open access journal, and articles are distributed under the terms of the Creative Commons Attribution-NonCommercial-ShareAlike 4.0 License <https://creativecommons.org/licenses/by-nc-sa/4.0/>, which allows others to remix, tweak, and build upon the work non-commercially, as long as appropriate credit is given and the new creations are licensed under the identical terms



**Figure 1:** Incision site and identification of the peroneus longus tendon.



**Figure 2:** Bunnell suturing technique before harvesting tendon (above) and final prepared graft of 22-cm length (below).

osteoarthritis [2]. The arthroscopic approach has advantages such as smaller skin and capsular incisions, improved viewing of the intercondylar notch for placement of tunnel and attachment sites, fewer adhesions, lesser postoperative pain, early motion, and easier rehabilitation [3]. ACL injuries are more common among active young people where road traffic accident (RTA) and sports injuries predominate as the most common methods of injury ACL reconstruction with peroneus longus graft method have used more frequently nowadays. (Fig. 1). The advantages of peroneus longus graft are as follows:

- Adequate graft length of minimum of 25–30 cm
- Adequate thickness of minimum 8.5–9 mm
- Less incidence of graft thinning
- Lesser hamstring and quadriceps weakness.
- Minimal donor site morbidity
- Minimal restriction of ankle movements

The current gold-standard treatment for ACL tear is arthroscopic reconstruction, and the most commonly used autografts for primary ACL reconstruction are bone-patellar tendon-bone and four-strand hamstring tendon graft.

### Materials and Methods

A prospective study of 25 patients with injured ACL without meniscal injury within the age group of 18–55 years managed with arthroscopic reconstruction of ACL with peroneus longus graft and fixed loop endobutton at femoral side and interference screw at tibial side. Sample size was calculated using Cochran's sample size formula.

### Inclusion criteria

1. Age 15–55 years
2. ACL injury with or without meniscal injury
3. Associated with symptoms of instability.

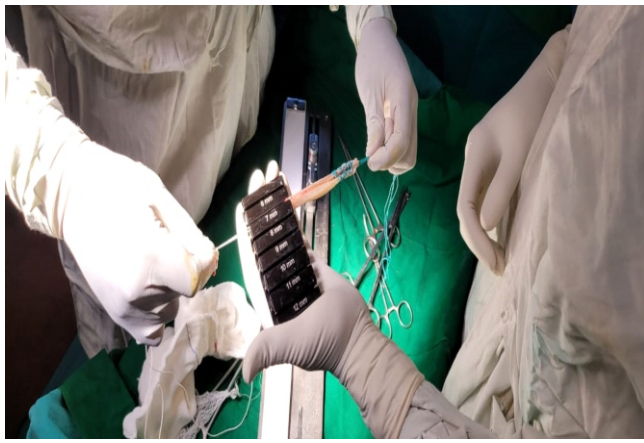### Exclusion criteria

1. ACL avulsion fractures and multiligament injuries
2. Fractures in the ipsilateral or contralateral limb
3. Revision ACL surgery

Functional outcome was assessed using clinical examination, international knee documentation committee, Lysholm knee scoring scale, and foot and ankle disability index score (FADI score). Patients were followed up at 2, 4, 8, 12 weeks and 6, 8 months post-operatively.

### Maneuver

All surgeries were done with a pneumatic tourniquet. Surgeries were performed in supine position with the operating knee flexed to 60–70° with the help of a bolster and a thigh support with standard anteromedial and anterolateral portals. Diagnostic arthroscopy was done to assess the internal derangement of the knee and confirm an ACL tear. Peroneus longus was harvested using a 5 cm vertical incision placed proximal to lateral malleolus. Graft was doubled and prepared on the graft master board. Average thickness of the graft was measured to be  $8.1 \pm 0.7$ –0.9 mm and average length of the graft



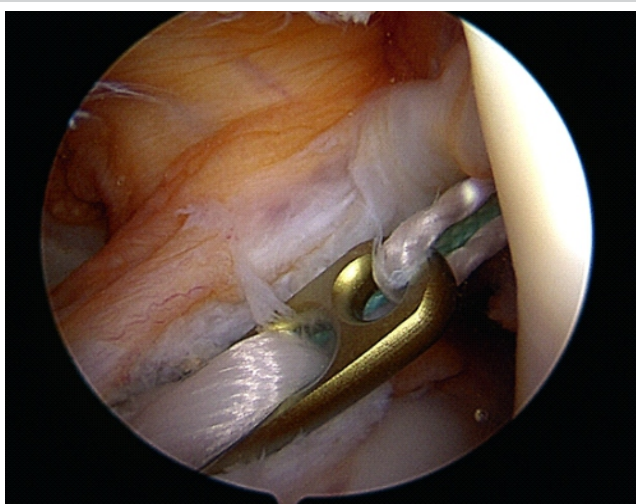
**Figure 3:** Graft thickness measurement.

was measured to be 22 cm. (Fig. 2).

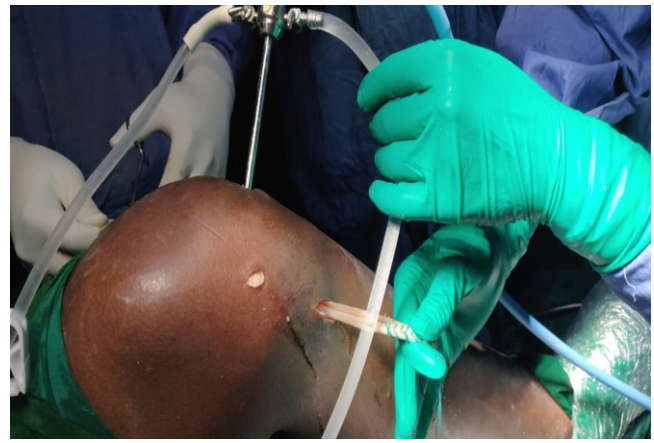
Femoral and tibial tunnel was prepared using appropriate size drills and instruments. Prepared graft was mounted on a fixed-loop endobutton and fixed to the femoral side. Tibial side was secured using an interference screw. Post-operative physiotherapy was followed as per standard ACL rehabilitation protocol. (Fig.3).

### Discussion

Successful clinical outcomes following ACL reconstruction with a peroneus longus graft has been reported by many authors with the primary goal of ACL reconstruction being restoring the stability of the knee [4-9]. All patients in our study underwent arthroscopy-assisted ACL reconstruction with doubled peroneus longus autograft from ipsilateral limb using fixed-loop endobutton, cortical suspensory fixation method for femoral side and non-absorbable titanium interference screw,



**Figure 5:** Endobutton passage inside the knee.



**Figure 4:** Graft passage through the tibial tunnel under arthroscopic visualization.

and aperture fixation method for tibial side. [10-14]. (Fig. 4 and 5).

### Mode of injury

A study conducted by Chaudhary et al. [13] opined that 66.7% injuries were caused by sporting activities, followed by motor vehicle accident accounted for 30.8%. Another study conducted by Patond et al. found sports activities to be the predominant cause of ACL injuries. In our study, 15 (60%) participants had sports related injuries, 7 (28.34%) were due to RTAs, and 3 (12%) were other modes of injury such as skid and fall and atraumatic degenerations suggesting comparable modes of injuries.

### Age distribution

The mean age of patients (in years) in our study was  $28.48 \pm 6.65$  years. The results of our study are comparable to the results of other studies such as the ones conducted by Chaudhary et al. [13] (mean age of 26.8 years) and Specchiulli et al. [12] (mean age of 27 years).

### Functional outcome

The mean post-operative FADI score showed no change in pre-operative score of 99.6–98.6% in our study. The mean post-operative IKDC score improved from pre-operative score of 64–99% in our study.

In Cirstoiu et al., there was early recovery with minimum post-interventional pain, increased mobility of the knee as early as 1st 2-week post-operation, and significant reduction of duration of hospitalization and costs when arthroscopic ACL reconstruction was performed with peroneus longus autografts.

In Rhatomy et al., ACL reconstruction with peroneus longus

autograft has excellent functional score in IKDC, modified Cincinnati, Tegner–Lysholm score at 2-year follow-up with the advantages of greater graft diameter, less thigh hypotrophy, good serial hop test result, and excellent ankle function based on AOFAS and FADI score.

#### Limitations of the study

It is not a comparative study done with hamstring graft.

### Results

This study consists of 25 cases of ACL injury. ACL rupture was common in second and third decade of life. In our study, 18 (63.34%) were sports-related injuries, 5 (26.66%) were due to RTAs, and 2 (10%) were atraumatic degenerations. 22 (80%) showed excellent results and 3 (20%) showed good results.

As per the IKDC scores, the post-operative average of  $95.6 \pm 5.277\%$  was found to have a  $P < 0.05$  compared to pre-operative average of  $46.4 \pm 10.612$  making it statistically significant.

As per the Lysholm scores, 23 patients (80%) had excellent results whereas 2 patients (20%) had good results.

As per the FADI, the post-operative average of  $98.6 \pm 2.277\%$  was found to have change in P-value compared to pre-operative average of  $99.6 \pm 8.712$  making it statistically insignificant.

### Conclusion

Arthroscopic ACL reconstruction using peroneus longus graft and fixed-loop endobutton and interference screws provided excellent post-operative clinical outcome in terms of knee stability, subjective knee and ankle function, and range of movements of the knee and ankle in our study.

### Clinical Message

Improvement in the functional outcome noted related to the graft and implant peroneus longus graft has an advantage in terms of adequate graft thickness and length compared to the other autografts.

**Declaration of patient consent:** The authors certify that they have obtained all appropriate patient consent forms. In the form, the patient has given the consent for his/ her images and other clinical information to be reported in the journal. The patient understands that his/ her names and initials will not be published and due efforts will be made to conceal their identity, but anonymity cannot be guaranteed.

**Conflict of interest:** Nil **Source of support:** None

### References

1. Varshney MK. Essential Orthopedics (Principles and Practice). 1st ed., Vol. 134., Ch. 34. New Delhi: Jaypee Brothers Medical Publishers; 2016. p. 866.
2. Ranjan R, Gaba S, Goel L, Asif N, Kalra M, Kumar R, et al. In vivo comparison of a fixed loop (Endo Button CL) with an adjustable loop (Tight Rope RT) device for femoral fixation of the graft in ACL reconstruction: A prospective randomized study and a literature review. *J Orthop Surg (Hong Kong)* 2018;26:2309499018799787.
3. Terry Canale S, James Beay H. Arthroscopy of the Lower Extremity: Campbells Operative Orthopaedics. 11th ed. Netherlands: Elsevier; 2023. p. 2855-6.
4. John R, Dhillon MS, Syam K, Prabhakar S, Behera P, Singh H. Epidemiological profile of sports-related knee injuries in northern India: An observational study at a tertiary care centre. *J Clin Orthop Trauma* 2016;7:207-11.
5. Samuelsen BT, Webster KE, Johnson NR, Hewett TE, Krych AJ. Hamstring autograft versus patellar tendon autograft for ACL Reconstruction: Is there a difference in graft failure rate? A meta-analysis of 47,613 patients. *Clin Orthop Relat Res* 2017;475:2459-68.
6. Joshi S, Shetty UC, Salim MD, Meena N, Kumar RS, Rao VK. Peroneus longus tendon autograft for anterior cruciate ligament reconstruction: A safe and effective alternative in nonathletic patients. *Niger J Surg* 2021;27:42-7.
7. Cirstoiu C, Circota G, Panaitescu C, Niculaita R. The advantage of arthroscopic anterior cruciate ligament reconstruction with autograft from the tendons of the semitendinosus-gracilis muscles for the recovery of the stability of the knee. *Maedica (Bucur)* 2011;6:109-13
8. Rhatomy S, Hartoko L, Setyawan R, Soekarno NR, Zainal Asikin AI, Pridianto D, et al. Single bundle ACL reconstruction with peroneus longus tendon graft: 2-years follow-up. *J Clin Orthop Trauma* 2019;11:S332-6.
9. Wiradiputra AE, Febyan, Aryana GN. Peroneus longus tendon graft for anterior cruciate ligament reconstruction: A



case report and review of literature. *Int J Surg Case Rep* 2021;83:106028.

10. Mousavi H, Maleki A, Nobakht A. Comparative study after hamstring anterior cruciate ligament reconstruction with endobutton and rigidfix: A clinical trial study. *Adv Biomed Res* 2017;6:136.

11. Asmussen CA, Attrup ML, Thorborg K, Hölmich P. Passive knee stability after anterior cruciate ligament reconstruction using the endobutton or toggleloc with ziploop as a femoral fixation device: A comparison of 1654 patients from the danish knee ligament reconstruction registry. *Orthop J Sports Med* 2018;6:2325967118778507.

12. Kim HS, Seon JK, Jo AR. Current trends in anterior cruciate ligament reconstruction. *Knee Surg Relat Res* 2013;25:165-73.

13. Plaweski S, Rossi J, Merloz P. Anterior cruciate ligament reconstruction: Assessment of the hamstring autograft femoral fixation using the EndoButton CL. *Orthop Traumatol Surg Res* 2009;95:606-13.

14. Kong CG, In Y, Kim GH, Ahn CY. Cross Pins versus endobutton femoral fixation in hamstring anterior cruciate ligament reconstruction: Minimum 4-year follow-up. *Knee Surg Relat Res* 2012;24:34-9.

**Conflict of Interest:** Nil

**Source of Support:** Nil

**Consent:** The authors confirm that informed consent was obtained from the patient for publication of this case report

#### How to Cite this Article

Shetty SB, Prabhakar PH, Kajava VP, Rao HK, Sarma LMK. Arthroscopic Reconstruction of Injured Anterior Cruciate Ligament Using Peroneus Longus Graft With Fixed Loop Endobutton – A Prospective Study. *Journal of Orthopaedic Case Reports* 2024 October;14(10):225-229.

