Case Report | Journal of Orthopaedic Case Reports 2022 August:12(8):Page 23-26

Novel Technique for the Management of Fibrous Dysplasia of Radius Shaft with Fibular Strut Autograft without Internal Fixation: A Case Report

Hemant Patankar[1], Devanshu Gupta[2], Zaid Memon[3], Fayaz Memon[4]

Learning Point of the Article:

Biological fixation using non-vascularised fibular strut graft in cases of fibrous dysplasia of radius is a novel technique with no recurrence.

Abstract

Introduction: Fibrous dysplasia (FD) is a developmental disorder in which the normal bone marrow is distorted and replaced by dense fibrous stroma containing a disorganized matrix. The disorder can be localized to a single bone or affect multiple bones. Although any bone can be affected, the bones of the upper extremity are the rare site of involvement. The disease process results in deformity of the bones and is often complicated by pathological fractures.

Case Report: Here, we present a case of a 14-year-old girl, who presented with FD of the radius bone with the progressive deformity with terminal restriction of supination and pronation. Radiographs showed revealed an expansile lytic lesion with ground glass appearance involving the proximal meta-diaphysis of the right radius, with its resultant bowin. Using Henry's approach, we treated with an innovative surgical approach envisioned with the non-vascularized cortical fibular bone graft without an internal fixation.

Conclusion: For the management of FD of radius bone, non-vascularized cortical fibular bone grafting provided if tightly fitted gives good radiological and functional outcome without any recurrence with complete osseointegration.

Keywords: Fibrous dysplasia, fibular strut autograft, radius bone.

Introduction

Fibrous dysplasia (FD) is a developmental anomaly where normal bone marrow is replaced by dense fibrotic tissue containing a disorganized matrix and characterized by immature woven bone spicules [1]. FD nearly accounts for 5–7% of benign bone tumors. Only a few numbers of isolated case reports of FD involving the radius bone have been documented to this point [1]. Surgical management is a challenge due to the wide clinical spectrum. Indications for surgery include non-union, persistent pain, and progressive deformity. Surgical options include curettage and bone grafting, open reduction, and internal fixation with vascularized bone grafting [2]. The majority of bone grafts, especially autografts, fail to incorporate and the lesion eventually returns to a dysplastic state [3]. We report a case of monostotic FD of radius bone of an adolescent female with progressive deformity managed with surgical excision and cortical strut bone grafting without internal fixation.

Case Report

A 14-year-old girl with the right dominant hand presented with gradually progressive deformity of the right forearm for the past 1 year associated with mild pain. There was no history of localized trauma or fever. Family history for similar deformities was absent. Local examination revealed a palpable thickening with

Access this article online

Website: www.jocr.co.in

DOI: 10.13107/jocr.2022.v12.i08.2950

Author's Photo Gallery


Dr. Hemant Patankar


Dr. Devanshu Gupta


Dr. Zaid Memon


Dr. Fayaz Memon

[1]Patankar's Hand and Limb Reconstruction Clinic, Chembur, Mumbai, Maharashtra, India,
[2]Department of Orthopaedics, Lokmanya Tilak Municipal Medical College (Sion hospital), Sion, Mumbai, Maharashtra, India,
[3]Department of Orthopaedics, MGM Medical Colleg and Hospital, Panvel, Navi Mumbai, 410209, India.
[4]Department of Orthopaedics, Grant Government Medical College and Sir J.J Hospital, Byculla, Mumbai, Maharashtra, India.

Address of Correspondence:
Dr. Devanshu Gupta,
Department of Orthopaedics, Lokmanya Tilak Municipal Medical College (Sion Hospital), Sion, Mumbai - 400 022, Maharashtra, India.
E-mail: devmittal2293@gmail.com

Submitted: 10/03/2022; Review: 20/05/2022; Accepted: July 2022; Published: August 2022

DOI:10.13107/jocr.2022.v12.i08.2950

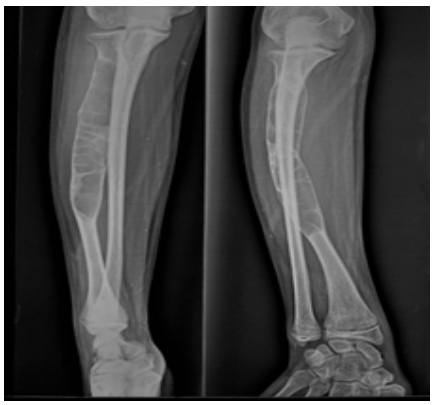

Figure 1: Skeletal radiograph (frontal and lateral views) showing an expansile lytic lesion with ground glass appearance involving the proximal meta-diaphysis of the right radius, with its resultant bowing.

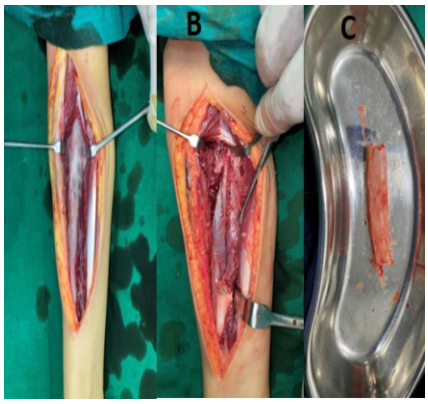

Figure 2: (a) Intraoperative image showing the radius bone (Henry's approach) and (b and c) excised lesion.

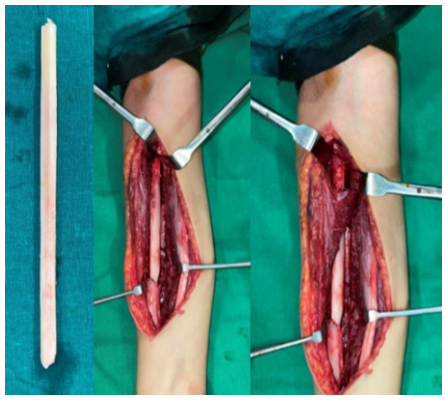

Figure 3: Intraoperative images with fibular cortical graft jammed in the defect.

deformity of the proximal two-thirds of the right radius. There was a restriction of terminal forearm pronation and supination. However, the function of the elbow and hand was unaffected. There was no evidence of distal neurovascular or tendon deficit. Skeletal radiographs (frontal and lateral view) of the right forearm revealed an expansile lytic lesion with ground glass appearance involving the proximal meta-diaphysis of the right radius, with its resultant bowing (Fig. 1). There was no sign of matrix calcification and the zone of transition was small. The lesion was causing thinning of the bony cortex. No obvious cortical breach, fracture, or periosteal reaction was noted. The overlying soft tissue was intact. A skeletal survey revealed no similar lesions elsewhere. With this radiographic appearance in mind, a provisional diagnosis of FD of the radius was put forth. The patient's symptoms and deformity warranted surgical intervention. In FD, cancellous bone (autograft) grafts undergo resorption and replacement with the same type of poorly formed woven bone, and thus recurrence occurs, which may lead to fracture and deformity. Hence, a different surgical approach was envisioned with the use of a non-vascularized cortical bone graft. The lesion in the radius was explored using Henry's approach [4], Intermuscular intervals being flexor carpi radialis and brachioradialis while internervous plane being median nerve and radial nerve. The proximal three-fourth of the radius bone was exposed and the lesion was excised along with 1 cm of normal bone on the distal side (Fig. 2). Proximally, a thin shell of the cortex was preserved after curettage of the proximal end of the radius and the specimen was sent for Histopathology to confirm the diagnosis. Fibular cortical strut graft was harvested from the leg of the same side. Graft length was kept 2 cm more than the excised bone to avoid shortening of the forearm. The graft was beveled on the distal end and jammed into the shaft of the distal radius such that 1 cm of the graft was inside the original bone (Fig. 3). Histopathology revealed a lesion comprising of trabeculae of immature woven bone having curvilinear branching appearance, embedded in a fibrous stroma. Post-operative radiographs were obtained and an above-elbow splint was applied to keep the elbow at 90° of flexion and the forearm in supination for a total of 6 months to allow for osseointegration and prevent any distal radioulnar joint discrepancy.

The patient was being followed up regularly. Follow-up radiographs (Fig. 4) obtained at 18 months revealed complete incorporation of the cortical bone graft with the reformation of the intramedullary bone canal and restoration of hand and elbow function with deformity being corrected (Fig. 5).

Discussion

Lichtenstein in 1938 used the term FD initially to designate a

Figure 4: Radiographs of the patient (18-month follow-up).

Figure 5: Clinical photos before and after the operation showing correction of deformity.

developmental anomaly of unknown etiology characterized by replacement of fibrous tissue of the medullary cavity of bones [5]. FD is mainly caused by activating mutations of alpha-subunit of Gs protein [2]. Any bone can be involved, depending on the form of the disease. FD can be monostotic, affecting only one bone, or polyostotic, affecting numerous bones [6]. Endocrine issues and McCune-Albright syndrome are linked to polyostotic FD. Radiographs help in making an early diagnosis of these cases and are also helpful in their subsequent follow-up. Classically, lesions of FD are intramedullary, expansile, and show varying degrees of hazy density giving a ground-glass appearance [6]. There is cortical thinning with bowing and deformity of the involved bones. Lesions of FD can be complicated by pathological fracture, development of secondary aneurysmal bone cyst, and rarely, malignant transformation to osteosarcoma, fibrosarcoma, chondrosarcoma, and malignant fibrohistiocytoma [7]. Depending on the patient's symptoms, management of FD might range from observation to surgical intervention. Asymptomatic lesions can be observed for progression. A progressive deformity, enlarged lesions with pain and functional loss, non-union, or malignant change are all indications for surgery in these cases [8]. Although small focal lesions can be treated with cancellous bone grafts and curettage, local recurrence remains a problem. The process of creeping substitution, depending on the local healing response of the bone, involves the resorption of the bone graft and newly formed host bone [3]. In FD, autologous cancellous bone grafts undergo resorption and replacement with the same type of poorly formed woven bone, and thus recurrence occurs, which may lead to fracture and deformity. Kokkalis et al. reported two cases of pathological fracture around the elbow due to FD being treated successfully with cancellous bone allograft after curettage. Both patients achieved excellent ROM and were pain-free without any recurrences [1]. The use of cortical strut grafts for the management of FD lesions has been cited in the literature [8]. Vascularized autologous cortical bone does not weaken as it does not undergo resorption. It is remodeled in a fashion similar to normal bone and is a superior graft compared to its non-vascularized counterpart [8]. According to one of the studies, FD and other benign lesions of the proximal femur can be treated safely and effectively with non-vascularized fibular cortical strut autografts [9]. In a study by Kumta et al., eight patients were treated for the upper limb FD with vascularized bone grafting [10].

Through this case report, we aim to describe an innovative approach to managing fibrous dysplastic lesion of radius bone using a non-vascularized fibular cortical strut graft. To the best of our knowledge, this has not been reported earlier, although fibular cortical strut graft has been used to treat fibrous dysplastic lesions of the proximal femur. We did not use any implant as we felt a tightly fitting cortical graft supported by external means would heal without displacement. Second, due to the short proximal fragment of the radius, no implant could provide any type of stability there. We admit that the distal end of the graft could have been stabilized by an intramedullary nail or a plate. Our technique thus avoided the use of an implant to fix the graft to the parent bone. It showed that a tightly fitted cortical graft is stable enough to incorporate with the original bone without deformation and pathological fracture, provided the forearm is protected till complete union is confirmed. No complication was observed postoperatively. The length of the forearm along with the range of motion was maintained including supination and pronation of the forearm. The hand and elbow function returned to the original pre-operative status.

Concusion

Non-vascularized fibular cortical strut grafting is an effective treatment modality for FD of the radius bone. External or internal fixation is not necessary if a tightly fitting cortical graft is jammed into the defect caused by lesion excision with complete osseointegration and no recurrence of FD.

Clinical Message

Monostotic FD of radius bone being a rare location can be effectively treated with complete excision of tumor and the bone defect can be managed by non-vascularized fibular cortical strut grafting without any internal or external fixation with no recurrence.

Declaration of patient consent: The authors certify that they have obtained all appropriate patient consent forms. In the form, the patient has given the consent for his/ her images and other clinical information to be reported in the journal. The patient understands that his/ her names and initials will not be published and due efforts will be made to conceal their identity, but anonymity cannot be guaranteed.

Conflict of interest: Nil **Source of support:** None

References

1. Kokkalis ZT, Jain S, Sotereanos DG. Fibrous dysplasia around the elbow. J Shoulder Elbow Surg 2010;19:e6-11.

2. DiCaprio MR, Enneking WF. Fibrous dysplasia. Pathophysiology, evaluation, and treatment. J Bone Joint Surg Am 2005;87:1848-64.

3. Leet AI, Boyce AM, Ibrahim KA, Wientroub S, Kushner H, Collins MT. Bone-grafting in polyostotic fibrous dysplasia. J Bone Joint Surg Am 2016;98:211-9.

4. Henry AK. Extensile Exposure. 2nd ed. New York: Churchill Livingstone; 1973.

5. Lichtenstein L. Polyostotic fibrous dysplasia. Arch Surg 1938;36:874-98.

6. Fitzpatrick KA, Taljanovic MS, Speer DP, Graham AR, Jacobson JA, Barnes GR, et al. Imaging findings of fibrous dysplasia with histopathologic and intraoperative correlation. Am J Roentgenol 2004;182:1389-98.

7. Kushchayeva YS, Kushchayev SV, Glushko TY, Tella SH, Teytelboym OM, Collins MT, et al Fibrous dysplasia for radiologists: Beyond ground glass bone matrix. Insights Imaging 2018;9:1035-56.

8. Burchardt H, Enneking WF. Transplantation of bone. Surg Clin North Am 1978;58:403-27.

9. George B, Abudu A, Grimer RJ, Carter SR, Tillman RM. The treatment of benign lesions of the proximal femur with non-vascularised autologous fibular strut grafts. J Bone Joint Surg Br 2008;90:648-51.

10. Kumta SM, Leung PC, Griffith JF, Kew J, Chow LT. Vascularised bone grafting for fibrous dysplasia of the upper limb. J Bone Joint Surg Br 2000;82:409-12.

Conflict of Interest: Nil
Source of Support: Nil

Content: The authors confirm that informed consent was obtained from the patient for publication of this case report

How to Cite this Article

Patankar H, Gupta D, Memon Z, Memon F. Novel Technique for the Management of Fibrous Dysplasia of Radius Shaft with Fibular Strut Autograft without Internal Fixation: A Case Report. Journal of Orthopaedic Case Reports 2022 August;12(8): 23-26.