

Atypical Presentation of MRSA Septic Arthritis with Concurrent Pyomyositis of the Calf Muscles in an Immunocompetent Adult

Sameer Tyagi¹, Dylan Goveas¹, Sanah Merchant², Russell Pinto³, Gurmeet Sawhney⁴

Learning Point of the Article:

Concurrent pyomyositis with septic arthritis can present without systemic symptoms. A high index of suspicion, early imaging, and interdisciplinary collaboration can dramatically improve outcomes.

Abstract

Introduction: Concurrent pyomyositis and septic arthritis without systemic symptoms is uncommon and may delay diagnosis.

Case Report: A 36-year-old immunocompetent male presented with isolated right knee swelling, without fever or trauma. Magnetic resonance imaging revealed joint effusion and myositis in surrounding muscles. Joint aspiration confirmed Methicillin-resistant *Staphylococcus aureus* septic arthritis. Despite intravenous antibiotics, a growing intramuscular abscess in the gastrocnemius was detected on serial ultrasound. Surgical drainage was performed. The patient was treated with IV vancomycin for 2 weeks, followed by oral linezolid, and recovered fully.

Conclusion: Pyomyositis should be considered in septic arthritis with atypical presentations. Serial imaging and inflammatory markers are essential for guiding treatment.

Keywords: Methicillin-resistant *Staphylococcus aureus*, septic arthritis, pyomyositis, gastrocnemius, vancomycin, C-reactive protein, immunocompetent, knee joint.

Introduction

Septic arthritis coexisting with pyomyositis is typically seen in immunocompromised individuals or tropical regions. However, such presentations in otherwise healthy patients, especially without systemic signs, such as fever, are rare. This case emphasizes the importance of considering muscle involvement in joint infections, even when classical symptoms are absent.

Pyomyositis, a primary bacterial infection of skeletal muscle, has traditionally been associated with tropical climates and immunocompromised states, such as HIV infection, diabetes mellitus, malignancy, or corticosteroid use [1,2]. However, recent literature suggests an increasing incidence of pyomyositis in immunocompetent individuals and in temperate regions [3-

6].

Staphylococcus aureus remains the most common causative organism, with methicillin-resistant strains methicillin-resistant *S. aureus* (MRSA) increasingly implicated in musculoskeletal infections [5,6]. The coexistence of pyomyositis with septic arthritis is uncommon and may occur due to contiguous spread or hematogenous dissemination [3].

Importantly, the diagnosis of pyomyositis is frequently delayed due to its insidious onset and non-specific clinical presentation, particularly in the absence of systemic symptoms, such as fever [7,8]. Advanced imaging, especially magnetic resonance imaging (MRI), plays a crucial role in early detection of muscle involvement, while ultrasound is valuable for identifying

Author's Photo Gallery



Dr. Sameer Tyagi



Dr. Dylan Goveas



Dr. Sanah Merchant



Dr. Russell Pinto



Dr. Gurmeet Sawhney

¹Department of Orthopedics, Holy Family Hospital, Mumbai, Maharashtra, India,

²Infectious Disease Unit, Holy Family Hospital, Mumbai, Maharashtra, India,

³Department of General Surgery, Holy Family Hospital, Mumbai, Maharashtra, India,

⁴Department of Microbiology, Holy Family Hospital, Mumbai, Maharashtra, India.

Address of Correspondence:

Dr. Sameer Tyagi,

Consultant Orthopedic Surgeon, Holy Family Hospital, Mumbai, Maharashtra, India.

E-mail: drsameertyagi@gmail.com

Access this article online

Website:
www.jocr.co.in

DOI:
<https://doi.org/10.13107/jocr.2026.v16.i07.7696>

Submitted: 06/04/2026; Review: 22/05/2026; Accepted: June 2026; Published: July 2026

DOI: <https://doi.org/10.13107/jocr.2026.v16.i07.7696>

© The Author(s). 2026 Open Access. This article is distributed under the terms of the Creative Commons Attribution 4.0 International License (<https://creativecommons.org/licenses/by-nc/4.0/>), which permits unrestricted use, distribution, and non-commercial reproduction in any medium, provided you give appropriate credit to the original author(s) and the source, provide a link to the Creative Commons license, and indicate if changes were made. The Creative Commons Public Domain Dedication waiver (<http://creativecommons.org/publicdomain/zero/1.0/>) applies to the data made available in this article, unless otherwise stated.

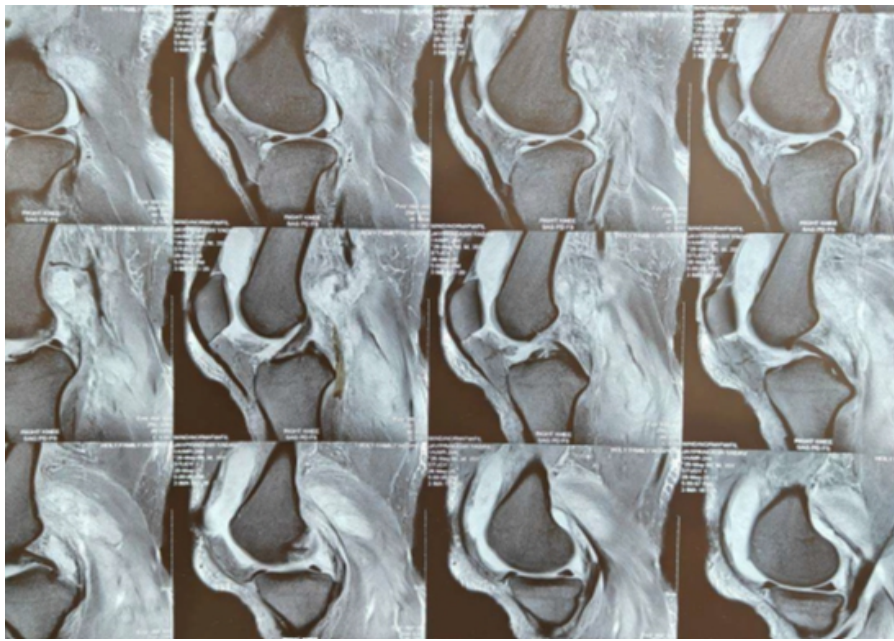


Figure 1: Magnetic resonance imaging (MRI) of the right knee (sagittal T2-weighted fat-suppressed image) showing moderate joint effusion with synovial enhancement and surrounding muscle edema suggestive of myositis. Usually, pyomyositis is diagnosed late, an immunocompetent individual presenting with only knee swelling, is likely to receive treatment for a few weeks before the infection spreads to other areas, one of the important points in this case was that the patient presented early to an orthopedic surgeon who ordered an MRI of the knee which also incidentally picked up the pus collections in the muscles making a diagnosis of pyomyositis.

evolving abscesses and guiding intervention [7].

Recent reports, including a case series by Shukla et al. [10], have demonstrated that pyomyositis can present in immunocompetent individuals without classical systemic features, further contributing to diagnostic challenges.

Case Report

A 36-year-old healthy male presented to the Orthopedic Unit at Holy Family Hospital, Mumbai, with a 4-day history of right knee swelling. He denied trauma, fever, or constitutional symptoms.

Clinical examination:

- Tense knee effusion
- Mild warmth
- Restricted flexion
- No systemic toxicity.

Timeline of events

- Day 1–4: Knee swelling without fever
- Day 4: MRI showed joint effusion with myositis (Fig. 1, 2, 3) ultrasound showed collection in gastrocnemius muscle

- Day 5: Joint aspiration → MRSA confirmed by culture (Fig. 4)
- Day 5–7: IV antibiotics switched to targeted antibiotics as per sensitivity (piperacillin-tazobactam → vancomycin)
- Day 8–10: C-reactive protein (CRP) plateau observed (Fig. 5)
- Day 10: Repeat ultrasonography → gastrocnemius collection increased instead of subsiding despite targeted antibiotics (Fig. 6,7)
- Day 11: Surgical incision and drainage performed, culture sent confirmed the bacteria in the intramuscular collection as isolated from the synovial fluid (Fig. 8)
- Post-operative: CRP decline and clinical improvement
- 4 weeks: Full recovery.

MRI findings

- Moderate right knee effusion
- Edema of vastus lateralis, medialis, and gastrocnemius

- Diagnosis: Septic arthritis with surrounding myositis.

Management and course

- Diagnostic aspiration: Purulent fluid
- Gram stain: Gram-positive cocci

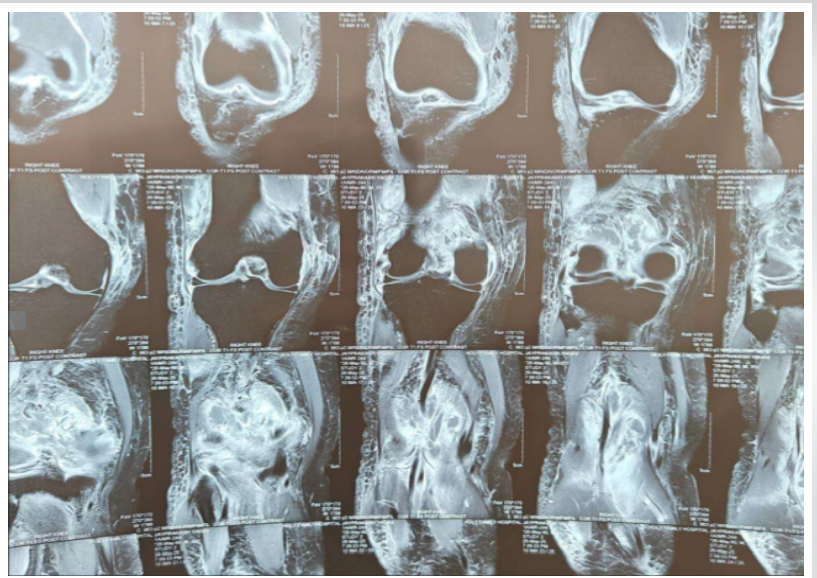


Figure 2: Coronal magnetic resonance imaging image of the knee showing intramuscular collections.

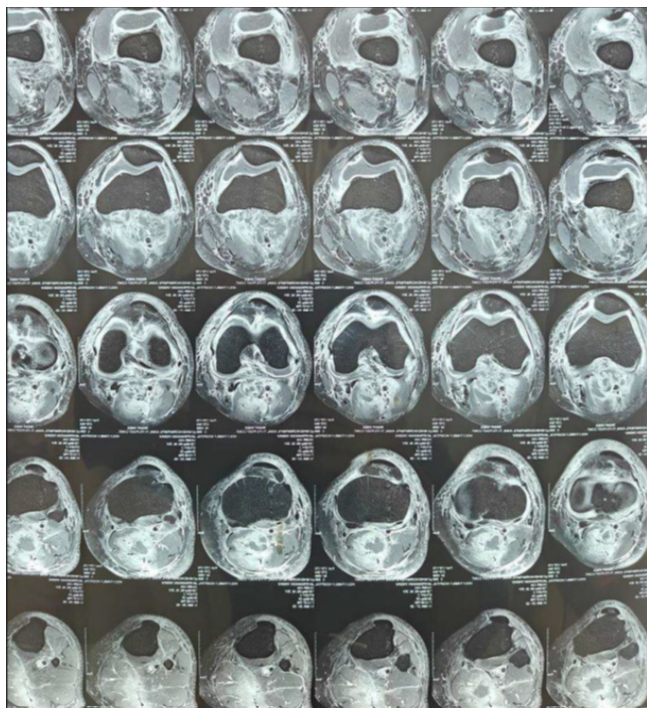


Figure 3: Magnetic resonance imaging axial T2-weighted image showing diffuse hyperintensity in the vastus lateralis, vastus medialis, and medial gastrocnemius muscles consistent with pyomyositis.

- Culture: MRSA
- Initial antibiotic: IV piperacillin-tazobactam, escalated to IV vancomycin post-sensitivity.

Despite initial improvement, CRP plateaued. Repeat ultrasound showed a growing collection in the medial gastrocnemius in spite of giving antibiotics as per sensitivity.

Surgical incision and drainage were performed. Necrotic tissue was debrided. Pus culture again confirmed MRSA.

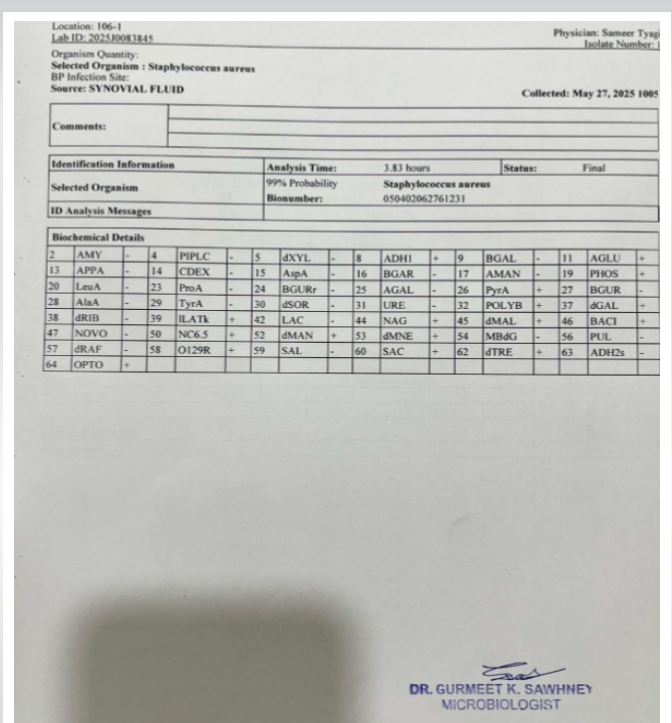


Figure 4: Knee was aspirated and synovial fluid sent for culture, which led to identification of Methicillin-resistant Staphylococcus aureus (culture report attached below). Injection of vancomycin was started for this; however, C-reactive protein and total leukocyte count values did not decrease, which led to the decision of incision and drainage. Culture Vitech identification (99% probability) and sensitivity reports with mic values of synovial fluid and pus.

Post-operative care

- CRP declined steadily
- Switched to oral linezolid after 2 weeks of IV vancomycin
- Wound managed with regular dressings
- At 4-week follow-up, the patient had full knee mobility with no signs of recurrence.

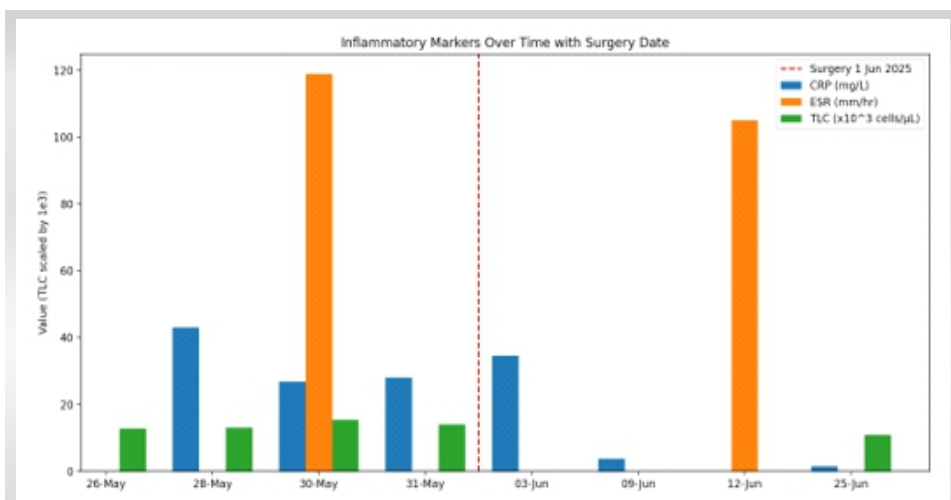


Figure 5: Trend of inflammatory markers (C-reactive protein [CRP], erythrocyte sedimentation rate, total leukocyte count [TLC]) over time in relation to surgery date (1 June 2025). Serial evaluation of Inflammatory markers and TLC shows raised values even after targeted antibiotic therapy. The CRP plateau prompted repeat ultrasound and surgical drainage, followed by steady post-operative decline.

Literature review

Pyomyositis, originally regarded as a tropical disease, is now being increasingly reported in temperate regions and among varied populations. It is traditionally associated with immunocompromised states – particularly HIV/AIDS, diabetes mellitus, malignancies, or corticosteroid use. A review by Crum [1] (2008) noted that over 90% of adult pyomyositis cases occurred in patients with identifiable immune compromise.

However, reports in immunocompetent individuals remain rare. Pediatric series by Chauhan et al. [2] and a small number



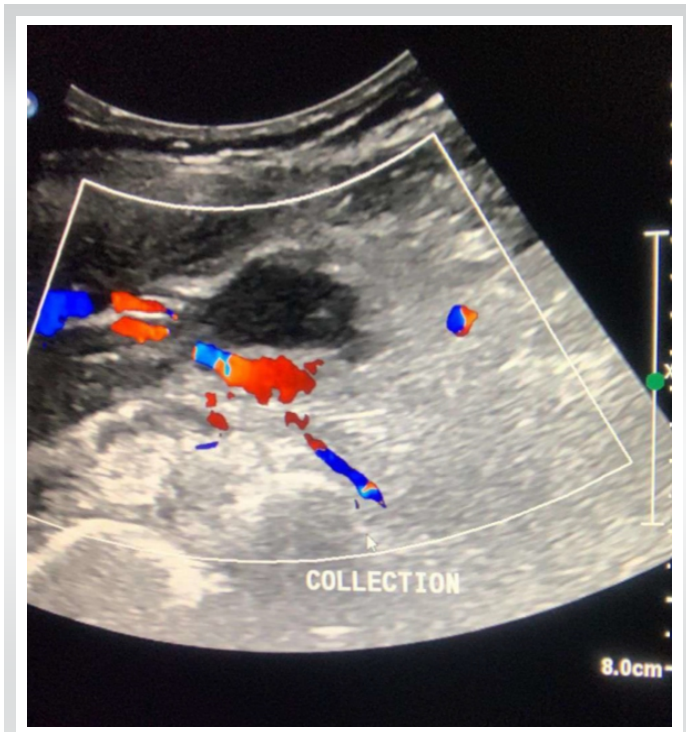


Figure 6: First ultrasound of gastrocnemius collection 27 May 2025. Ultrasound image with color Doppler showing anechoic intramuscular collection with internal echoes and peripheral vascularity in the medial gastrocnemius muscle (27 May 2025).

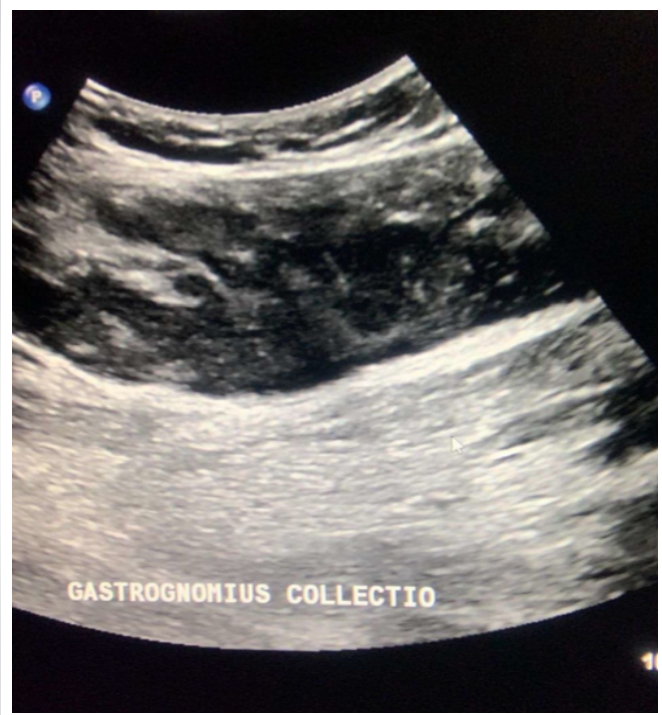

Figure 7: Repeat ultrasound showing increased size (instead of expected decrease) of the medial gastrocnemius collection despite ongoing IV vancomycin therapy (31 May 2025) which prompted surgical drainage.

of adult case reports have described pyomyositis in otherwise healthy individuals, but often with atypical locations or delayed presentation. Recent case series by Shukla et al. [10] also highlight similar atypical presentations in immunocompetent patients, supporting our findings.

In addition, literature often emphasizes delayed diagnosis, with symptoms evolving over 1–3 weeks before imaging or intervention is performed. This delay is often due to vague initial symptoms or deep muscle involvement not easily visible on examination.

In contrast, our patient was immunocompetent and had no underlying systemic illness. The presence of knee joint swelling prompted early MRI, which revealed both the joint effusion and surrounding muscle edema – enabling early diagnosis and timely management [3,4,7,8,9].

Discussion

MRSA septic arthritis may present atypically in immunocompetent individuals. The absence of fever can mislead diagnosis. While initial MRI showed only myositis, progression to abscess necessitated close monitoring with inflammatory markers and imaging. Serial CRP and ultrasound helped guide timely surgical intervention. Targeted antimicrobial therapy and aggressive wound care contributed to a successful outcome.

Organism Quantity: Selected Organism : Staphylococcus aureus (MRSA)
 BP Infection Site: Source: Pus (SURGICAL SITE) Collected: Jun 1, 2025 1049

Comments: F/35

Susceptibility Information		Analysis Time: 13.15 hours	Status: Final		
Antimicrobial	MIC	Interpretation	Antimicrobial	MIC	Interpretation
Cefoxitin Screen	POS	+	Clindamycin	>= 4	R
Benzylpenicillin	>= 0.5	R	Linezolid	4	S
+Piperacillin		R	Daptomycin	0.5	S
+Piperacillin/Tazobactam		R	Teicoplanin	<= 0.5	S
+Methicillin		R	Vancomycin	<= 0.5	S
Oxacillin	>= 4	R	+Minocycline		S
+Meropenem		R	Tetracycline	<= 1	S
Gentamicin	<= 0.5	S	Tigecycline	<= 0.12	S
Ciprofloxacin	>= 8	R	Rifampicin	<= 0.03	S
Levofloxacin	4	R	Trimethoprim/Sulfamethoxazole	80	R
Erythromycin	<= 0.25	S			

AES Findings

Confidence: Consistent

DR. GURMEET K. SAWHNEY
 MICROBIOLOGIST

Figure 8: Culture report from the intramuscular collection at the time of incision and drainage shows the same Methicillin-resistant Staphylococcus aureus (MRSA) organism isolated from the synovial fluid. After the incision and drainage, patient’s condition improved rapidly. VITEK-2 identification and antimicrobial susceptibility profile of S. aureus (MRSA) isolate from intramuscular pus showing resistance to methicillin and sensitivity to vancomycin and linezolid.



In contrast, our case demonstrates that early imaging combined with CRP monitoring can enable timely intervention. The plateau in CRP was a key indicator prompting repeat imaging.

Although pyomyositis may coexist with septic arthritis, such concurrent presentations remain uncommon [3]. Our case is distinct in demonstrating both conditions without systemic symptoms.

Recent case series by Shukla et al. [10] also highlight similar atypical presentations in immunocompetent patients, supporting our findings

An important aspect of this case was the use of interdisciplinary collaboration facilitated through a digital medium. Upon diagnosis, a dedicated WhatsApp group was created involving the orthopedic team, microbiologist, general surgeon, and infectious disease specialist. This real-time communication channel allowed all involved clinicians to remain updated, share inputs promptly, and make joint decisions regarding antibiotic escalation, need for surgical intervention, and discharge planning.

This approach not only enhanced clinical coordination but also reduced delays in care, especially in the evolving phase of the

patient's condition. It underscores the growing value of digital communication platforms in streamlining multidisciplinary care, particularly in acute infections where timely action is critical.

Conclusion

Clinicians should consider evolving pyomyositis in septic arthritis cases with persistent inflammatory markers or atypical imaging findings. Early culture-guided antibiotics, close surveillance, and surgical drainage when needed are crucial for recovery.

Clinical Message

In patients with septic arthritis and persistent inflammation or atypical imaging findings, pyomyositis should be considered – even in immunocompetent individuals. Early MRI and serial inflammatory markers are key to timely diagnosis and intervention. Targeted antibiotic therapy may not be enough and surgical evacuation of the abscesses may be required in addition to IV antibiotics.

Declaration of patient consent: The authors certify that they have obtained all appropriate patient consent forms. In the form, the patient has given the consent for his/ her images and other clinical information to be reported in the journal. The patient understands that his/ her names and initials will not be published and due efforts will be made to conceal their identity, but anonymity cannot be guaranteed.

Conflict of interest: Nil **Source of support:** None

References

1. Crum NF. Bacterial pyomyositis in the United States. *Am J Med* 2008;121:486-91.
2. Chauhan S, Jain S, Varma S, Chauhan SS. Tropical pyomyositis (myositis tropicans): Current perspective. *Postgrad Med J* 2004;80:267-70.
3. Gubbay AJ, Isaacs D. Pyomyositis in children. *Pediatr Infect Dis J* 2000;19:1009-12; quiz 1013.
4. King RJ, Laugharne D, Kerslake RW. Pyomyositis-a tropical disease in a temperate climate. *Ann R Coll Surg Engl* 2003;85:333-4.
5. Menezes GA, Harish BN, Sujatha S, Vinothini K, Parija SC. MRSA in India: Prevalence & susceptibility pattern. *Indian J Med Res* 2008;127:212-5.
6. Mathews CJ, Weston VC, Jones A, Field M, Coakley G. Bacterial septic arthritis in adults. *Lancet* 2010;375:846-55.
7. Lee YJ, Sadigh S, Mankad K, Kapse N, Rajeswaran G. The imaging of pyomyositis: A pictorial review. *Insights Imaging* 2018;9:753-62.
8. Kumar N, Menon A, Gopinathan NR. Pyomyositis of the lower limb muscles: Clinical features and management of 40 cases in a tertiary care center. *Indian J Orthop* 2014;48:297-302.
9. Mehta Y, Gupta A. Role of digital tools like WhatsApp in multidisciplinary clinical decision making: Boon or risk? *Indian J Crit Care Med* 2019;23:333-4.
10. Shukla RV, Dubey IP, Kumar A, Kompella K, Khan S, Mohanan K, et al. Tropical pyomyositis in immunocompetent hosts posing diagnostic challenges: A case series. *J Mar Med Soc* 2024;26:127-31.

Conflict of Interest: Nil

Source of Support: Nil

Consent: The authors confirm that informed consent was obtained from the patient for publication of this article

How to Cite this Article

Tyagi S, Goveas D, Merchant S, Pinto R, Sawhney G. Atypical Presentation of MRSA Septic Arthritis with Concurrent Pyomyositis of the Calf Muscles in an Immunocompetent Adult. *Journal of Orthopaedic Case Reports* 2026 July;16(07): 378-382.

