

Failure of Total Hip Arthroplasty due to Delamination and Wear of Titanium Nitride-coated Titanium Heads: A Case Series

Nils Wirries¹, Robert Egon Becker², Michael Skutek¹

Learning Point of the Article:

Titanium nitride-coated titanium alloy heads contributed to early failure of THA due to osteolysis and implant loosening.

Abstract

Introduction: We present the case studies of three patients requiring revision for premature failure of total hip arthroplasty (THA).

Case Report: All patients received titanium nitride (TiN)-coated heads made of titanium alloy TiALV as part of their index total hip replacements. At the time of revision surgery, intraoperative findings included partial or complete delamination of the TiN head coating and wear/deformation of the TiALV heads.

Conclusion: In addition to PE wear as a known mechanism for THA failure, titanium wear appears to play a major role in contributing to early THA failure and acceleration of PE wear. As a result, the choice of TiN-coated TiALV heads for use in THA should be approached with caution. It is thought that manufacturers of hip implants are aware of this potential problem. However, in a global community, this paper simply aims to bring this knowledge to general attention, while the manufacture of the presented heads does not exist anymore.

Keywords: Total hip arthroplasty, wear, titanium head, revision.

Introduction

Total hip arthroplasty (THA) is an operation with documented excellent long-term survivorship combined with equally good patient outcomes and significant improvements in quality of life [1,2]. History, however, is also littered with failures in THA related to the quest for improvement in prosthetic longevity. In a simulator study by Gutmanas and Gotman, titanium nitride (TiN)-coated heads showed minimized wear rates without a hint of delamination after 4×10^6 cycles [3]. TiN-coated heads are made of titanium alloy TiALV. It is a chemical composition made of titanium, 6% aluminum, and 4% vanadium and is commonly used in orthopedic implants. In the meanwhile, these TiN-coated heads were mainly no longer produced. Successful THA

requires excellent surgical technique in combination with a choice of implants that have favorable long-term survivorship.

We present the case studies of three patients who had premature failure of THA from osteolysis caused by aseptic loosening and periprosthetic fracture. TiN-coated heads made of titanium alloy were implanted in all three patients. In line with significant PE wear, clinical findings and features of this titanium alloy implant failure are presented, and possible mechanisms for failure are discussed.

Case Reports

Three patients (Fig. 1) initially received an uncemented titanium

Access this article online

Website:
www.jocr.co.in

DOI:
<https://doi.org/10.13107/jocr.2024.v14.i01.4138>

Author's Photo Gallery



Dr. Nils Wirries



Dr. Robert Egon Becker



Dr. Michael Skutek

¹Department of Joint Replacement, Diakovere Annastift Hannover, Hannover, Germany,

²Department of Medical Education – Neurology and Psychology, Indian River State College, 3209 Virginia Avenue, Fort Pierce, Florida.

Address of Correspondence:

Dr. Nils Wirries,

Department of Joint Replacement, Diakovere Annastift Hannover, Hannover, Germany.

E-mail: nils.wirries@diakovere.de

Submitted: 12/10/2023; Review: 25/11/2023; Accepted: December 2023; Published: January 2024

DOI: <https://doi.org/10.13107/jocr.2024.v14.i01.4138>

This is an open access journal, and articles are distributed under the terms of the Creative Commons Attribution-NonCommercial-ShareAlike 4.0 License <https://creativecommons.org/licenses/by-nc-sa/4.0/>, which allows others to remix, tweak, and build upon the work non-commercially, as long as appropriate credit is given and the new creations are licensed under the identical terms



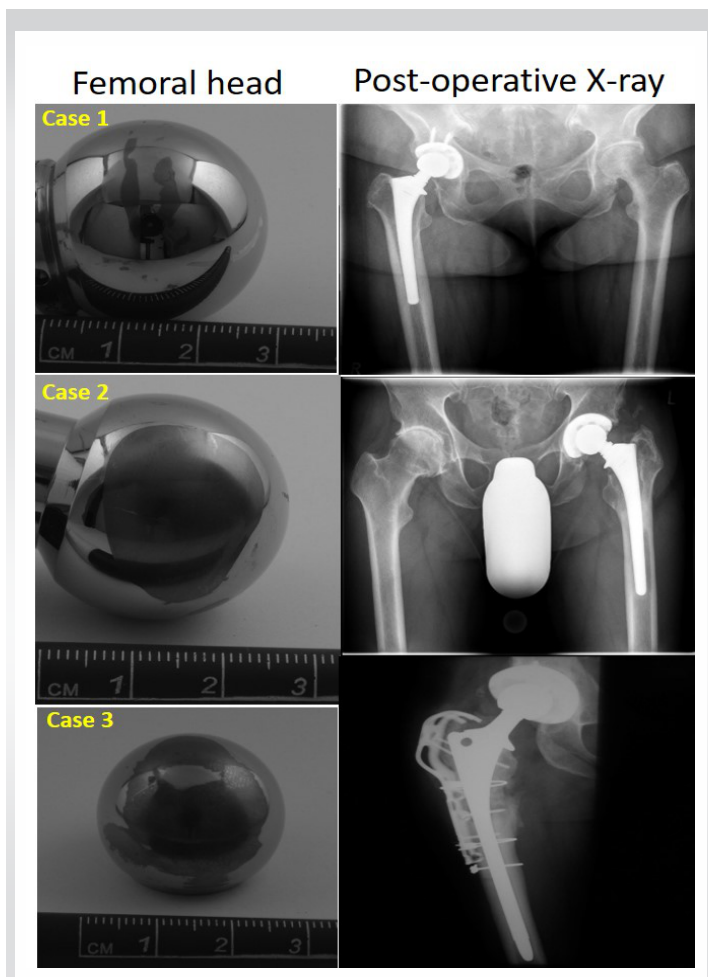


Figure 1: TiALV heads of all cases with defect sizes range from 0.5 cm² (1) to 5.75 cm² (3; monochrome images). Further, post-operative images of all cases: Cases 1 and 2 received a cup revision, Case 3 an exchange of all components.

stem, a titanium threaded cup with an inclination between 40 and 45°, standard ultra-high-molecular-weight-polyethylene inlays, and a 28 (n = 1) or 32 mm (n = 2) TiN-coated head. In all cases, the acetabular component was to be revised due to definite aseptic loosening (Pinnacle® cup: Sector II n = 2, Multihole n = 1). Marathon® liners and Articul/eze® (CoCr; Arge) heads were used in all instances for revision, except for Case 3.

Case 1 (female, 76 years) has had minimal osteolysis around the proximal stem with no loosening, and thus, the femoral implant was retained. The initial diagnosis for THA was primary osteoarthritis. The revision-free interval was 9.5 years (07/00–01/10).

Case 2 (male, 56 years) has had femoral osteolysis Type II (Paprosky) of the well-fixed stem 10.9 years (06/01–05/12) after THA due mild dysplasia and was treated with bone grafting of the proximal defects (15 cm³).

Case 3 (male, 47 years) has had more extensive osteolysis affecting the ischium and pubis (type IIIa), Fig. 1a) with severe metallosis and sander marks on the head's surface. Metal wear was seen in the histologic samples. Extensive bone grafting of the defects in the ischium (12 cm³) and pubis (8 cm³) was necessary. The stem was clinically loose at surgery and was revised using a solution stem (DePuy) through an extended trochanteric osteotomy, plus a trochanteric grip plate due to refixation of periprosthetic trochanteric fracture (Trofix®, Zimmer, Fig. 1b). The primary surgery was 10.0 years ago (01/02–12/11).

Retrieved implants demonstrated significant volumetric wear of the liner (up to 2.84 cm³) with either partial or complete loss of the TiN coating and volumetric wear of the TiALV-heads. In all three cases, the TiN coating was delaminated to varying but significant extents. No backside wear or liner damage was noted. Measurements were done by three independent blinded assessors and averaged. An electronic digital caliper (digiMax, Swiss Precision Instruments, Inc.,) was used. The damaged femoral head coating ranged 0.5 cm² (elderly patient) to 5.75 cm² (two younger patients, Fig. 1). The two younger patients also had a defect of the TiALV head itself. All defects were palpable. The head diameter was reduced by 0.19 mm (32 mm head) and 0.18 mm (28 mm head). Histologically, a range of mild to severe metallosis was found in three cases in addition to wear-induced tenosynovitis [4, 5]. All patients suffered from mainly load depending hip pain without neurological symptoms.

Discussion

Osteolysis and component loosening following total hip replacement remains to be a major clinical issue. Example of increased volumetric wear and early failure has resulted from attempts to introduce new technologies aimed to decrease wear and improve longevity. Our study documents early prosthetic loosening related to the use of TiN-coated TiALV heads. We could not identify other failure-related factors. All cases received their primary THA due to primary osteoarthritis or mild dysplasia of the hip. Thus, severe and complex deformity was not present in the primary setting that might have influenced the time to loosening. In all settings, no septic condition was present. A probably approach-related impact on the implant loosening and dislocations was observed with cemented stem components in the Swedish Hip Arthroplasty Register [6]. However, all the presented cases were treated with cementless stems. Although prosthetic wear is to be expected, especially in active and high demand patients [7], failure of implants around 10 years should be considered as early failure. Moreover, massive osteolysis and titanium-related metallosis may lead to major problems technical difficulties during

revision procedures. Bone grafting and complete removal of PE and titanium debris are required in these instances. Titanium alloy particles have been implicated as a cause of significant periprosthetic reactions and osteolysis leading to premature prosthetic failure and early revision [8-12]. Recent laboratory studies support a major role of titanium wear particles in implant failure, and this is born out clinically in the cases we have seen. Cytological examination of the areas surrounding failed implants has indicated an increase in the bone-resorption-inducing cytokine, interleukin 1 β (IL-1 β), due to activation of the NALP3 inflammasome, which leads to increased IL-1 β secretion and IL-1-associated signaling, including neutrophil recruitment [13]. Further, titanium wear may cause neurological symptoms due to oxidative stress reactions and mitochondrial process changes (in vitro) [14]. However, within our case series, non-neurological disorder could be observed.

Conclusion

TiN-coated TiALV heads contributed to early failure of THA

Declaration of patient consent: The authors certify that they have obtained all appropriate patient consent forms. In the form, the patient has given the consent for his/ her images and other clinical information to be reported in the journal. The patient understands that his/ her names and initials will not be published and due efforts will be made to conceal their identity, but anonymity cannot be guaranteed.

Conflict of interest: Nil **Source of support:** None

References

- 1 Mariconda M, Galasso O, Costa GG, Recano P, Cerbasi S. Quality of life and functionality after total hip arthroplasty: A long-term follow-up study. *BMC Musculoskelet Disord* 2011;12:222.
- 2 Knight SR, Aujla R, Biswas SP. Total hip arthroplasty - over 100 years of operative history. *Orthop Rev (Pavia)* 2011;3:e16.
- 3 Gutmanas EY, Gotman I. PIRAC Ti nitride coated Ti-6Al-4V head against UHMWPE acetabular cup-hip wear simulator study. *J Mater Sci Mater Med* 2004;15:327-30.
- 4 Krenn V, Morawietz L, Haupl T, Neidel J, Petersen I, König A. Grading of chronic synovitis--a histopathological grading system for molecular and diagnostic pathology. *Pathol Res Pract* 2002;198:317-25.
- 5 Krenn V, Otto M, Morawietz L, Hopf T, Jakobs M, Klauser W, et al. Histopathologic diagnostics in endoprosthetics: Periprosthetic neosynovialitis, hypersensitivity reaction, and arthrofibrosis. *Orthopade* 2009;38:520-30.
- 6 Lindgren V, Garellick G, Karrholm J, Wretenberg P. The type of surgical approach influences the risk of revision in total hip arthroplasty: A study from the Swedish Hip arthroplasty register of 90,662 total hip replacements with 3 different cemented prostheses. *Acta Orthop* 2012;83:559-65.
- 7 Wangen H, Lereim P, Holm I, Gunderson R, Reikerås O. Hip arthroplasty in patients younger than 30 years: Excellent ten to 16-year follow-up results with a HA-coated stem. *Int Orthop* 2008;32:203-8.
- 8 Baumann B, Seufert J, Rolf O, Jakob F, Goebel S, Eulert J, et al. Upregulation of LITAF mRNA expression upon exposure to TiAlV and polyethylene wear particles in THP-1 macrophages. *Biomed Tech (Berl)* 2007;52:200-7.
- 9 Agins HJ, Alcock NW, Bansal M, Salvati EA, Wilson PD Jr., Pellicci PM, et al. Metallic wear in failed titanium-alloy total hip replacements. A histological and quantitative analysis. *J Bone Joint Surg Am* 1988;70:347-56.
- 10 Jakobsen SS, Larsen A, Stoltenberg M, Bruun JM, Soballe K. Effects of as-cast and wrought cobalt-chrome-molybdenum

Clinical Message

We recommend caution in the choice of titanium-coated femoral heads as these have caused significant clinical problems in our experience. Although these TiN-coated heads that were used in the presented failure cases are no longer available, it seems important to bring the knowledge and possible mechanisms of failure to global attention both for developers of hip implants and users.

and titanium-aluminium-vanadium alloys on cytokine gene expression and protein secretion in J774A.1 macrophages. *Eur Cell Mater* 2007;14:45-54; discussion 54-5.

11 Manlapaz M, Maloney WJ, Smith RL. In vitro activation of human fibroblasts by retrieved titanium alloy wear debris. *J Orthop Res* 1996;14:465-72.

12 Mostardi RA, Kovacic MW, Ramsier RD, Bender ET, Finefrock JM, Bear TF, et al. A comparison of the effects of prosthetic and commercially pure metals on retrieved human fibroblasts: the role of surface elemental composition. *Acta*

Biomater 2010;6:702-7.

13 St Pierre CA, Chan M, Iwakura Y, Ayers DC, Kurt-Jones EA, Finberg RW. Periprosthetic osteolysis: Characterizing the innate immune response to titanium wear-particles. *J Orthop Res* 2010;28:1418-24.

14 Huerta-Garcia E, Perez-Arizti JA, Marquez-Ramirez SG, Delgado-Buenrostro NL, Chirino YI, Iglesias GG, et al. Titanium dioxide nanoparticles induce strong oxidative stress and mitochondrial damage in glial cells. *Free Radic Biol Med* 2014;73:84-94.

Conflict of Interest: Nil

Source of Support: Nil

Consent: The authors confirm that informed consent was obtained from the patient for publication of this case report

How to Cite this Article

Wirries N, Becker RE, Skutek M. Failure of Total Hip Arthroplasty due to Delamination and Wear of Titanium Nitride-coated Titanium Heads: A Case Series. *Journal of Orthopaedic Case Reports* 2024 January;14(1): 36-39.