

Atypical Bilateral Cystic Foot Swellings with Osteomyelitis-Like Features: A Diagnostic Dilemma

S Nirmal¹, Harish Kiran¹, R V Raghav¹, B Aditya¹, M Mohan Kumar¹

Learning Point of the Article:

Chronic non-infective osteomyelitis should be considered in immunocompromised patients presenting with bilateral multifocal cystic foot swellings, osteomyelitis-like MRI features, and persistently sterile microbiological studies.

Abstract

Introduction: We report an unusual case of bilateral multiloculated cystic foot swellings in which extensive investigations failed to establish a definitive diagnosis, highlighting the challenges in distinguishing culture-negative infectious osteomyelitis from chronic non-infective osteomyelitis. Chronic osteomyelitis typically presents with localized infection and an identifiable microbiological etiology. However, atypical presentations with bilateral involvement and sterile cultures pose significant diagnostic challenges, especially in immunocompromised individuals.

Case Report: A 56-year-old female presented with multiple bilateral foot swellings of 2 years duration, associated with pain. Clinical examination revealed well-defined cystic, fluctuant swellings without classical signs of infection. Magnetic resonance imaging (MRI) demonstrated multiloculated fluid collections with sinus tracts and adjacent bony involvement suggestive of chronic osteomyelitis. Despite aspiration and biopsy, microbiological studies remained negative. Histopathology revealed acute on chronic inflammatory granulation tissue. The patient had significant comorbidities, including diabetes mellitus, rheumatoid arthritis, and prolonged steroid use.

Conclusion: Although MRI findings were highly suggestive of chronic osteomyelitis, persistently negative microbiological studies and non-specific histopathology precluded definitive confirmation of infection. After extensive multidisciplinary evaluation, chronic non-infective osteomyelitis emerged as the most plausible diagnosis. This case represents a significant diagnostic dilemma.

Keywords: Chronic osteomyelitis, culture-negative, bilateral foot swelling, magnetic resonance imaging, steroid misuse, diagnostic dilemma.

Introduction

Chronic osteomyelitis is a persistent infection of bone characterized by necrosis, sequestrum formation, and chronic inflammatory changes. It is most commonly caused by bacterial pathogens; however, a subset of patients present with culture-negative osteomyelitis, complicating diagnosis and management [1,2]. Bilateral involvement of the foot is uncommon and may mimic benign cystic lesions, inflammatory arthropathies, or neoplastic conditions [3]. Furthermore, immunocompromised states such as diabetes, autoimmune diseases, and prolonged corticosteroid use can alter disease presentation and obscure classical clinical features [4].

We report a rare case of bilateral multiloculated cystic foot swellings with radiological features suggestive of osteomyelitis but persistently negative

microbiological findings, highlighting the diagnostic dilemma and importance of clinico-radiological correlation.

Case Report

A 56-year-old female presented with complaints of multiple swellings over both feet for 2 years, associated with pain for the past 1 year. Swelling initially appeared in the left foot and gradually progressed to involve both feet with multiple swellings over a period of 4 years. The pain was insidious in onset, pricking and burning in nature, gradually progressive, aggravated by walking and standing, and relieved with medications. There was no associated history of fever, discharge, sinus formation, trauma, or thorn prick. No history of barefoot walking. She had a history of prolonged unsupervised steroid intake for pain relief. She was a known case of diabetes mellitus, systemic hypertension, and

Author's Photo Gallery



Dr. S Nirmal



Dr. Harish Kiran



Dr. R V Raghav



Dr. B Aditya



Dr. M Mohan Kumar

¹Department of Orthopaedic Surgery, Sri Ramachandra Institute of Higher Education and Research, Chennai, Tamil Nadu, India.

Address of Correspondence:

Dr. Harish Kiran,
Department of Orthopaedic Surgery, Sri Ramachandra Institute of Higher Education and research, Chennai, Tamil Nadu, India.
E-mail: harishkiran.2694@gmail.com

Access this article online

Website:
www.jocr.co.in

DOI:
<https://doi.org/10.13107/jocr.2026.v16.i06.7532>

Submitted: 07/03/2026; Review: 13/04/2026; Accepted: May 2026; Published: June 2026

DOI: <https://doi.org/10.13107/jocr.2026.v16.i06.7532>

© The Author(s). 2026 Open Access. This article is distributed under the terms of the Creative Commons Attribution 4.0 International License (<https://creativecommons.org/licenses/by-nc/4.0/>), which permits unrestricted use, distribution, and non-commercial reproduction in any medium, provided you give appropriate credit to the original author(s) and the source, provide a link to the Creative Commons license, and indicate if changes were made. The Creative Commons Public Domain Dedication waiver (<http://creativecommons.org/publicdomain/zero/1.0/>) applies to the data made available in this article, unless otherwise stated.

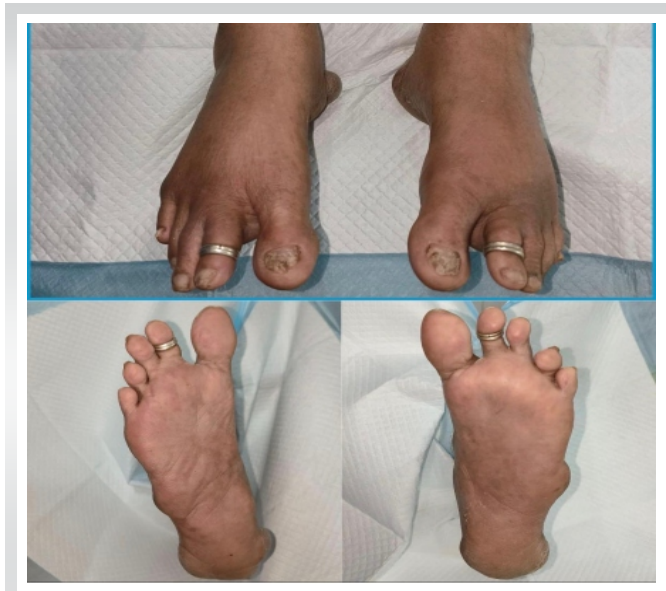

Figure 1: Clinical image showing multiple soft tissue swellings involving the dorsal and plantar aspects of bilateral feet.

rheumatoid arthritis.

On clinical examination, she had multiple globular swellings were present over the dorsoplantar junction of both feet. The swellings were well-defined, cystic, fluctuant, and non-mobile. There was no local warmth, erythema, or discharge. Mild tenderness was noted. Ankle range of motion was full and

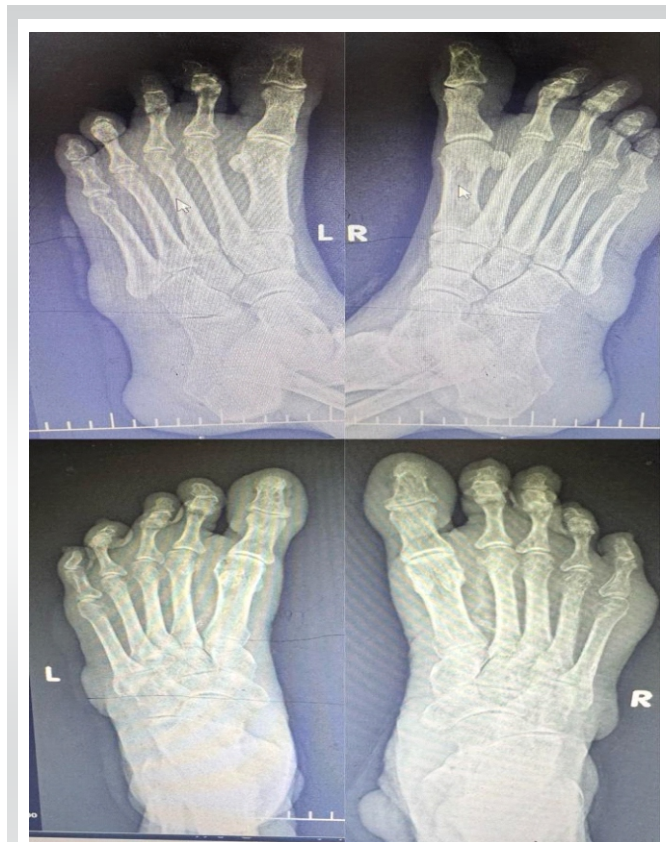

Figure 3: Plain radiographs of both feet showing no obvious bony abnormalities, with soft tissue prominence along the borders corresponding to clinically evident swellings and no evidence of calcification.

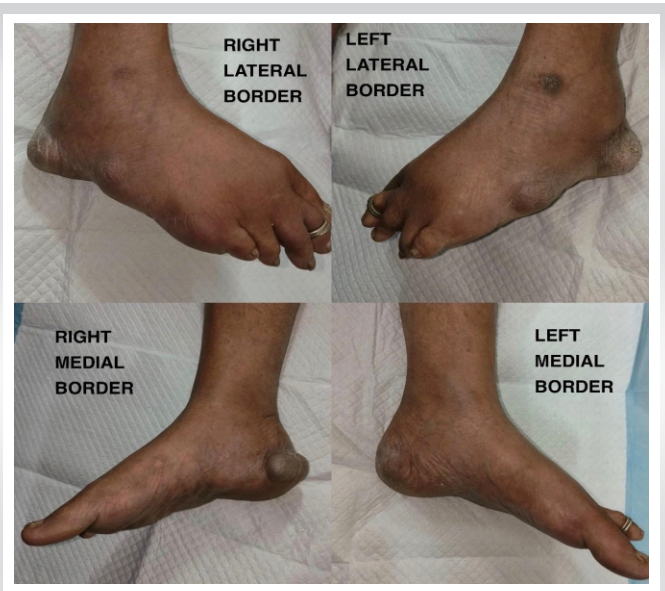


Figure 2: Clinical images showing multiple soft tissue swellings involving the medial and lateral borders of both feet, highlighting the extent and distribution of lesions

painless. Toe movements were preserved. No distal neurovascular deficit was present.

Laboratory findings were a normal total leukocyte count (8860) with elevated erythrocyte sedimentation rate (88 mm/h) and C-reactive protein (2.4 mg/L). Radiological showed no significant bony abnormality but showed multiple soft-tissue shadows along the plane of swelling.

Magnetic resonance imaging (MRI) of the right foot revealed multiloculated thick-walled fluid collections in the plantar aspect of the hindfoot with multiple branching sinus tracts extending along subcutaneous and intermuscular planes. Cortical breach with marrow edema was noted in the cuboid, with extension to adjacent bones, including the base of the fifth metatarsal and calcaneum. Extensive surrounding soft-tissue edema was present. These findings were suggestive of chronic infective etiology with osteomyelitis.

Procedures

Initially, aspiration of a single swelling over the right foot was done, which had approximately 20 mL of straw-colored fluid was aspirated. Culture showed no growth. Notably, swelling reaccumulated within 24 h after aspiration.

Later, we did an open biopsy of swelling over the right foot, which revealed occasional pus cells without identifiable organisms in gram stain and negative for bacterial culture, fungal culture, acid-fast bacilli, GeneXpert, and potassium hydroxide (KOH) mount.

Histopathology revealed acute on chronic inflammatory granulation tissue composed of neutrophils, lymphocytes, vascular proliferation, and pigment-laden macrophages, suggestive of chronic inflammatory pathology.

Detailed evaluation by rheumatology and dermatology specialists did not reveal evidence of active systemic inflammatory disease, extra-articular rheumatoid manifestations, or cutaneous lesions suggestive of alternative diagnoses.

The patient was treated with empirical broad-spectrum antibiotics and followed for six months. During follow-up, she reported a gradual reduction in pain and swelling, with no development of new lesions.

Discussion

Chronic osteomyelitis is traditionally regarded as an infective condition;

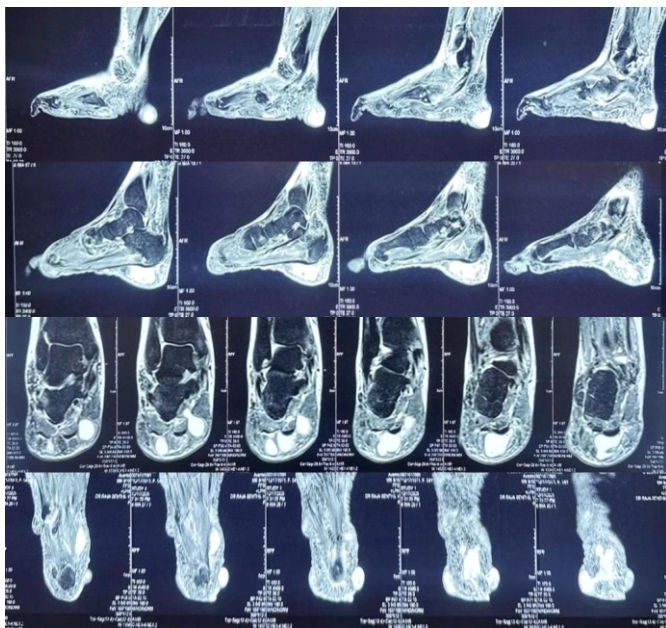


Figure 4: Selected MRI sections of the right foot demonstrating multiloculated fluid collections in the plantar hindfoot with multiple sinus tracts. Marrow edema involving the cuboid and adjacent bones is seen, along with extensive surrounding soft tissue edema..

however, its presentation can vary widely, particularly in immunocompromised individuals [5]. The present case is notable for its bilateral involvement, cystic morphology, and persistently negative microbiological findings, all of which contribute to a significant diagnostic dilemma.

An important consideration in such cases is chronic non-infective osteomyelitis, a sterile inflammatory disorder characterized by immune-mediated bone inflammation¹. Although more commonly described in pediatric populations, adult presentations – particularly in association with autoimmune diseases such as rheumatoid arthritis – are increasingly recognized [2]. The bilateral and multifocal nature of the lesions in this patient, along with negative cultures, raises the possibility of a non-infective inflammatory process.

However, several features in this case strongly favor an infective etiology. MRI demonstrated multiloculated collections, sinus tract formation, cortical breach, and marrow edema, which are characteristic of chronic osteomyelitis [3,6]. Imaging plays a pivotal role in such scenarios, as MRI has high sensitivity for detecting early bone and soft-tissue involvement, although its specificity remains limited [7]. Therefore, radiological findings must be interpreted in conjunction with clinical and histopathological data.

The persistently culture-negative status observed in this patient is not uncommon, with literature reporting rates of up to 30% [2, 8]. This may be attributed to prior antibiotic exposure, low-virulence organisms, or inadequate sampling. In addition, prolonged corticosteroid use in this patient likely contributed to immune suppression, masking classical signs of infection and potentially leading to sterile cultures [4].

Another rare but relevant differential diagnosis is pseudophycomycotic cyst [9], a form of subcutaneous fungal infection seen in immunocompromised hosts. These lesions may present as chronic, cystic swellings mimicking benign or infective conditions. However, the absence of fungal elements on histopathology, along with negative KOH and culture studies, makes this diagnosis unlikely in the present case. Ganglion cysts [10] may present as cystic, occasionally multiloculated lesions; however, the presence of sinus tracts, marrow edema, and cortical breach in this case is atypical. Synovial cyst

was also considered, but the absence of a clear communication with the adjacent joint or tendon sheath on imaging made this diagnosis unlikely. In addition, the lesions lacked synovial lining on histopathology, arguing against a synovial cyst. Mycetoma was ruled out as there was absent discharging sinuses, granules, and a typical “dot-in-circle” [11] sign on MRI argued against this diagnosis. Furthermore, no fungal elements or grains were identified on cytology/biopsy, making mycetoma unlikely. Rheumatoid nodules were considered, given the background of rheumatoid arthritis; however, the atypical bilateral plantar distribution and imaging characteristics were not classical. Moreover, histopathology did not demonstrate well-formed palisading granulomas [12] with central fibrinoid necrosis, making this diagnosis less likely. It went against the favor of Ledderhose disease [13] as the lesions were not confined to the plantar fascia and lacked the typical cord-like fibromatosis pattern on imaging. In addition, histopathology did not show dense fibroblastic proliferation with collagen deposition, making this diagnosis unlikely. Neoplasm was ruled out from considerations as neither imaging did not show a discrete aggressive mass, bone destruction, or invasive features, nor histopathology did not reveal cellular atypia, pleomorphism, or mitotic activity, effectively ruling out a neoplastic etiology. The presence of bone involvement and sinus tract formation effectively excludes most benign cystic conditions and favors an underlying infective process. Thus, this case represents a complex diagnostic dilemma. Although infectious osteomyelitis remained a strong consideration based on MRI findings, persistently negative microbiological studies and non-specific histopathology prevented definitive confirmation. Chronic non-infective osteomyelitis appears to be the most plausible diagnosis after exclusion of other differentials with atypical cystic presentation, occurring in an immunocompromised host. It underscores the importance of maintaining a high index of suspicion and relying on a combination of clinical, radiological, and histopathological findings for diagnosis.

Bilateral multiloculated cystic swellings of the foot with negative microbiological studies represent a significant diagnostic challenge. Chronic non-infective osteomyelitis should be strongly considered in such cases, particularly in immunocompromised patients. MRI and histopathology play a crucial role in establishing the diagnosis when cultures are inconclusive.




Figure 5: Aspiration showing clear straw-colored fluid without evidence of blood clots or purulent material.

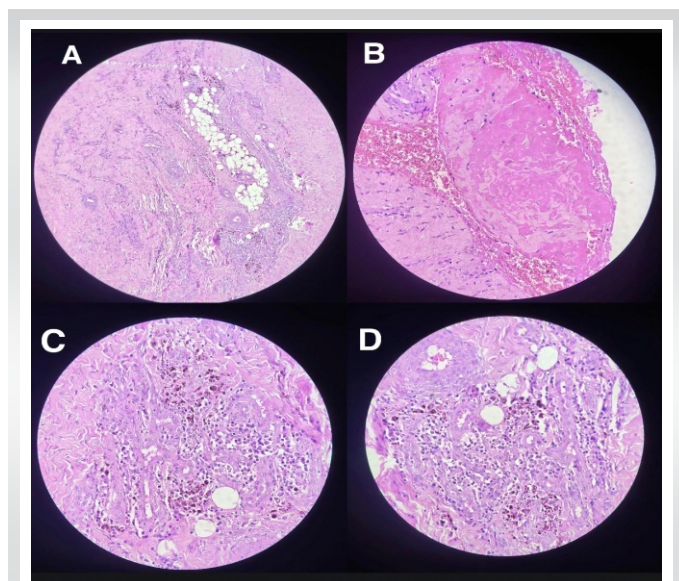


Figure 6: Histopathology sections (H&E stain): (A) low-power field section showing inflammatory changes, (B) high-power field depicting focal fibrin deposition, and (C, D) high-power fields showing inflammatory infiltrate with pigment-laden macrophages.

Limitations

This report describes a single unusual case and is intended to highlight a diagnostic challenge rather than provide generalizable conclusions. Definitive microbiological confirmation was not obtained despite extensive testing and advanced molecular diagnostics. Additional imaging modalities such as positron emission tomography-computed tomography or bone scintigraphy

were not performed due to financial constraints. Although only one representative lesion underwent open biopsy, the bilateral lesions were clinically and radiologically similar. The patient was followed for six months, during which symptoms improved with empirical antibiotic therapy; however, the final diagnosis remains presumptive.

Conclusion

Bilateral multifocal cystic foot swellings with osteomyelitis-like imaging findings represent a rare and challenging diagnostic entity. Differential diagnoses include infective chronic osteomyelitis, chronic non-infective osteomyelitis (CNO), mycetoma, ganglion cyst, synovial cyst, rheumatoid nodules, pseudohyphomycosis, Ledderhose disease, inflammatory arthropathies, and soft-tissue neoplasms. In the present case, chronic non-infective osteomyelitis emerged as the most plausible diagnosis owing to bilateral multifocal involvement, persistently sterile microbiological studies, non-specific histopathology, absence of definitive infective or neoplastic pathology, and clinicoradiological features suggestive of a sterile inflammatory process. This case highlights the importance of integrating clinical, radiological, microbiological, and histopathological findings while evaluating atypical bilateral foot lesions in immunocompromised patients.

Clinical Message

In patients presenting with bilateral cystic foot swellings and sterile microbiological studies, chronic non-infective osteomyelitis should be considered alongside infectious osteomyelitis. Diagnosis requires careful clinicoradiological and histopathological correlation, particularly in immunocompromised individuals.

Declaration of patient consent: The authors certify that they have obtained all appropriate patient consent forms. In the form, the patient has given the consent for his/ her images and other clinical information to be reported in the journal. The patient understands that his/ her names and initials will not be published and due efforts will be made to conceal their identity, but anonymity cannot be guaranteed.

Conflict of interest: Nil **Source of support:** None

References

- Lew DP, Waldvogel FA. Osteomyelitis. *Lancet* 2004;364:369-79.
- Calhoun JH, Manning MM. Adult osteomyelitis. *Infect Dis Clin North Am* 2005;19:765-86.
- Pineda C, Espinosa R, Pena A. Radiographic imaging in osteomyelitis: The role of plain radiography, computed tomography, ultrasonography, magnetic resonance imaging, and scintigraphy. *Semin Plast Surg* 2009;23:80-9.
- Kaplan SL. Bone and joint infections. *J Infect* 2014;68:S51-6.
- Zimmerli W. Clinical practice. Vertebral osteomyelitis. *N Engl J Med* 2010;362:1022-
- Termaat MF, Raijmakers PG, Scholten HJ, Bakker FC, Patka P, Haarman HJ. The accuracy of diagnostic imaging for the assessment of chronic osteomyelitis: A systematic review and meta-analysis. *J Bone Joint Surg Am* 2005;87:2464-71.
- Palestro CJ, Love C, Miller TT. Imaging of musculoskeletal infections. *Best Pract Res Clin Rheumatol*. 2006;20:1197-1218
- Senneville E, Robineau O, Valette M, Beltrand E, Legout L, Caillaux M. Culture-negative osteomyelitis. *Int J Infect Dis*. 2012;16:e406-11.
- McGinnis MR. Phaeoerythromycosis and hyalohyphomycosis. *Mycopathologia*. 1983;81:3-19.
- Neto N, Nunnes P. Spectrum of MRI features of ganglion and synovial cysts. *Insights Imaging* 2016;7:179-86.
- arris I, Berendt AR, Athanasous N, Ostlere SJ. The MRI 'dot-in-circle' sign in mycetoma: A characteristic finding. *AJR Am J Roentgenol*. 2003;180:357-59.
- Kumar V, Abbas AK, Aster JC. Robbins and Cotran Pathologic Basis of Disease. 10th ed. Netherlands: Elsevier; 2020.
- De Palma L, Angelini A, Pavan M, Zanus G. Plantar fibromatosis (Ledderhose disease): MR imaging findings. *Radiol Med*. 1999;98:117-20.

Conflict of Interest: Nil

Source of Support: Nil

Consent: The authors confirm that informed consent was obtained from the patient for publication of this article

How to Cite this Article

Nirmal S, Kiran H, Raghav RV, Aditya B, Kumar MM. Atypical Bilateral Cystic Foot Swellings with Osteomyelitis-Like Features: A Diagnostic Dilemma. *Journal of Orthopaedic Case Reports* 2026 June;16(06):524-527.

