

# Varied Reduction and Fixation Modalities for Scapula Fractures: A Case Series

Parth Panchal<sup>1</sup>, Shivam Sharma<sup>2</sup>, Hemant Soni<sup>3</sup>, Sanjay Soni<sup>3</sup>, Dhruv Sharma<sup>3</sup>, Mohit Tolani<sup>3</sup>

## Learning Point of the Article:

Scapula fractures are operated less often and there exists lack of references for fixation techniques. This case series illustrates varied reduction and fixation modalities practiced for diverse patterns of scapula fractures for adequate restoration of bony anatomy.

## Abstract

**Introduction:** Scapula fractures usually comprise polytrauma and seldom are operated on, resulting in a dearth of literature and clinical experience. The aim of this case series is to illustrate diverse patterns of scapula fracture, varied reduction and fixation modalities practiced in different case scenarios.

**Case Series:** This is a retrospective descriptive case series, conducted at a teaching tertiary care center over a period of 1 year. Fifteen patients (14 males and 1 female) of scapula fractures following high-energy trauma, with an average age of 32.5 years, were selected based on the inclusion and exclusion criteria. They were operated by a single experienced trauma surgeon for internal fixation with a combination of different implant combination and placement. Variedly classified scapula fractures requiring a specific approach, reduction, and fixation with case-tailored implant positioning are illustrated in detail. Augmentation techniques such as long sub-glenoid screw, dual lateral border construct, concurrent acromion and coracoid fixation using saber incision, corresponding intra-articular and extra-articular fracture, lateral border reduction necessitating medial release using reverse Judet approach were applied and found to be effective in restoration of bony anatomy. This was evident by the restoration of radiographic (Cole's) parameters assessed postoperatively and at 6-month follow-up. Furthermore, augmentation of traditional fixation allows early range of motion and hence, a satisfactory functional outcome as apparent by the Constant-Murley Score assessment at 6-month follow-up.

**Conclusion:** Scapular fractures have a varied type, which makes accurate classification and visualization of fracture planes absolutely indispensable. Each pattern requires special consideration for choosing the appropriate surgical approach to achieve adequate reduction and final fixation using specific placement of different implants.

**Key words:** Scapula fracture, glenoid fracture, shoulder trauma.

## Introduction

Scapula fractures comprise the body (45%) and glenoid (35%), with 0.4–1% cases accounting for floating shoulder [1]. The broad spectrum of scapula fractures put treating surgeon in a quandary, with most cases being managed non-operatively

owing clinical inexperience or priority given to associated injuries [2]. Distributed and incoherent literature brings no resolve to the predicament of selecting accurate management. This retrospective descriptive case series depicts varied fracture patterns of the scapula and illustrates case specific surgical

Access this article online

Website:  
www.jocr.co.in

DOI:  
<https://doi.org/10.13107/jocr.2026.v16.i07.7736>

## Author's Photo Gallery



Dr. Parth Panchal



Dr. Shivam Sharma



Dr. Hemant Soni



Dr. Sanjay Soni



Dr. Dhruv Sharma



Dr. Mohit Tolani

<sup>1</sup>Department of Orthopaedics, GMERS Medical College, Valsad, Gujarat, India,  
<sup>2</sup>Department of Orthopaedics, GMERS Medical College, Ahmedabad, Gujarat, India,  
<sup>3</sup>Department of Orthopaedics, Pramukhswami Medical College, Anand, Gujarat, India

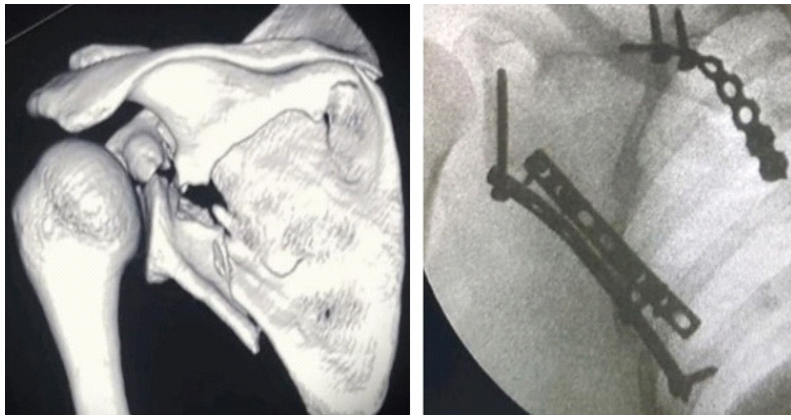
### Address of Correspondence:

Dr. Shivam Sharma,  
H. No. 40, Sector 8A, Gandhinagar, Gujarat – 382007, India.  
E-mail: mailshivamsha@gmail.com

Submitted: 03/04/2026; Review: 21/05/2026; Accepted: June 2026; Published: July 2026

DOI: <https://doi.org/10.13107/jocr.2026.v16.i07.7736>

© The Author(s). 2026 Open Access. This article is distributed under the terms of the Creative Commons Attribution 4.0 International License (<https://creativecommons.org/licenses/by-nc/4.0/>), which permits unrestricted use, distribution, and non-commercial reproduction in any medium, provided you give appropriate credit to the original author(s) and the source, provide a link to the Creative Commons license, and indicate if changes were made. The Creative Commons Public Domain Dedication waiver (<http://creativecommons.org/publicdomain/zero/1.0/>) applies to the data made available in this article, unless otherwise stated.



**Figure 1:** Bi-planar lateral pillar construct.

approach, reduction techniques, implant choice, and placement with different modalities of Scapula fracture fixation.

### Case Report

After obtaining Institutional Ethics Committee approval at a teaching tertiary care center, fifteen patients with scapula fracture (14 males and 1 female, average age 32.5 years) following high-energy trauma, were selected over 1 year. Inclusion and exclusion criteria were used, and the selected patients included both extra-articular and intra-articular fracture varieties, with some having concurrent acromion, coracoid, or clavicle fractures. After availing patient's consent and pre-surgical fitness, they were operated on for open reduction and internal fixation by a single experienced surgeon. The surgical approach was tailored for each case, and fixation was achieved using a combination of different orientations of plates and screw placement, resulting in varied fixation

modalities for different patterns of scapula fractures. Restoration of bony anatomy and Cole's criteria were assessed in plain radiograph as the post-operative and 6-month follow-up radiological outcome measure. Functional assessment was done by evaluating the patients and interpreting the Constant-Murley Score (CMS) at a single 6-month follow-up.

### Inclusion criteria

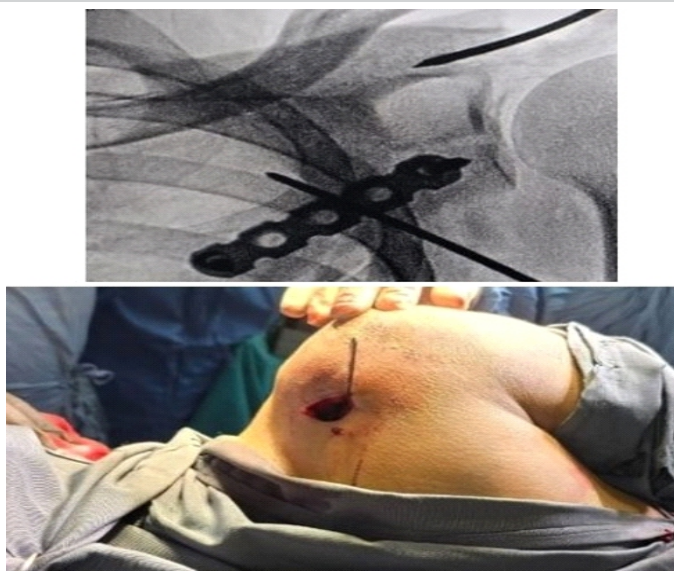1. Age >18 years
2. Operative scapular fractures based on Cole's operative criteria [3]
3. Floating shoulder (Superior Shoulder Suspensory Complex [SSSC] injury).

### Exclusion criteria

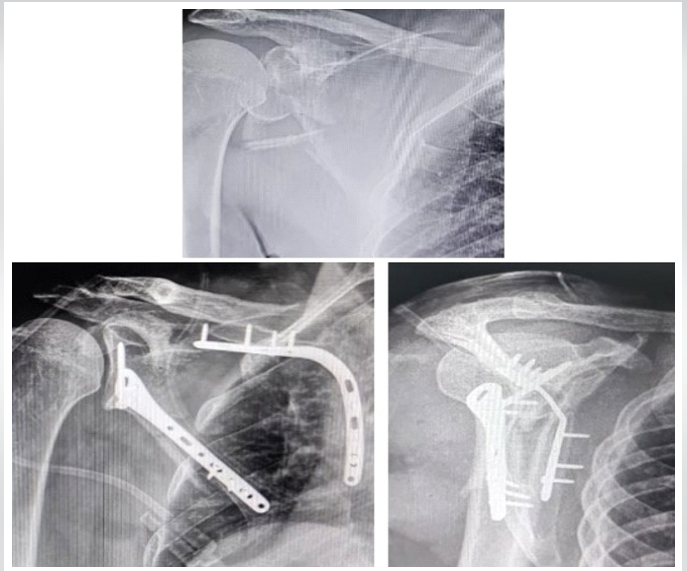
1. Severely comorbid conditions due to trauma or chest trauma or those requiring intensive care
2. Polytrauma cases
3. Patients not meeting the surgical indication and managed conservatively
4. Patients medically unfit for surgery
5. Non-consenting patients.

### Case-1: Bi-planar lateral pillar construct

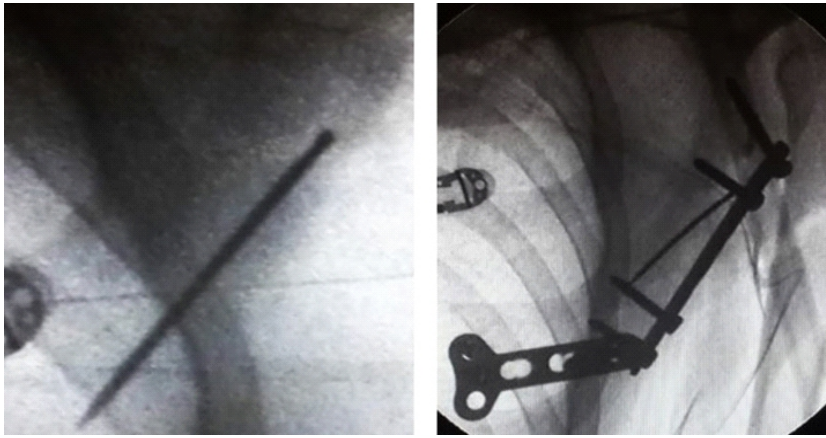
Ideberg Type 5a intra-articular fracture with extra-articular extension may be fixed with a posterior surface 3.5 mm dynamic compression plate (DCP) augmented with a lateral surface 3.5 mm semi-tubular plate using a long (55 mm) sub-glenoid screw



**Figure 2 :** Reduction maneuver.



**Figure 3:** Fixation through Reverse Judet approach.



**Figure 4:** Lost K-wire technique.

**Case-2: Reduction maneuver**

Ideberg Type 2 intra-articular glenoid fractures in the axial plane are often irreducible, despite of adequate exposure through the posterior approach. Using coracoid as fulcrum to achieve reduction by Kapandji lever technique has a utilitarian benefit in such cases (Fig. 2).

6-month follow-up CMS – 82.

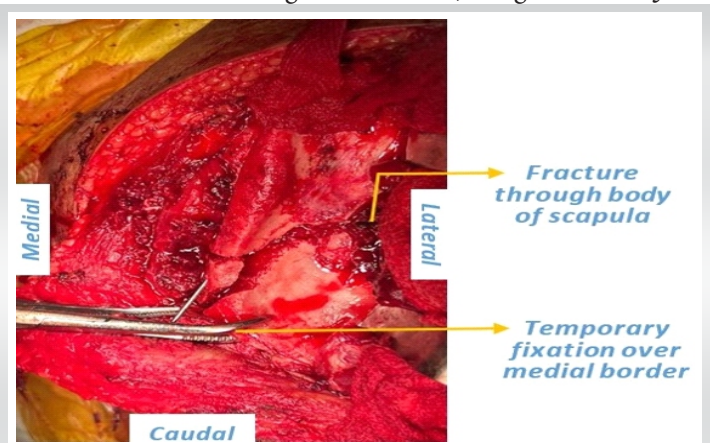
**Case-3: Fixation through reverse Judet approach**

Ideberg Type 5a fracture fixed with anatomical posterior and medial plates with a 3.5 mm cortical screw for glenoid fixation, using the reverse Judet

for simultaneous intra-articular fixation. Simultaneous use of lateral and posterior plates over the lateral border makes a stronger biplanar construct. Placing a lateral surface plate along the lateral border may require medialization of the quadrangular space to expose the glenoid neck, that is, elevating the long head of triceps off the lateral border, sparing the origin at the infraglenoid tubercle [4]. The medial border is fixed using a contoured 3.5 mm reconstruction plate (Fig. 1).

The preferred sub-glenoid screw directed (towards coracoid base) usually ranges from 35 mm to 60 mm, the most common being 55 mm, through a semi-tubular or reconstruction plate along the lateral border to augment the posterior surface fixation, making a stronger and more stable bi-planar construct.

6-month follow-up CMS – 95.



**Figure 5:** Lost K-wire technique.

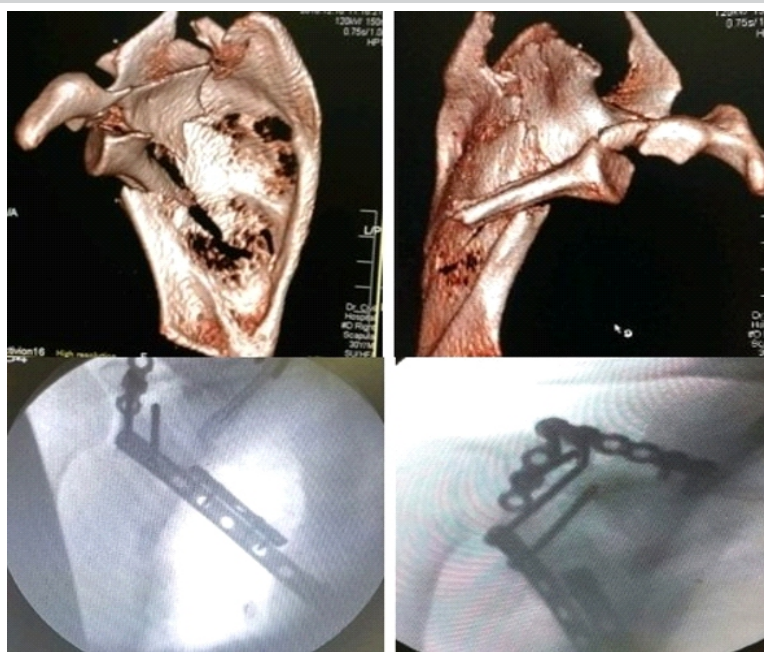
approach [5], which aids in reduction of the lateral pillar by allowing medial release and simultaneous visualization of both the medial and lateral pillars (Fig. 3).

6-month follow-up CMS – 88.

**Case-4: Lost K wire technique**

Fixation of the extra-articular fracture with lateral border comminution with a K wire, augmented by final fixation with 3.5 mm lateral surface plate and 3.5 mm Ellis T plate distally near the inferior angle through Brodsky approach or temporary fixation over the medial border through reverse Judet approach, typically for comminuted fractures aid in reconstruction of the lateral and medial bony pillars. Angulation and medialization may not correct unless fracture fragments over the body and medial border are not completely freed of soft-tissue pull [6] (Fig. 4 and 5).

6-month follow-up CMS – 88.



**Figure 6:** Bi-planar lateral pillar construct with arthrotoxy.

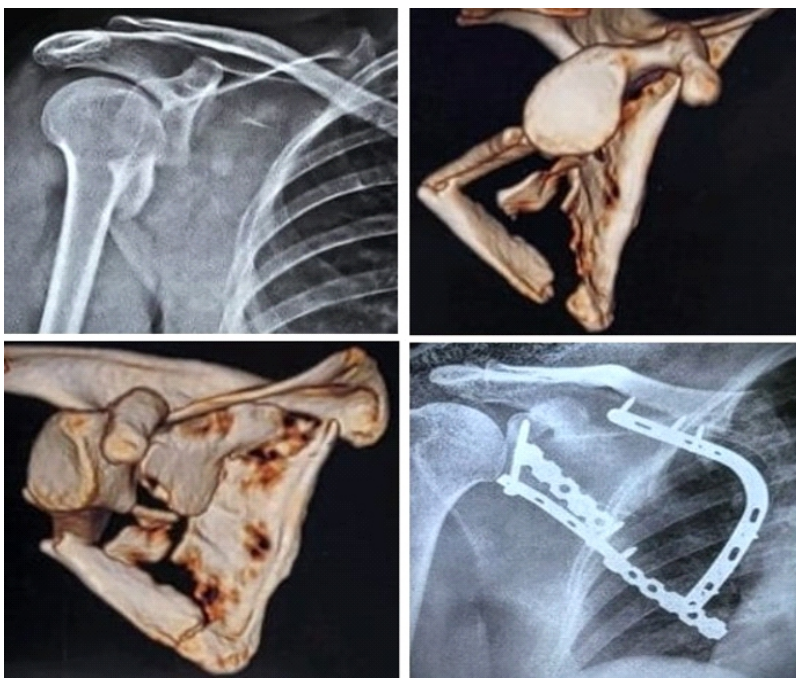


Figure 7: Contoured distal lateral pillar plate.

#### Case-5: Bi-planar lateral pillar construct with arthroscopy

Ideberg Type 5c combined extra-articular and intra-articular fracture fixation, using a 2.7 mm semi-tubular plate over the posterior surface, augmented with 3.5 mm long DCP along the lateral surface with a sub-glenoid screw through modified Judet approach. Posterior joint arthroscopy was done in line with the posterior glenoid rim, and final fixation was achieved with a small posterior glenoid plate, while keeping the posterior and lateral surface plate in situ (Fig. 6).

6-month follow-up CMS – 92.

#### Case-6: Contoured distal lateral pillar plate

Extra-articular fracture with scapular body comminution and angulation was fixed using a medial anatomical plate, proximal lateral surface 3.5 mm semi-tubular plate, and distal posterior surface 3.5 mm reconstruction plate. The distal lateral border was fixed using 3.5 mm reconstruction plate – proximally aligned along the lateral surface, twisted at 90° distally to contour along the posterior surface to achieve stable fixation of the lateral pillar (Fig. 7).

6-month follow-up CMS – 90.

#### Case-7: Associated coracoid base fracture

Ideberg Type 5c comminuted scapular body,

segmental lateral border with medial extension and coracoid base fracture fixed using lateral and posterior plates for the lateral pillar, medial anatomical plate for the medial pillar, and coracoid base screw through half-Saber incision (Fig. 8).

6-month follow-up CMS – 82.

#### Case-8: Associated acromion fracture

Ideberg Type 5a fracture fixed using posterior and lateral surface plate with long (60 mm) sub-glenoid screw and acromion fixation using plate with tension band wiring through the reverse Judet approach (Fig. 9).

6-month follow-up CMS – 78.

#### Case-9: Temporary fixation, associated acromion fracture

Comminuted Ideberg Type 5a fracture temporarily fixed with two posterior surface 3.5 mm semi-tubular plates, removed after final fixation with 3.5 mm semi-tubular plate over the lateral surface with a long sub-glenoid screw and 3.5 mm semi-tubular plate for acromion, all

by a single reverse Judet approach. Screw sizes over the medial and lateral border posterior plates range from 12 mm at thin cortices to 16 mm at thick cortices (Fig. 10).

6-month follow-up CMS – 86.

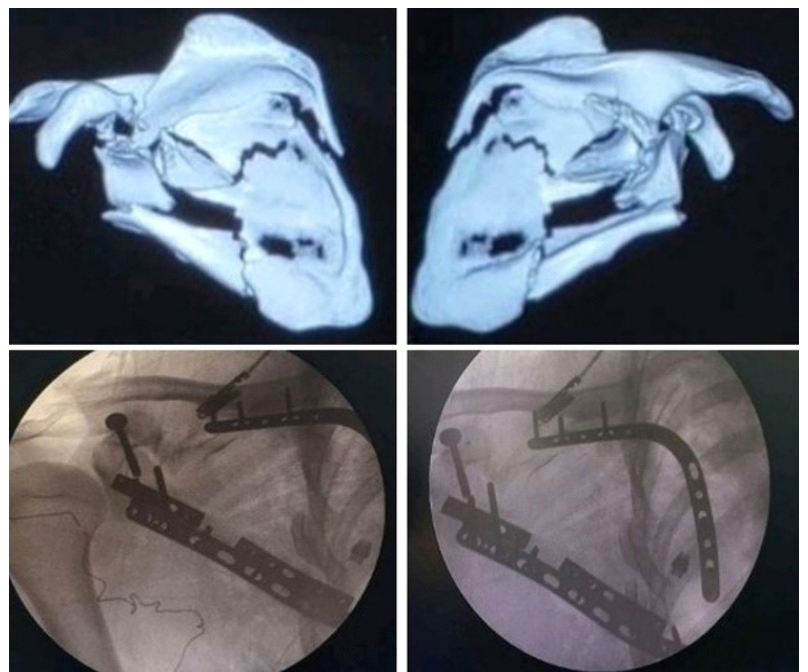


Figure 8: Associated coracoid base fracture.

**Case-10: Percutaneous glenoid fixation**

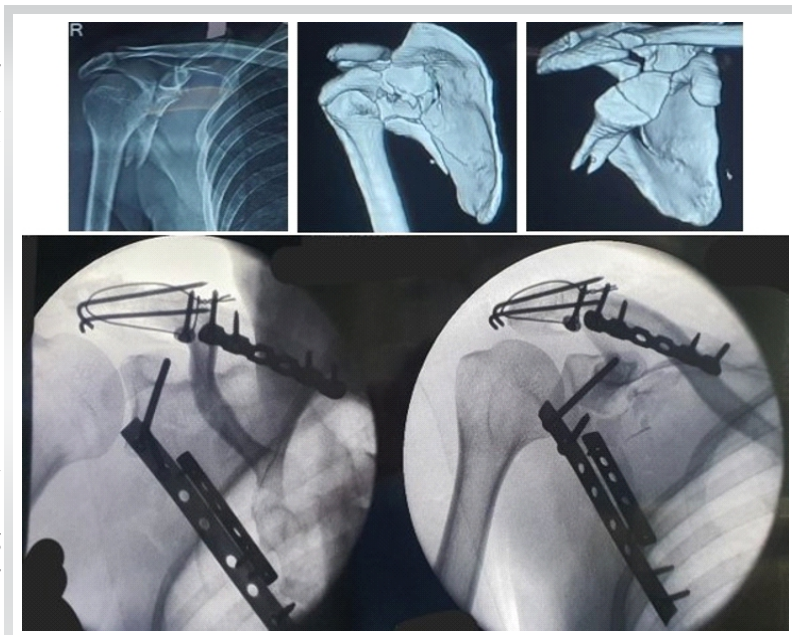
Arthroscopy-assisted percutaneous fixation [7] for Ideberg type 3 displaced glenoid fractures through superior or posterior portal aids in achieving accurate reduction of the glenoid articular margin and allows stable fixation while avoiding drawbacks associated with open dissection (Fig. 11).

6-month follow-up CMS – 90.

**Case-11: Associated clavicle fracture (SSSC injury – floating shoulder)**

Extra-articular comminuted glenoid neck fracture with medial border, acromion, and clavicle fractures was managed with lateral and medial pillar, acromion plating through the reverse Judet approach, and anterior clavicle plating (Fig. 12).

6-month follow-up CMS – 88.



**Figure 9:** Associated acromion fracture.

**Discussion**

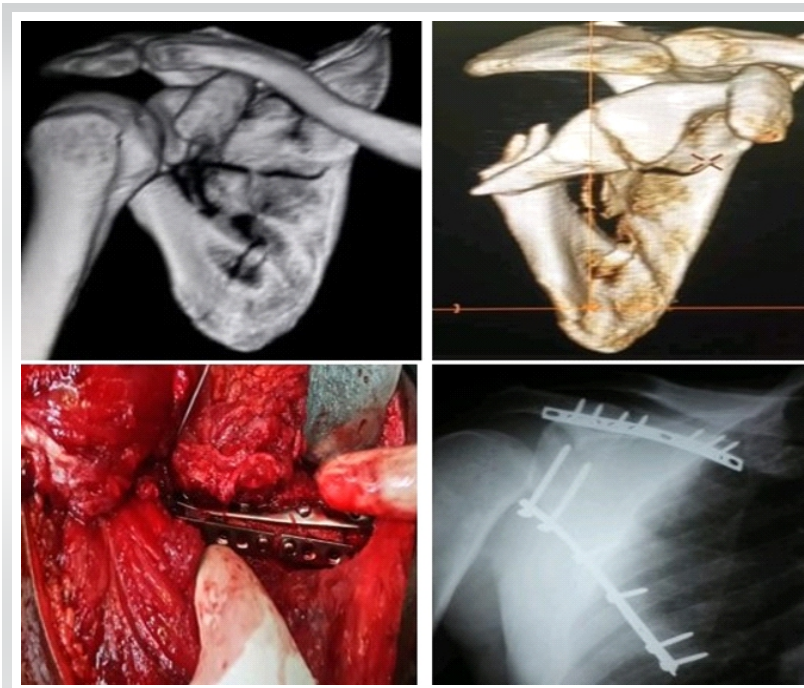
Case Summary			
S. No.	Case Highlight	Diagnosis	Remarks
1	Bi-planar lateral pillar construct (CMS - 95)	Ideberg Type 5a fracture (intra-articular fracture with extra-articular extension)	Posterior surface plate with lateral surface plate using a long (55 mm) sub-glenoid screw; medialization of the quadrangular space (Fig. 1)
2	Reduction maneuver (CMS - 82)	Ideberg Type 2 fracture	Coracoid as fulcrum and reduction by Kapandji technique (Fig. 2)
3	Fixation through Reverse Judet approach (CMS - 88)	Ideberg Type 5a fracture	Anatomical posterior and medial plates with a 3.5 mm cortical screw for glenoid fixation – reverse Judet approach (Fig. 3)
4	Lost K wire technique (CMS - 88)	Extra-articular fracture with lateral wall comminution	K wire augmented lateral surface plate and 3.5 mm Ellis T plate at inferior angle – Brodsky approach. Angulation and medialization corrected by freeing medial border soft-tissue pull (Figs. 4 and 5)
5	Bi-planar lateral pillar construct with arthrotomy (CMS - 92)	Ideberg Type 5c fracture	Posterior surface plate with lateral surface plate and long sub-glenoid screw – modified Judet approach; posterior joint arthrotomy (Fig. 6)
6	Contoured distal lateral pillar plate (CMS - 90)	Extra-articular fracture with scapular body comminution	Medial anatomical plate, proximal lateral plate and twisted lateral distal posterior surface plate (Fig. 7)
7	Associated coracoid base fracture (CMS - 82)	Ideberg Type 5c fracture with comminution	Lateral and posterior plates for lateral pillar, medial anatomical plate, and coracoid base screw through half-Saber incision (Fig. 8)
8	Associated acromion fracture (CMS - 78)	Ideberg Type 5a fracture	Posterior and lateral surface plate, acromion plating with tension band wiring – reverse Judet approach (Fig. 9)
9	Temporary fixation, associated acromion fracture (CMS - 86)	Ideberg Type 5a fracture with comminution and acromion fracture	Temporary bi-planar fixation, lateral border fixation with sub-glenoid screw (Fig. 10)
10	Percutaneous glenoid fixation (CMS - 90)	Ideberg Type 3 displaced glenoid fractures	Arthroscopy-assisted percutaneous fixation (Fig. 11)
11	Associated clavicle fracture (SSSC injury – floating shoulder) (CMS - 88)	Extra-articular comminuted glenoid neck with scapular body, acromion and clavicle fracture	Lateral and medial pillar, acromion plating through the reverse Judet approach, and anterior clavicle plating (Fig. 12)

Scapula fractures, often prone to “benign neglect,” if managed conservatively, may lead to loss of shoulder function due to malalignment or arthrosis, scapula-thoracic dyskinesia, and impingement pain. Operative fixation of scapula fractures, when indicated, is crucial for a satisfactory clinical outcome as evident in studies of Herrera et al. [8], Bartoníček and Frič [9], Cole et al., and Schroder et al. [10]. The functional outcomes depend on thoughtful management protocol designed on a cumulative consideration of patient profile, fracture pattern, and associated injuries.

Surgical management often comes with challenges in the form of pre-operative planning, surgical exposure, and intraoperative handling of vital structures, accurate reduction, and strong fixation. This case series dwells into various cases of scapular fractures and narrates how each was managed for the sake of reference of fellow orthopedic surgeons.

Choosing the right patient according to fracture classification, operative indication, patient bio-profile, and injury characteristics is vital. Furthermore, the most essential part of pre-operative planning is selecting the most suitable approach – one which provides the most abundant exposure, allows easy manipulation of fracture fragments, and helps achieve varied hardware implantation. Taking





**Figure 10:** Temporary fixation, associated acromion fracture.

any posterior approach to scapula essentially involves dissection along the interval of the infraspinatus and teres minor. This interval may be identified by two methods, either looking for the direction of fibers starting laterally and tracing them medially, or alternatively, locating the teres minor fibers origin over the inferior angle of the scapula and tracing it run at a greater angle towards the humeral head.

Authors found the reverse Judet approach aids in several aspects, which are as follows:

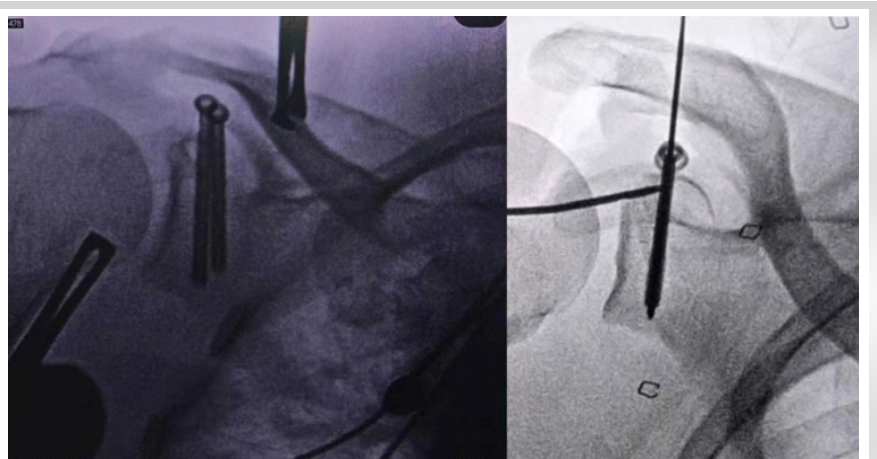
### Merits of the reverse Judet approach

- Greater exposure of multiple anatomical structures at once
- Both extra-articular and intra-articular can be addressed with a single approach
- Manipulation at both medial and lateral borders together, that is, exposure of bony elements of the scapula having adequate bone stock for internal fixation
- Allows plate placement over the lateral surface while manipulating the scapular body and medial border
- Prevention of misdiagnosis of concomitant supra-scapular nerve injury through dissection of spinoglenoid notch to rule out nerve entrapment (leading cause of infraspinatus atrophy)

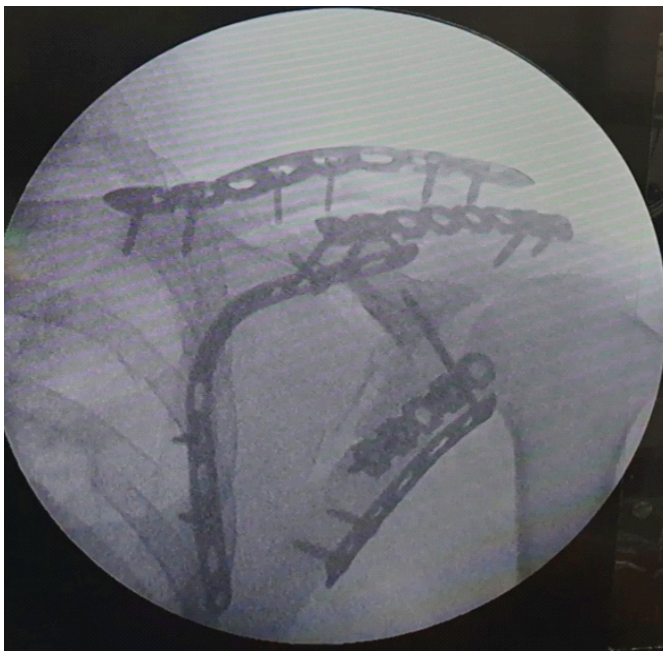
- Allows exposure for open wedge osteotomy to address recurrent posterior shoulder dislocation
- Allows addressing lateral body fixation without removing the deltoid from scapular spine by wide abduction of the arm aiding early mobilization and rehabilitation, without the need to wait for muscle healing
- Allows a stronger biplanar construct
- Best suited for comminuted fractures of the scapular body involving both medial and lateral pillars, intra-articular fractures involving the body and the acromion or coracoid processes, or cases with lateral border fixation requiring medial release
- Chen [11] concluded that the reverse Judet approach shortens the duration of surgery, reduces blood loss, and allows sufficient exposure for reduction and achieving stable fixation, thus allowing for early functional range of motion, proving to be a safe and efficient method for surgical fixation of complicated scapula fractures.

Often overlooked, some important aspects change the outcome of any case. Priority must be given to intra-articular fracture (i.e. reduction of articular step-off) in the presence of simultaneous extra-articular fracture, to avoid painful arthritis. Reduction must be assessed in three views – Grashey AP view/Neer I projection, Y (outlet) view/Neer II projection, and axillary view. Screw penetration must be checked before closure that can result in a painful range of motion and early arthritis; which is visible in Neer I and axillary view. Rotator cuff must be repaired, and capsule should be closed. Allgower Donati suture technique may be preferred to preserve lateral flap vascularization.

Of importance is avoiding vital structures around the scapula.



**Figure 11:** Percutaneous glenoid fixation.



**Figure 12:** Associated clavicle fracture (Superior shoulder suspensory complex injury – floating shoulder).

Wijdicks et al. [12] have characteristically identified critical danger zones comprising neuro-vascular structures. This includes a 4-7-8 cm triangle centered along the spinoglenoid notch, constituting essentially the suprascapular nerve and the ascending branch of the circumflex scapular artery. These must be carefully handled in any posterior approach to scapula nearing the scapular neck.

In this case series, there was no complication in either of the cases, and post-operative radiological criteria were met and found to be satisfactory.

Authors acknowledge limitations of this study pertaining the small sample size and lack of long term outcome measure but each is of value since they provide either newer or augmentation of previously existing fixation methods for various scapula fractures. It is highlighted that the dissection and surgical approaches used are already existent in the literature and widely practiced.

Furthermore, the series does not intend to establish superiority of any single fixation technique, rather it showcases augmentation to existing methods of fixation and adds to the

knowledge of any operating orthopedic surgeon some reduction techniques which can come handy in everyday surgical practice.

The reduction maneuvers and augmentation techniques for existing fixation methods provide a better reduction as measured in post-operative radiograph and on a 6-month follow-up, and allow early range of motion. Functional evaluation using the CMS at a single 6-month follow-up of all cases placed twelve patients in the very good (86–100) category, whereas three patients fell in the good category (71–85); evidential of satisfactory outcome.

Authors acknowledge that the study's small sample size ( $n = 15$ ), retrospective design, single-center setting, and single-surgeon experience limit the strength of the evidence and the generalizability of the findings.

They further advocate of a cohort study with a large sample size to assess and compare the functional outcomes with radiological parameters for long term outcomes.

### Conclusion

The case series illustrates the fact that scapular fractures have a diverse presentation, necessitating accurate classification and fracture plane visualization. Each pattern requires special consideration while choosing the surgical approach, appropriate reduction technique, and varied implant placement to achieve a strong and rigid fixation to meet the post-operative criteria. The presented case series demonstrates the feasibility of various reduction and fixation strategies in selected patients and provides technical insights that may assist surgeons managing similar injuries. Authors emphasize that larger prospective studies with standardized protocols, comparative cohorts, and long-term follow-up are necessary before definitive recommendations can be made.

### Clinical Message

Diverse scapula fracture patterns require varied reduction and fixation modalities practiced in different case scenarios.

**Declaration of patient consent:** The authors certify that they have obtained all appropriate patient consent forms. In the form, the patient has given the consent for his/ her images and other clinical information to be reported in the journal. The patient understands that his/ her names and initials will not be published and due efforts will be made to conceal their identity, but anonymity cannot be guaranteed.

**Conflict of interest:** Nil **Source of support:** None

## References

1. Schmidt V, Mukka S, Bergdahl C, Ekholm C, Brüggemann A, Wolf O. Epidemiology, treatment, and mortality of 3973 scapula fractures from the Swedish fracture register. *J Shoulder Elbow Surg* 2025;34:e47-56.
2. annan S, Singh HP, Pandey R. A systematic review of management of scapular fractures. *Acta Orthop Belg* 2018;84:497-508.
3. Cole PA, Freeman G, Dubin JR. Scapula fractures. *Curr Rev Musculoskelet Med* 2013;6:79-87.
4. Gauger EM, Cole PA. Surgical technique: A minimally invasive approach to scapula neck and body fractures. *Clin Orthop Relat Res* 2011;469:3390-9.
5. Manohara R, Kumar VP. A reverse judet approach to the scapula. *Arch Orthop Trauma Surg* 2018;138:669-73.
6. Pires RE, Giordano V, de Souza FS, Labronici PJ. Current challenges and controversies in the management of scapular fractures: A review. *Patient Saf Surg* 2021;15:6.
7. Marsland D, Ahmed HA. Arthroscopically assisted fixation of glenoid fractures: A cadaver study to show potential applications of percutaneous screw insertion and anatomic risks. *J Shoulder Elbow Surg* 2011;20:481-90.
8. Herrera DA, Anavian J, Tarkin IS, Armitage BA, Schroder LK, Cole PA. Delayed operative management of fractures of the scapula. *J Bone Joint Surg Br* 2009;91:619-26.
9. Bartoníček J, Frič V. Scapular body fractures: Results of operative treatment. *Int Orthop* 2011;35:747-53.
10. Schroder LK, Gauger EM, Gilbertson JA, Cole PA. Functional outcomes after operative management of extra-articular glenoid neck and scapular body fractures. *J Bone Joint Surg Am* 2016;98:1623-30.
11. Chen Y. Evaluation of reverse Judet approach in the treatment of scapular body complicated fractures. *Int J Surg* 2021;12:760-3.
12. Wijdicks CA, Armitage BM, Anavian J, Schroder LK, Cole PA. Vulnerable neurovasculature with a posterior approach to the scapula. *Clin Orthop Relat Res* 2009;467:2011-7.

**Conflict of Interest:** Nil

**Source of Support:** Nil

**Consent:** The authors confirm that informed consent was obtained from the patient for publication of this article

## How to Cite this Article

Panchal P, Sharma S, Soni H, Soni S, Sharma D, Tolani M. Varied Reduction and Fixation Modalities for Scapula Fractures: A Case Series. *Journal of Orthopaedic Case Reports* 2026 July;16(07): 513-520.

