

Revision of a Dislocated Articulating Antibiotic Hip Spacer as an Alternative to Girdlestone Arthroplasty: A Case Report

Ibaad Khan¹, Thomas J Pumo¹, Alexander A Linton¹, David N Kugelman¹

Learning Point of the Article:

Clinicians should perform adequate techniques to prevent spacer dislocation, and if this occurs, revision spacer is an option rather than Girdlestone arthroplasty.

Abstract

Introduction: Dislocation of an articulating antibiotic spacer is a rare but significant complication following the first stage of revision hip arthroplasty for infection. This report describes a case of posterior dislocation of a right hip articulating antibiotic spacer, its management, and subsequent total hip arthroplasty (THA).

Case Report: A 67-year-old man presented with chronic right hip pain and limited mobility. Radiographs and laboratory work confirmed septic arthritis of the native hip, with aspiration cultures positive for methicillin-sensitive *Staphylococcus aureus*. He initially underwent right hip resection arthroplasty with articulating antibiotic spacer placement, which dislocated shortly thereafter. Closed reduction was unsuccessful. He subsequently underwent revision of the dislocated spacer with a new articulating spacer. Intraoperative cultures were positive for *Bacillus* species, and intravenous antibiotics were administered. Definitive THA was later performed as a second-stage procedure. At the latest follow-up, he was ambulating independently with minimal pain and no recurrent infection.

Conclusion: Spacer dislocation is a rare yet serious complication that can compromise infection control and mechanical stability. Adequate techniques should be employed to ensure this does not happen, and if it does, a surgeon should consider a revision antibiotic spacer instead of Girdlestone arthroplasty.

Keywords: Periprosthetic joint infection, total hip arthroplasty, two-stage revision, antibiotic spacer.

Introduction

Periprosthetic joint infection (PJI) remains one of the most devastating complications following total hip arthroplasty (THA) [1]. The gold standard for chronic PJI treatment is two-stage exchange arthroplasty, which involves component explantation and placement of an antibiotic spacer followed by delayed reimplantation [2].

Antibiotic articulating spacers maintain limb length and soft-tissue tension while delivering high local concentrations of

antibiotics [3]. Despite their therapeutic benefit, spacer-related complications, including fracture, mechanical failure, and dislocation, can compromise functional outcomes and prevent infection eradication [4]. Spacer dislocation has previously been identified as the most common overall mechanical complication of these procedures [5]. Reported dislocation rates vary widely, ranging from 6% to 41% depending on spacer design, patient factors, and fixation technique [6,7,8].

Spacer dislocation has been associated with various surgical and

Author's Photo Gallery



Dr. Ibaad Khan



Dr. Thomas J Pumo



Dr. Alexander A Linton



Dr. David N Kugelman

Access this article online

Website:
www.jocr.co.in

DOI:
<https://doi.org/10.13107/jocr.2026.v16.i06.7544>

¹Department of Orthopaedic Surgery, Rothman Orthopaedic Institute at Thomas Jefferson University, Philadelphia, Pennsylvania, USA.

Address of Correspondence:

Dr. Ibaad Khan,
Department of Orthopaedic Surgery, Rothman Orthopaedic Institute at Thomas Jefferson University, Philadelphia, Pennsylvania, USA.
E-mail: ibaadkhan@gmail.com

Submitted: 05/03/2026; Review: 13/04/2026; Accepted: May 2026; Published: June 2026

DOI: <https://doi.org/10.13107/jocr.2026.v16.i06.7544>

© The Author(s). 2026 Open Access. This article is distributed under the terms of the Creative Commons Attribution 4.0 International License (<https://creativecommons.org/licenses/by-nc/4.0/>), which permits unrestricted use, distribution, and non-commercial reproduction in any medium, provided you give appropriate credit to the original author(s) and the source, provide a link to the Creative Commons license, and indicate if changes were made. The Creative Commons Public Domain Dedication waiver (<http://creativecommons.org/publicdomain/zero/1.0/>) applies to the data made available in this article, unless otherwise stated.

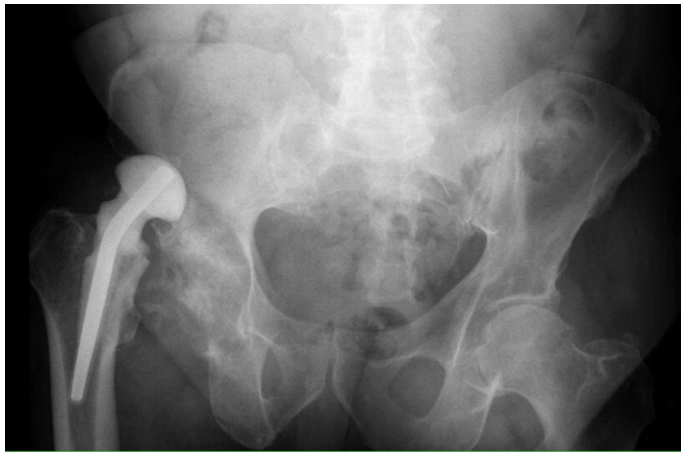

Figure 1: Dislocated antibiotic spacer. AP radiograph of the pelvis demonstrating posterior dislocation of the spacer relative to the acetabulum with no associated fracture evident.

patient-specific factors, including insufficient fixation of the spacer, typically due to undersizing, reduced femoral offset, acetabular bone loss, and patient noncompliance with post-operative instructions [9,10]. Spacer design may play a role, with some evidence for higher rates of mechanical complications, including instability in molded spacers compared to preformed spacers [5]. Interestingly, Bori et al. found no modifiable risk factors for spacer dislocation despite worse clinical outcomes in those patients [11]. Closed reduction may be attempted but with varying success rates; Faschingbauer et al. found that only four of 12 observed spacer dislocations could undergo closed reduction and stable retention [12]. Many cases have therefore traditionally been managed with Girdlestone resection arthroplasty, which sacrifices joint function and soft-tissue tension in order to prevent further mechanical complications or provide further infection control. However, recent evidence suggests that spacer revision can be an effective option with infection eradication and acceptable complication rates while preserving joint function [13].

We present a case of dislocation of an articulating antibiotic hip spacer managed successfully with revision to a semi-constrained design, followed by definitive reimplantation. This case highlights critical surgical decision-making and technical considerations in managing early spacer instability.

Case Report

A 67-year-old man (body mass index 27.5 kg/m², the American Society of Anesthesiologists Physical Status Classification System III, Charlson Comorbidity Index 3) with a history of chronic obstructive pulmonary disease, left upper-extremity deep vein thrombosis, and degenerative joint disease presented with several months of worsening right native hip pain and

limited ambulation. He underwent platelet-rich plasma injection in the hip and subsequently had a significant increase in pain in the days following the injection, concerning for septic arthritis. Hip aspiration indicated native hip septic arthritis with cultures positive for methicillin-sensitive *Staphylococcus aureus*, and intravenous (IV) nafcillin therapy was initiated.

Initial surgery and complication

Over the course of the next 2 months, the patient underwent multiple irrigations and debridements, with recurrent pain and persistent infection. He then underwent right hip resection arthroplasty with insertion of an articulating antibiotic spacer. Immediately after surgery, he experienced acute right hip pain in the post-anesthesia care unit. Radiographs demonstrated posterior dislocation of the spacer without fracture (Fig. 1). Closed reduction was attempted but was unsuccessful. He was then transferred from the outside hospital (OSH) and outside surgeon to our tertiary care center, approximately 1 month after this initial dislocation event, as he was being managed nonoperatively at the OSH.

Revision spacer surgery

The patient returned to the operating room for removal of the dislocated spacer and insertion of a new articulating spacer utilizing real components. Our decision was made to proceed with an articulating spacer rather than a Girdlestone due to

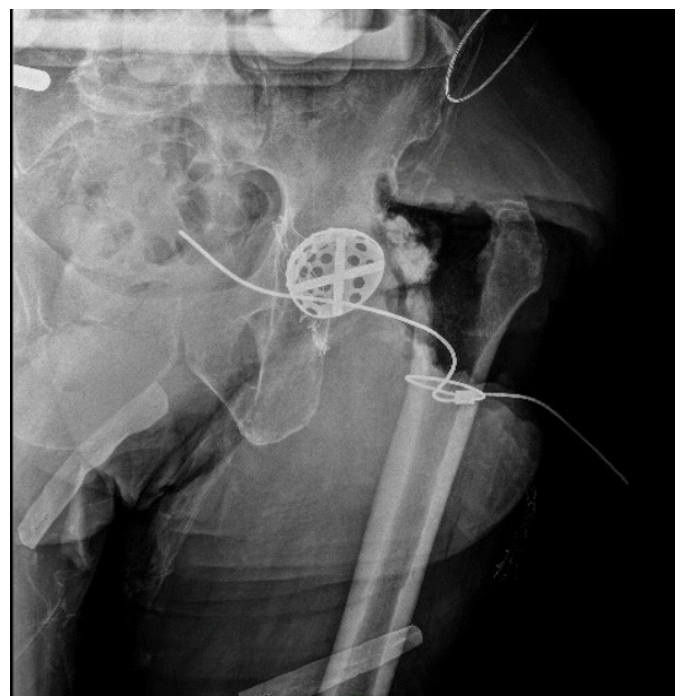


Figure 2: Intraoperative X-ray confirming identification of anatomic acetabulum. Intra-operative AP radiograph utilizing a reamer shell to confirm correct identification of the anatomic acetabulum.

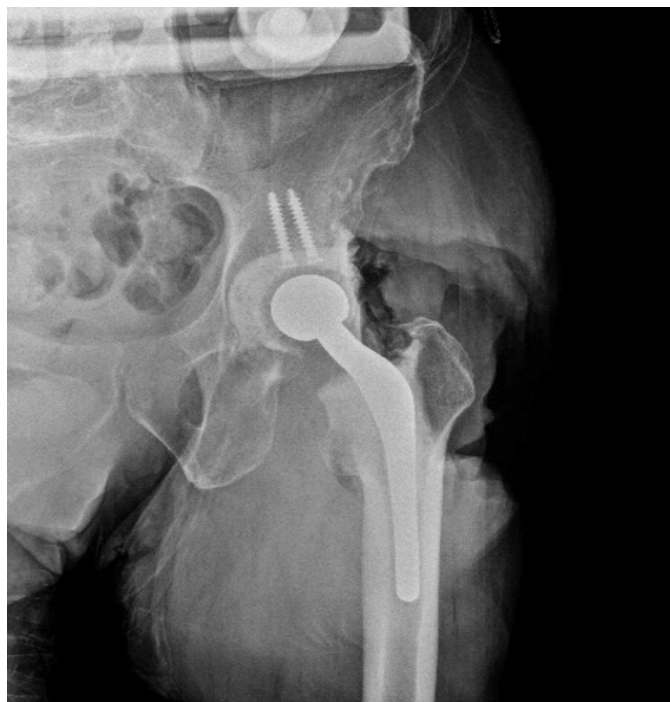

Figure 3: Intraoperative imaging of final spacer construct. Intraoperative AP radiograph of final spacer construct demonstrating stable alignment without fracture.

numerous flaws in the original procedure's surgical technique, including varus malpositioning, inadequate version, and leg length discrepancy. Intraoperatively, the femoral stem was well-fixed, and no purulence was noted, but there was significant superolateral acetabular bone loss with formation of a pseudoacetabulum.

The stem was approached first and removed with no issue. We then approached the acetabulum. Since the hip was dislocated for nearly 1 month, a pseudoacetabulum was beginning to develop. To find the real acetabulum, the cotyloid fossa was identified, and a cobra retractor was placed inferior to the transverse acetabular ligament. We utilized reamers and intraoperative X-ray to confirm that the anatomic acetabulum was indeed identified (Fig. 2). After debridement and identification of the true acetabulum, two 35-mm screws were placed to be used as an augment to our cement fixation. Bone wax was placed in the screw holes for easy removal during the planned second stage. A constrained liner was used to reduce the risk of repeat dislocation. The liner was cemented in place in appropriate anteversion and abduction with 2 bags of cement and methylene blue.

The new spacer was fashioned using a size 3 × 150 mm stem molded with high viscosity cement containing 3 g vancomycin and 2.4 g tobramycin per bag. The real stem was impacted into position and trialed to ensure our ability to relocate the hip. The stem was then loosely cemented proximally and allowed to cure

to maintain appropriate anteversion. We then trialed the hip again and identified the correct head size, which provided adequate stability. This head was placed, and the hip was finally reduced.

Intraoperative imaging confirmed stable alignment without fracture (Fig. 3). Cultures grew *Bacillus* species. Postoperatively, the patient was managed with IV nafcillin (2 g every 4 h) and vancomycin (1.5 g every 12 h). The patient was made toe-touch weight-bearing with posterior hip precautions and received apixaban for venous thromboembolism prophylaxis.

Definitive reimplantation

After completion of 6 weeks of IV antibiotics, labs demonstrated a downtrending erythrocyte sedimentation rate and C-reactive protein within normal limits. The patient underwent re-aspiration, which was negative for infection. A total of 4 months after the revision spacer procedure, the patient underwent the second-stage procedure with definitive THA. After removal of the spacer components, a revision multi-hole acetabular component was implanted with multiple screws. A cerclage cable was placed to prevent fracture, then a monoblock diaphyseal engaging stem was placed, followed by antibiotic-

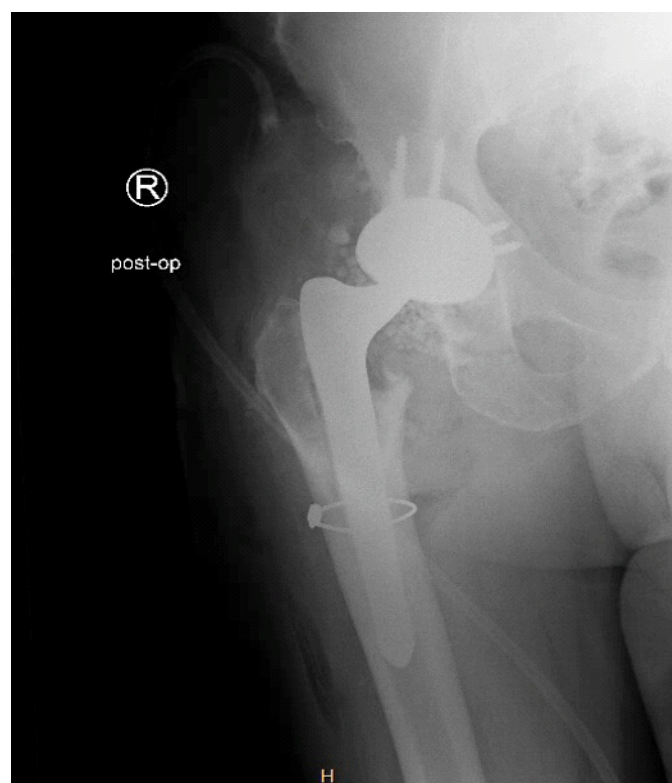

Figure 4: Post-operative radiograph after second-stage definitive THA. Post-operative AP radiograph demonstrating definitive implant including revision multi-hole acetabular component, cerclage cable, and a monoblock diaphyseal engaging stem.

infused beads. Post-operative radiographs demonstrated an anatomically aligned THA with no periprosthetic fracture (Fig. 4). At final follow-up, the patient was ambulating independently with minimal discomfort and no evidence of recurrent infection.

Discussion

Dislocation of an articulating antibiotic spacer is an uncommon but clinically significant complication during staged management of hip PJI. Articulating spacers are intended to preserve joint motion and have demonstrated higher treatment success rates as compared to static spacers [14]. Static spacers have also been associated with a significantly longer length of hospital stay [15].

Several factors can predispose towards spacer instability. Acetabular bone defects, abductor insufficiency, and history of previous instability events have all been implicated [5]. Spacer design itself is also important, as adequate femoral fixation and appropriate head/neck ratio can reduce the risk of complications [9]. Previous data have demonstrated that articulating spacers using real-component articulations (versus all-cement articulations) provide several advantages, including improved limb length restoration and higher rates of home discharge [16]. Using real-component articulating spacers allows surgeons to better optimize offset and leg length, which may minimize the risk of instability. In our case, significant acetabular deficiency likely played a role in early dislocation of the index spacer construct.

Closed reduction has been described but is frequently unsuccessful [12]. Historically, recurrent dislocation has sometimes led surgeons to perform Girdlestone resection arthroplasty to prevent repeat dislocation. However, this approach sacrifices limb length and function. When bone stock allows, revising the dislocated spacer can restore stability while maintaining limb mechanics [13]. In the present case, use of acetabular screw augmentation with a constrained liner and real-component articulation provided sufficient mechanical stability for a successful articulating spacer and eventual reimplantation.

Most reports of spacer dislocation involve the knee rather than the hip; thus, data on hip spacer instability remain limited. Mechanical complications across both hip and knee spacers are common, yet these complications do not always negatively impact the likelihood of successful reimplantation [17]. Practical strategies to minimize dislocation risk include appropriate spacer sizing, careful cementation, reinforcement of acetabular bone loss, and the selective use of constrained liners in high-risk settings. Hybrid screw-cement fixation, as described by Patel et al. and Pizzo et al., has shown promise in

improving construct stability in similar situations [18,19].

Proper techniques to provide stability cannot be ignored: surgeons must avoid placing the spacer in varus, restore appropriate leg lengths, and place both the femoral and acetabular components with appropriate anteversion. Adequate reaming of the acetabulum and use of an acetabular component within the spacer construct are also key considerations in order to achieve stability. In infection cases with early or persistent instability, surgeons must consider persistent infection, which may occur with inadequate initial debridement, lack of acetabular reaming, insufficient use of irrigation, and incorrectly tailored antibiotics.

Ultimately, infection control remains the foundation of successful two-stage exchange. The combination of nafcillin and vancomycin used in this case provided broad Gram-positive coverage, consistent with current recommendations for culture-directed therapy in PJI [3]. The absence of recurrent infection at follow-up highlights the value of combining stable mechanical reconstruction with effective antimicrobial management.

This case demonstrates that prompt recognition and revision of a dislocated spacer can preserve joint mechanics and enable successful second-stage reimplantation. Surgeons should maintain a high index of suspicion for early post-operative pain or instability, particularly in patients with poor bone stock or chronic infection, as timely intervention can lead to excellent functional outcomes and infection control.

Conclusion

Dislocation following hip articulating antibiotic spacer placement, though rare, is a serious complication that can jeopardize infection control and mechanical stability. Early recognition, surgical revision, and culture-directed antibiotics can restore joint integrity and allow for successful second-stage reimplantation. Attention to spacer design and acetabular support is critical to preventing recurrence.

Clinical Message

Hip articulating spacer dislocation is uncommon but should be suspected in patients with chronic infection or acetabular bone loss who develop acute pain or clinical signs of instability. Early diagnosis, timely revision, and appropriate antibiotic therapy can prevent morbidity and facilitate successful two-stage reconstruction.



Declaration of patient consent: The authors certify that they have obtained all appropriate patient consent forms. In the form, the patient has given the consent for his/ her images and other clinical information to be reported in the journal. The patient understands that his/ her names and initials will not be published and due efforts will be made to conceal their identity, but anonymity cannot be guaranteed.

Conflict of interest: Nil **Source of support:** None

References

- Blanco JF, Díaz A, Melchor FR, Da Casa C, Pescador D. Risk factors for periprosthetic joint infection after total knee arthroplasty. *Arch Orthop Trauma Surg* 2020;140:239-45.
- Lazic I, Scheele C, Pohlig F, Von Eisenhart-Rothe R, Suren C. Treatment options in PJI - is two-stage still gold standard? *J Orthop* 2021;23:180-4.
- Naoum S, Koutserimpas C, Pantekidis I, Giovanoulis V, Veizi E, Piagkou M, et al. Antimicrobial regimens in cement spacers for periprosthetic joint infections: A critical review. *Antibiotics (Basel)* 2024;13:772.
- Jung J, Schmid NV, Kelm J, Schmitt E, Anagnostakos K. Complications after spacer implantation in the treatment of hip joint infections. *Int J Med Sci* 2009;6:265-73.
- Sambri A, Fiore M, Rondinella C, Morante L, Paolucci A, Giannini C, et al. Mechanical complications of hip spacers: A systematic review of the literature. *Arch Orthop Trauma Surg* 2023;143:2341-53.
- Jacobs C, Christensen CP, Berend ME. Static and mobile antibiotic-impregnated cement spacers for the management of prosthetic joint infection. *J Am Acad Orthop Surg* 2009;17:356-68.
- Romanò CL, Romanò D, Logoluso N, Meani E. Long-stem versus short-stem preformed antibiotic-loaded cement spacers for two-stage revision of infected total hip arthroplasty. *Hip Int* 2010;20:26-33.
- Leunig M, Chosa E, Speck M, Ganz R. A cement spacer for two-stage revision of infected implants of the hip joint. *Int Orthop* 1998;22:209-14.
- Jones CW, Selemo N, Nocon A, Bostrom M, Westrich G, Sculco PK. The influence of spacer design on the rate of complications in two-stage revision hip arthroplasty. *J Arthroplasty* 2019;34:1201-6.
- Anagnostakos K, Fürst O, Kelm J. Antibiotic-impregnated PMMA hip spacers: Current status. *Acta Orthop* 2006;77:628-37.
- Bori G, García-Oltra E, Soriano A, Rios J, Gallart X, Garcia S. Dislocation of preformed antibiotic-loaded cement spacers (Spacer-G): Etiological factors and clinical prognosis. *J Arthroplasty* 2014;29:883-8.
- Faschingbauer M, Reichel H, Bieger R, Kappe T. Mechanical complications with one hundred and thirty eight (antibiotic-laden) cement spacers in the treatment of periprosthetic infection after total hip arthroplasty. *Int Orthop (SICOT)* 2015;39:989-94.
- Clemente A, Cavagnaro L, Russo A, Chiaroni F, Massè A, Burastero G. Spacer exchange in persistent periprosthetic joint infection: Microbiological evaluation and survivorship analysis. *Arch Orthop Trauma Surg* 2023;143:1361-70.
- Warwick HS, Tan TL, Weiser L, Shau DN, Barry JJ, Hansen EN. Comparison of static and articulating spacers after periprosthetic joint infection. *J Am Acad Orthop Surg Glob Res Rev* 2023;7:e22.00284.
- Nahas CR, Chalmers PN, Parvizi J, Sporer SM, Deirmengian GK, Chen AF, et al. Randomized trial of static and articulating spacers for treatment of the infected total hip arthroplasty. *J Arthroplasty* 2021;36:2171-7.
- Kugelman D, Roof M, Egol A, Guanche I, Chen AF, Schwarzkopf R, et al. Comparing articulating spacers for periprosthetic joint infection after primary total hip arthroplasty: All-cement versus real-component articulating spacers. *J Arthroplasty* 2022;37:S657-63.
- Costanzo J, McCahon J, Tokarski AT, Deirmengian C, Bridges T, Fliegel BE, et al. Mechanical complications of hip and knee spacers are common. *Cureus* 2023;15:e38496.
- Patel JN, Pizzo RA, Yoon RS, Liporace FA. Addressing antibiotic hip spacer instability via hybrid screw-cement fixation of a constrained liner and cement-rebar interface techniques: A technical narrative. *J Am Acad Orthop Surg* 2020;28:166-70.
- Pizzo RA, Patel JN, Viola A, Keller DM, Yoon RS, Liporace FA. Reducing dislocations of antibiotic hip spacers via hybrid cement-screw constrained liner fixation: A case series. *Hip Pelvis* 2020;32:207-13.

Conflict of Interest: Nil

Source of Support: Nil

Consent: The authors confirm that informed consent was obtained from the patient for publication of this article

How to Cite this Article

Khan I, Pumo TJ, Linton AA, Kugelman DN. Revision of a Dislocated Articulating Antibiotic Hip Spacer as an Alternative to Girdlestone Arthroplasty: A Case Report. *Journal of Orthopaedic Case Reports* 2026 June;16(06): 552-556.

