

# A Rare Case of Intra-articular Osteochondroma of the Femoral Neck: A Case Report

Yazan Hammad<sup>1</sup>, (Habib Alrahman) Ahmad Saleh<sup>2</sup>, Ibrahim F Aburumman<sup>2</sup>, Marwan Balasim<sup>2</sup>,  
Mohammad Ibrahim Al-Hyari<sup>2</sup>, Jihad Al-Ajlouni<sup>1</sup>

## Learning Point of the Article:

Intra articular Osteochondroma can restrict the hip range of motion and induce impingement. The risk of avascular necrosis, intra-operative femur neck fracture and sciatic nerve injury should be discussed with the patient.

## Abstract

**Introduction:** The osteochondroma (OC) is considered a benign tumor with long bone preference. It presents usually at the metaphyseal part of the bone, with rare cases of intra-articular origins especially in the hip joint. The presentation of such rare cases varies according to its site and mass effect, which may compress the adjacent nerves, tendon, or vascular structures.

The femoral neck OC carries a higher risk of femoral head vascular injury and necrosis, as well as sciatic nerve injury, which requires careful preoperative planning and intraoperative cautions. We report a rare case of intra-articular OC in the hip.

**Case Report:** A 28-year-old male, presented to our hospital, with complaints of right-side gluteal pain, decrease hip joint extension, and feeling of a hard mass for 2 years. The radiographic evaluation showed an osseous mass related posterior and inferior to the right femur neck, with cortical and medullary continuation, and cartilaginous cap on the magnetic resonance image. The suspicious was OC, and planned for excision and histopathological evaluation. The excision was done through lateral hip approach, and it was intra-articular with marked stretching of the joint capsule. Complete excision was done, as close as possible to the femoral neck cortex using saw and osteotomes, followed by prophylactic fixation using two cannulated screws. The histopathology reports confirm the diagnoses, and the patient started on hip range of motion and abductor strengthening exercises. Over a 4-month follow-up period the patient showed significant improvement in his hip range of motion.

**Conclusion:** The intra articular OC of the hip is as rare presentation of the OC, which carries the risks of avascular necrosis as well as nerve compression. Clinical suspicion, proper planning, and histopathological evaluation are needed for better results.

**Keywords:** Hip joint, intra-articular tumor, osteochondroma.

## Introduction

Osteochondroma (OC) is a common, benign tissue overgrowth that contains both bone and cartilage. It is usually an extra-articular lesion arising from the ends of the long bones. Based on radiological and pathological studies, it has been reported to be the most common benign tumor of the bone [1, 2]. The incidence rate in general population is approximately 0.9/100,000 [3] most of them in the second decade of life with a 2:1 male to female ratio [4].

OC is usually a metaphyseal tumor of the long bones that do not

involve the joints. The femur accounts for the majority of the cases, which is about 30% of the total and most of them, are distal lesions [5].

The presentation of the femoral neck OC usually depends on its size and site. It may present with mechanical restriction of the hip range of motion, due to the direct contact of the tumor against the acetabular rim or the ischium. It also causes mass effect which compress the adjacent structures such as tendons, muscles, vascular structures, and nerves, for example: compression of the sciatic nerve can present with lower back

Access this article online

Website:  
www.jocr.co.in

DOI:  
10.13107/jocr.2021.v11.i01.1978

## Author's Photo Gallery



Dr. Yazan Hammad



Dr. (Habib Alrahman) Ahmad Saleh



Dr. Ibrahim F Aburumman



Dr. Marwan Balasim



Dr. Mohammad Ibrahim Al-Hyari



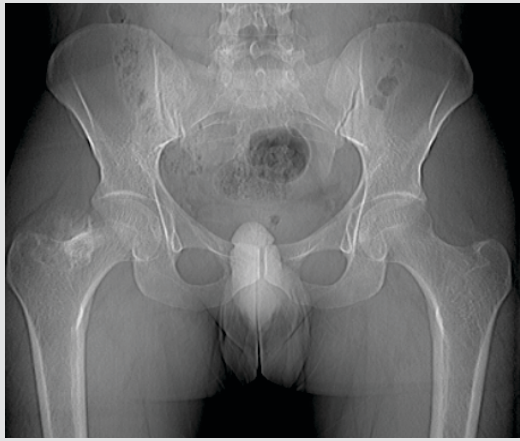
Dr. Jihad Al-Ajlouni

<sup>1</sup>Department of Orthopedic Surgery, University of Jordan and Jordan University Hospital, Amman-Jordan, 11942 Aljubeiha, Amman,  
<sup>2</sup>School of Medicine, The University of Jordan, Amman, Jordan, 11942 Aljubeiha, Amman.

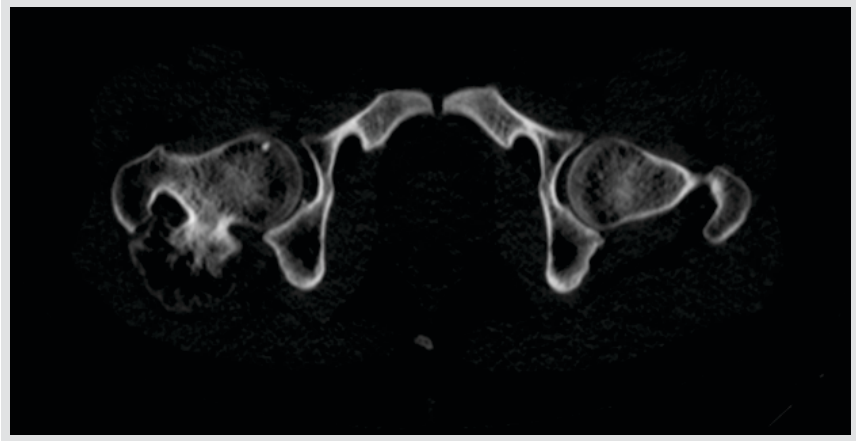
## Address of Correspondence:

Dr. Yazan Hammad,  
Department of Orthopedic Surgery, University of Jordan and Jordan University Hospital, 11942 Aljubeiha, Amman.  
E-mail: yazanshammad@yahoo.com





**Figure 1:** Pelvic radiography at presentation, showed an osseous mass related to the right femur neck.



**Figure 2:** Computed tomography scan axial view showed a right posterior-inferior osseous mass with cortical and medullary continuity with the femur neck.

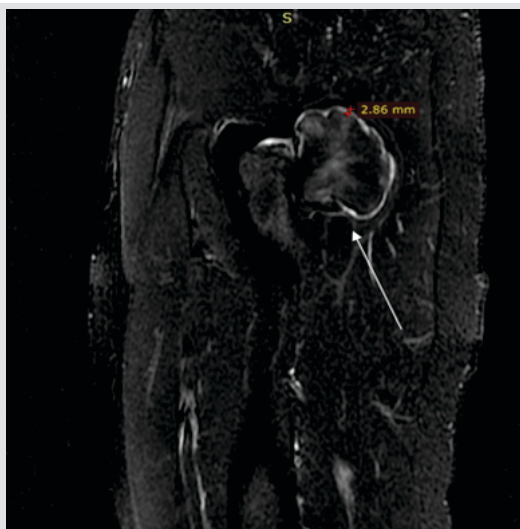
and leg pain. This scenario is rare and presents in less than 1% of all cases [6]. The surgical resection of the intra-articular OC is difficult regarding to its high risk of avascular necrosis [7]. In this study, we report a rare case of intra-articular OC of femoral neck and its surgical resection, histopathological confirmation, and patient rehabilitation.

### Case Report

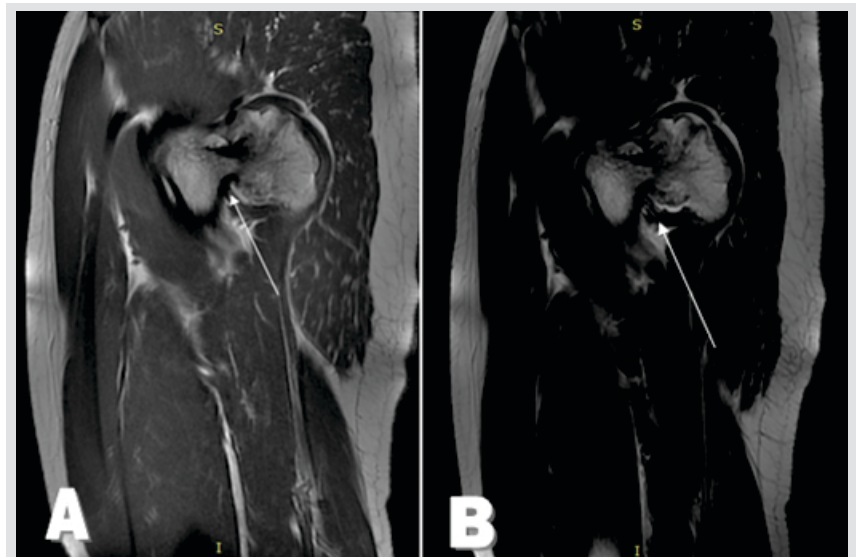
This report presents a case of 28-year-old male, who was referred to the Department of Orthopedic Surgery in the Jordan University Hospital complaining of right gluteal pain and feeling of unusual hard mass for 2 years. The pain was insidious and increased over time, he described it as a burning sensation that radiates from the gluteal area to the posterior side of the thigh, which was exacerbated on walking but relief with rest and there was no night pain. He also reported a progressive limitation of right hip extension which significantly interfered with his daily activities.

Through the 2 years before the presentation, the patient was assessed by multiple general physicians one of them diagnosed him as a muscle stiffness and another one ordered a lumbosacral magnetic resonance image (MRI) to rule out disc prolapse. For that, the patient had been receiving several courses of para spinal muscle strengthening physical therapy and core body exercises, but with minimal benefit. The patient visited a general orthopedic surgeon 1 month before the presentation which ordered a pelvic radiography that showed an osseous mass related to the right femur neck (Fig. 1). Therefore, the patient was transferred to our hospital for further evaluation.

On physical examination, there were multiple tender points in the gluteal area and over the greater trochanter, with restricted passive and active extension of the right hip joint, but there was no weakness and symmetric power 5/5 in both lower limbs. The results of the laboratory tests (complete blood count, erythrocyte sedimentation rate, C-reactive protein, kidney function test, and electrolyte) were within normal limits.

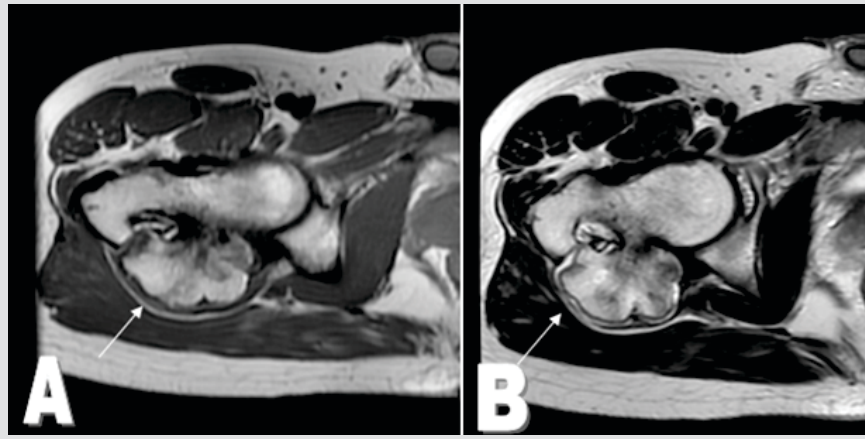


**Figure 3:** Magnetic resonance image – sagittal short tau inversion recovery fast spin-echo (SAG STIR fast IR) showed the posterior relation of the osteochondroma to the femur neck (arrow), and the high intensity cap thickness which goes with the diagnosis of osteochondroma.

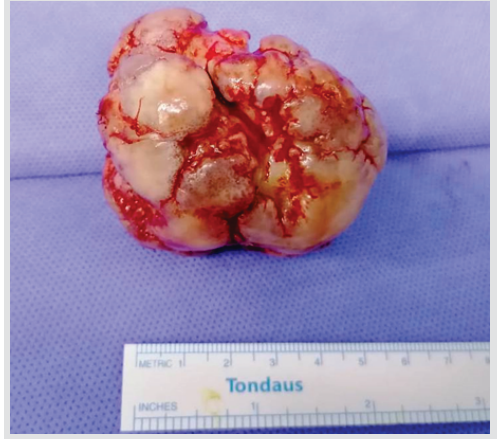


**Figure 4:** Magnetic resonance image sagittal view T1 in (A) and T2 in (B), showing the posterior relationship of the osteochondroma to the femur neck.





**Figure 5:** Magnetic resonance image – axial views – showing the cartilage cape low enhancement in T1 (a) and high enhancement in T2 (b).



**Figure 6:** The osseous mass gross appearance after resection, showing the cartilage coverage, it measures around 6 cm.

Computed tomography scan (CT scan) was ordered and showed a right femoral neck posterior-inferior osseous mass with cortical and medullary continuity on the axial view (Fig. 2). MRI – sagittal short tau inversion recovery fast spin-echo (SAG STIR fast IR) showed the posterior relation of the OC to the femur neck, and the high intensity cap which goes with the diagnosis of OC (Fig. 3). MRI – sagittal view T1 in (a) and T2 in (b), showing the posterior relationship of the OC to the right femur neck (Fig. 4). MRI – axial views show the cartilage cape low enhancement in T1(a) and high enhancement in T2(b) (Fig. 5).

The plan was to remove the mass, and the risks of intra-operative femur neck fracture, sciatic nerve injury and incomplete resection were discussed with the patient. The operation was in lateral position through a lateral approach to the hip. The hip capsule was stretched and the mass was intra capsular in posterior relation to the femur neck with a stalk. It was removed as close as possible to the femur neck using the saw and osteotome. It was completely removed without a fracture to the femur neck (Fig. 6, 7). Then, we fixed the femur neck with

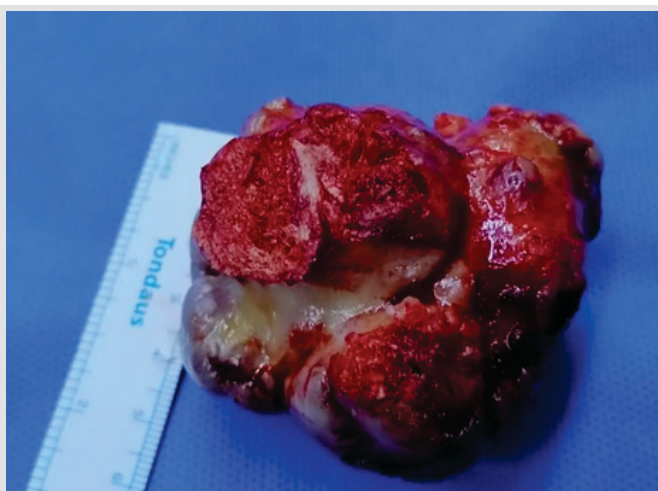
two fully threaded cannulated screws as a prophylactic fixation (Fig. 8, 9). The mass was sent for histopathology evaluation (Fig. 10), which confirms the diagnosis of OC.

The patient started full weight bearing and hip range of motion rehabilitation program in supine and prone position directly on the next day of the operation. After 4-months of out-patient follow ups, the patient reported a significant improvement in his hip extension and a complete resolution of the burning sensation in his gluteal area.

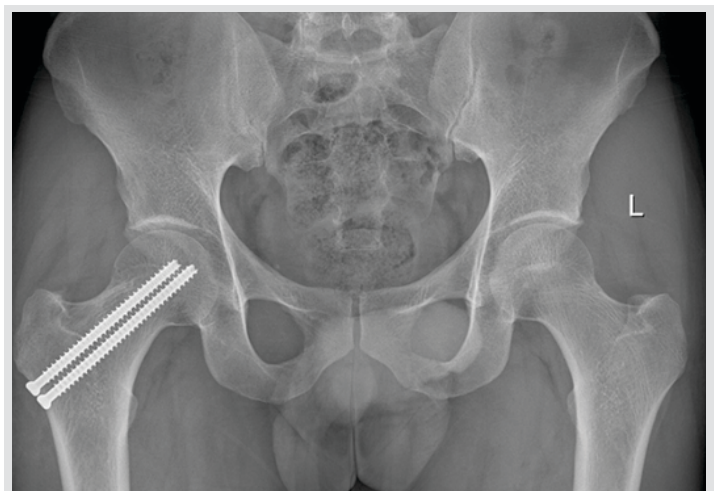
### Discussion

OCs are usually thought to be benign bone tumors although they are more correctly thought to be a developmental anomaly [8]. They present as a solitary (85% of cases) or multiple lesions in the context of hereditary multiple exostosis (in 15% of case), commonly in an autosomal dominant manner [9].

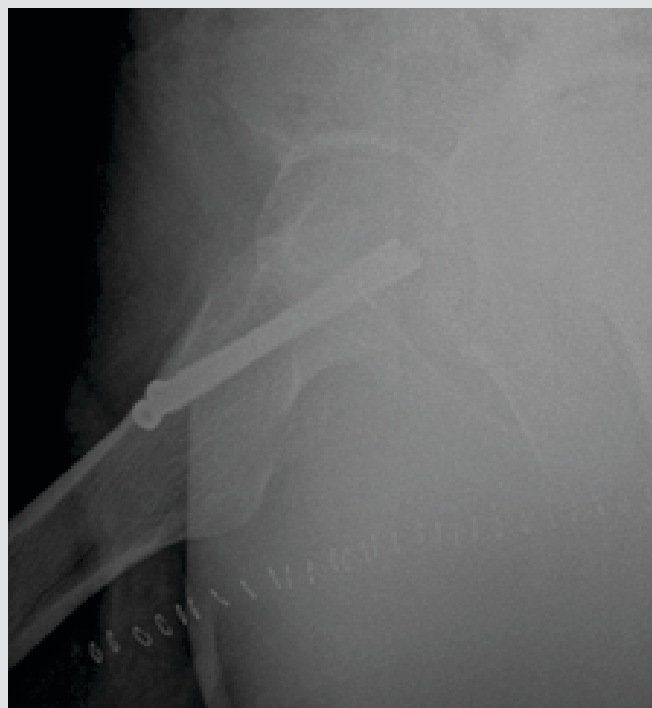
Femoral neck OC relatively rare as it is a typical for OC to be an intra-articular lesion [10]. It could be associated with snapping hip [11], trochanteric bursitis, sciatic nerve compression [12,



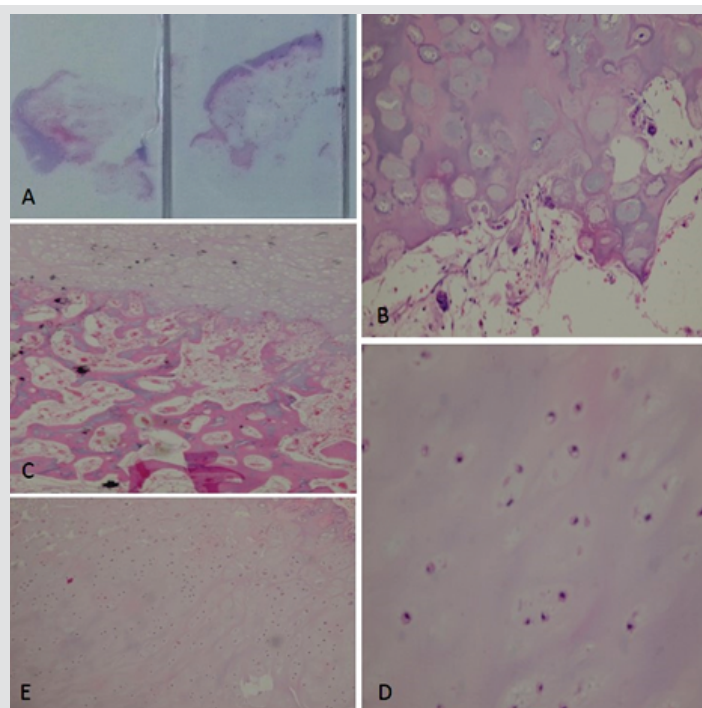
**Figure 7:** The osseous mass gross appearance after resection, showing its (stalk) which was attached on and in continuation with the femur neck cortex.



**Figure 8:** Post-operative X-ray AP view of the pelvis showing right hip two fully threaded cannulated screws with complete resection of the osteochondroma without fracture.



**Figure 9:** Post-operative X-ray lateral view of the right hip showing two fully threaded cannulated screws with complete resection of the osteochondroma without fracture.



**Figure 10:** Sections from the lesion demonstrate a cartilaginous cap with underlying bone (a and b) exhibiting areas of endochondral ossification with growth plate-like areas (c and d). The chondrocytes are bland looking, with no morphologic evidence of increased cellularity, pleomorphism, enlargement, or mitosis (e).

13], pedicle fracture [14, 15] or femoroacetabular impingement [16, 17].

Femoral neck OC leads to a mechanical block and pain if there is a direct contact of the enlarged femoral neck against the ischium or the acetabulum [17]. Neurovascular compression is rare and occurs in <1% of all cases of OCs [6]. In our patient, it was associated with gluteal pain, described it as a burning sensation that radiates from the gluteal area to the posterior side of the thigh with a hard mass feeling.

The choice of the proper surgical approach to femoral neck OC is often difficult, as it should reflect a balance between complete removal and the risk of neurovascular injury or intra operative fracture. The surgeon can choose the most effective approach to help in removing the tumor safely without complications [18]. In our patient, we used the lateral approach. The OC was in posterior relation to the femur neck and it was pedunculated with a high risk for intraoperative fracture. We used the saw and osteotomes to remove it as close as possible to the femur neck and we performed a prophylactic fixation of the femoral neck

after that with two fully threaded cannulated screws.

The reported complications of the intra-articular OC were varied as sciatic nerve compression pre-operative [13] and impingement of the tumor against the ischium in flexion and external rotation [19], which suggests careful pre-operative examination and CT/MRI evaluation of the nerve compression. These complications, the clinical presentations, and authors notes which were reported in previous similar cases are reviewed in (Table-1).

A recent study showed that patients who did the prophylactic fixation of femur neck intra-operatively have better outcomes than patients who did it in a separate session after the femur neck fracture [20]. Another case study supports the use of arthroscopic excision when available to prevent the risk of avascular necrosis of the femoral head, especially when associated with synovial OC [21].

The patient started on a rehabilitation program after the surgery. It consisted of hip range of motion exercises and hip abductor muscle strengthening. During the follow-up period over 4 months, there was significant improvement in the hip extension and resolution of the gluteal pain.

## Conclusion

OC is the most common benign bone tumor. However, being intra-articular OC of femoral neck makes it a rare case that needs a careful evaluation and treatment as a risk of femoral neck fracture and neurovascular compromise which needs

Author	Age, gender	Location	Surgical approach/treatment	Author's notes /Recommendations
Z. J. Liu et al, .... [22]	6, Male	Posterior femur neck	Lateral Approach excision	Marginal excision with histopathological identification is the treatment of choice
B. G. Jones et al, ... [23]	18	Posteroinferior femur neck with low energy hip dislocation	Posterior Approach excision	OC can be a cause of chronic impingement, sub laxation and ends as hip dislocation.
Waqas Hussain et al, .. [24]	24, Male	Posterior femur neck	posterolateral approach Excision	There is a relation between proximal femur OC and Impingement. Their patient needs post excision arthroscopic femoroacetabular osteochondroplasty, and labral repair
Kimberly Yu [12]	39, Male	Posterior femur neck	posterior approach Excision	The association between OC and sciatic neuropathy of the peroneal and tibial branches



detailed radiological workup to determine its size and site in relation to femoral neck accurately.

Femoral neck OC can present with restricted hip motion, feeling of a hard mass in one side, and gluteal pain that may interfere with daily activities.

### Clinical Message

OC must be one of the differentials in a young patient who presents with restricted hip range of motion, feeling of a hard mass in one side and insidious progressive groin pain. After radiological workup, if the OC seems to be in the femoral neck, there will be further steps in evaluation and treatment to avoid some serious complications such as femoral neck fracture.

### References

1. Canella P, Gardin F, Borriani S. Exostosis development, evolution and relationship. *Ital J Orthop Traumatol* 1981;7:293-8.
2. Porter DE, Benson MK, Hosney GA. The hip in hereditary multiple exostoses. *J Bone Joint Surg Br* 2001;83:988-95.
3. Kitsoulis P, Galani V, Stefanaki K, Paraskevas G, Karatzias G, Agnantis NJ, et al. Osteochondromas: Review of the clinical, radiological and pathological features. *In Vivo* 2008;22:633-46.
4. Haaga JR, Dogra VS, Frosting M, Gilkeson RC, Sundaram M. A case report of osteochondroma with unusual clinical and imaging presentation. *Adv Biomed Res* 2009;2:2134-5.
5. Douis H, Saifuddin A. The imaging of cartilaginous bone tumours. I. Benign lesions. *Skeletal Radiol* 2012;41:1195-212.
6. Paik NJ, Han TR, Lim SJ. Multiple peripheral nerve compressions related to malignantly transformed hereditary multiple exostoses. *Muscle Nerve* 2000;23:1290-4.
7. Feeley BT, Kelly BT. Arthroscopic management of an intraarticular osteochondroma of the hip. *Orthop Rev (Pavia)* 2009;1:e2.
8. Mehta M, White LM, Knapp T, Kandel RA, Wunder JS, Bell RS. MR imaging of symptomatic osteochondromas with pathological correlation. *Skeletal Radiol* 1998;27:427-33.
9. Singh R, Jain M, Siwach R, Rohilla S, Sen R, Kaur K. Large para-articular osteochondroma of the knee joint: A case report. *Acta Orthop Traumatol Turc* 2012;46:139-43.
10. Alqarni AD. Femoral neck osteochondroma in an athlete: A case report and literature review. *Saudi J Sports Med* 2014;14:158-60.
11. Inoue S, Noguchi Y, Mae T, Rikimaru S, Hotokezaka S. An external snapping hip caused by osteochondroma of the proximal femur. *Mod Rheumatol* 2005;15:432-4.
12. Yu K, Meehan JP, Fritz A, Jamali AA. Osteochondroma of the femoral neck: A rare cause of sciatic nerve compression. *Orthopedics* 2010;33:625-6.
13. Ilica AT, Yasar E, Sanal HT, Duran C, Guvenc I. Sciatic nerve compression due to femoral neck osteochondroma: MDCT and MR findings. *Clin Rheumatol* 2008;27:403-4.
14. Robbins MM, Kuo S, Epstein R. Non-traumatic fracture of an osteochondroma mimicking malignant degeneration in an adult with hereditary multiple exostoses. *Radiol Case Rep* 2008;3:99.
15. Carpintero P, León F, Zafra M, Montero M, Berral FJ. Fractures of osteochondroma during physical exercise. *Am J Sports Med* 2003;31:1003-6.
16. Hussain W, Avedian R, Terry M, Peabody T. Solitary osteochondroma of the proximal femur and femoral acetabular impingement. *Orthopedics* 2010;33:51.
17. Siebenrock KA, Ganz R. Osteochondroma of the femoral neck. *Clin Orthop Relat Res* 2002;394:211-8.
18. Makhdom AM, Jiang F, Hamdy RC, Benaroch TE, Lavigne M, Saran N. Hip joint osteochondroma: Systematic review of the literature and report of three further cases. *Adv Orthop* 2014;2014:180254.
19. Kanauchi T, Suganuma J, Kawasaki T, Mochizuki R, Inoue Y, Uchikawa S, et al. Fracture of an osteochondroma of the femoral neck caused by impingement against the ischium. *Orthopedics* 2012;35:e1438-41.
20. Arvinus C, Parra JL, Mateo LS, Maroto RG, Borrego AF, Stern LL. Benefits of early intramedullary nailing in femoral metastases. *Int Orthop* 2014;38:129-32.
21. Wang SI, Park EH, Yoon SJ and Kim JR. Intra-articular osteochondroma of the posteroinferior femoral neck associated with hip joint osteochondromatosis: A case report. *Mol Clin Oncol* 2017;7:915-8.
22. Z. J. Liu, Q. Zhao, and L. J. Zhang, "Extraskeletal osteochondroma near the hip: a pediatric case," *Journal of Pediatric Orthopaedics B*, vol. 19, no. 6, pp. 524–528, 2010.
23. B. G. Jones and A. W. G. Kinninmonth, "Low-energy hip dislocation in the young," *Journal of Trauma*, vol. 58, no. 3,





pp. 638–639, 2005.

24. W. Hussain, R. Avedian, M. Terry, and T. Peabody, “Solitary

osteochondroma of the proximal femur and femoral acetabular impingement,” *Orthopedics*, vol. 33, no. 1, p. 51, 2010.

**Conflict of Interest:** Nil

**Source of Support:** Nil

**Consent:** The authors confirm that informed consent was obtained from the patient for publication of this case report

**How to Cite this Article**

Hammad Y, Saleh A, Aburumman IF, Balasim M, Al-Hyari MI, Al-Ajlouni J. A Rare Case of Intra-articular Osteochondroma of the Femoral Neck: A Case Report. *Journal of Orthopaedic Case Reports* 2021 January; 11(1): 91-96.