

# Cervical Disk Arthroplasty in a Collegiate Football Player

James Satalich<sup>1</sup>, Phillip Wyatt<sup>2</sup>, Conor O'Neill<sup>1</sup>, Prakasam Kalluri<sup>1</sup>, Robert O'Connell<sup>1</sup>

## Learning Point of the Article:

Cervical disc arthroplasty is a reliable and safe option in a high level athletes to return to sport after injury.

## Abstract

**Introduction:** While the body of research investigating anterior cervical disk fusion (ACDF) for symptomatic cervical disk herniations in high-level athletes is large, evidence for cervical disk replacement (CDR) is sparse. The amount of patients able to return to sport after an ACDF is estimated to be 73.5%, causing surgeons to search for alternatives with better outcomes in this population. This case report describes the successful treatment of a symptomatic collegiate American football player with C6–C7 disk herniation and C5–C6 central canal stenosis.

**Case Report:** This is a 21-year-old American football safety who underwent a C5–6 and C6–7 cervical disk arthroplasty. Three weeks postoperatively, the patient demonstrated nearly complete resolution of weakness, full resolution of radiculopathy, and normal cervical range of motion in all planes.

**Conclusion:** The CDR may be considered as an alternative to the ACDF in the treatment of high-level contact athletes. Compared to the ACDF, CDR has been shown in prior studies to decrease the long-term risk of adjacent segment degeneration. Future studies comparing ACDF to CDR in the high-level contact sport athlete population are needed. CDR appears to be a promising surgical intervention for symptomatic patients in this population.

**Keywords:** Cervical disk replacement, anterior cervical disk fusion, contact sports, cervical disk arthroplasty.

## Introduction

Cervical disk replacement (CDR) and anterior cervical disk fusion (ACDF) have both been used to treat cervical disk disease in symptomatic high-level athletes [1, 2, 3, 4]. Given the imperative need for full cervical range of motion in contact sports such as American football, CDR has been used with increasing popularity to avoid the single- and sometimes multi-level cervical fusion associated with ACDF. CDR has been shown to maintain physiologic distribution of range of motion throughout the cervical spine. In contrast, ACDF is associated with increased range of motion contribution from adjacent segments (in relation to the fusion) to maintain gross cervical mobility [5].

This increased motion in the adjacent segment has been associated with adjacent segment degeneration, a long-term complication that CDR has been shown to mitigate [6, 7, 8]. There have been other case reports of high-level athletes undergoing CDR with good outcomes [4, 9]. This report demonstrates further success of CDR in a collegiate American football player.

## Case Report

The patient presented as a right hand-dominant 21-year-old male collegiate football player (safety position) with a 7-day

Access this article online

Website:  
www.jocr.co.in

DOI:  
10.13107/jocr.2022.v12.i09.3008

## Author's Photo Gallery



Dr. James Satalich



Dr. Phillip Wyatt



Dr. Conor O'Neill



Dr. Prakasam Kalluri



Dr. Robert O'Connell

<sup>1</sup>Department of Orthopaedic Surgery, Virginia Commonwealth University Hospital, Richmond, Virginia,

<sup>2</sup>Department of Orthopaedics, VCU Medical School, Virginia Commonwealth University Hospital, Richmond, Virginia.

### Address of Correspondence:

Dr. James Satalich,

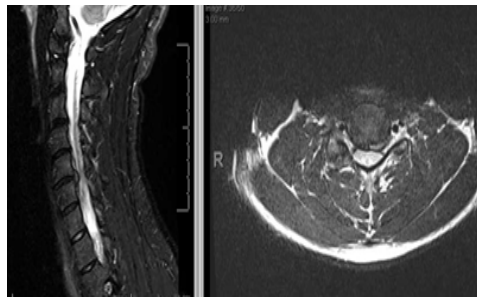
Department of Orthopaedic Surgery, Virginia Commonwealth University Hospital, Richmond, Virginia.

E-mail: james.satalich@vcuhealth.org

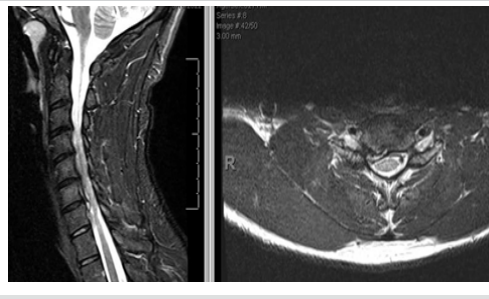
Submitted: 26/07/2022; Review: 15/08/2022; Accepted: August 2022; Published: September 2022

DOI:10.13107/jocr.2022.v12.i09.3008

This is an open access journal, and articles are distributed under the terms of the Creative Commons Attribution-NonCommercial-ShareAlike 4.0 License <https://creativecommons.org/licenses/by-nc-sa/4.0/>, which allows others to remix, tweak, and build upon the work non-commercially, as long as appropriate credit is given and the new creations are licensed under the identical terms



**Figure 1:** C5–6 with moderate spinal canal stenosis, cord deformity, and cord edema signal, moderate left, and mild right foraminal stenosis.



**Figure 2:** C6–7 right paracentral and right foraminal disk herniation causing mild spinal canal stenosis, cord deformity, and severe right foraminal stenosis.

Subsequent follow-up with a fellowship-trained orthopedic spine surgeon revealed improving symptoms, but now with 4+/5 right wrist extension strength and positive Hoffmann's bilaterally. At this time, it was recommended that the patient not return to play due to concern regarding the cord edema.

Over the course of the next month and a half, his numbness and tingling worsened with prolonged

history of the right-sided muscle spasms, aching, and numbness/tingling that radiated to his right index and middle finger. The symptoms appeared after a weight training session. Medical history was significant for a right ulna percutaneous pinning 8 years ago due to a previous fracture. Athletic training staff at his school had attempted therapeutic ultrasound and dry needling with no relief. His pain and spasms were in the posterior shoulder region.

On physical examination, the patient demonstrated full range of motion bilaterally with tenderness to palpation in the paraspinal muscles as well as rhomboids with no palpable trigger point. Spurling's test was positive, recreating his pain in the posterior shoulder blade. Shoulder range of motion was within normal limits and 5/5 strength was observed throughout both upper extremities. Right shoulder and cervical X-rays revealed no acute osseous abnormalities with slight loss of cervical lordosis. At his first visit, the patient was given a Medrol Dospak (methylprednisolone 4 mg) to address suspected cervical radiculopathy.

Eight days later, an MRI was performed of the cervical spine which revealed (1) degenerative changes of the cervical spine most prominent at C5–6 with moderate spinal canal stenosis, cord deformity and cord edema signal, moderate left, mild right foraminal stenosis, and (2) at C6–7, right paracentral and right foraminal disk herniation causing mild spinal canal stenosis, cord deformity, and severe right foraminal stenosis (Fig. 1, 2).

sitting, and he was starting to notice difficulty with push-ups due to weakness in his right pectoralis major muscle. He presented for a follow-up visit now ~3 months post injury. On physical examination, he demonstrated 4/5 right biceps and right triceps strength. In addition, finger extensors were 4/5 bilaterally. Sensory examination showed no focal deficits in the upper extremities. At this visit, surgical intervention was recommended and described as C5–6 and C6–7 anterior discectomy with arthroplasty with possible fusion with allograft plating.

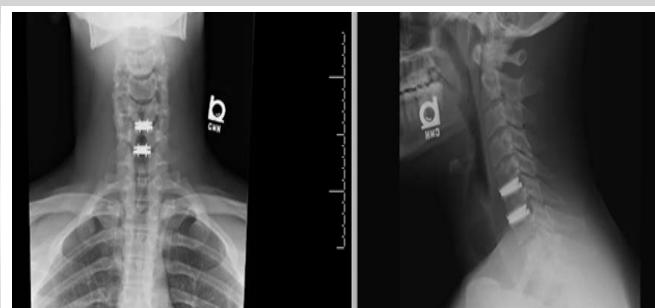A C5–6 and C6–7 anterior discectomy and arthroplasty were performed exactly 3 months after the initial office visit by a fellowship-trained spine surgeon (Fig. 3).

Three weeks postoperatively, the patient presented with resolution of arm pain, numbness, or tingling, taking ibuprofen as needed for pain related to surgery site. Upper extremity motor examination was intact bilaterally C5–T1 except mild wrist flexor weakness bilaterally (5–/5). Sensory examination revealed intact sensation bilaterally. Cervical range of motion in all planes (bilateral rotation, lateral bending, flexion, and extension) was normal and painless. Post-operative X-rays demonstrated the C5–7 disk arthroplasties in good position.

## Discussion

This case report describes a rare injury within the collegiate football player population that was successfully treated with CDR. Cervical spine injuries are common in NCAA collegiate football athletes with nearly 7500 such injuries reported from 2009 to 2014. However, only a small fraction of these (0.02%) were related to cervical disk injury. An even smaller percentage (0.01%) of these injuries involved central spinal stenosis [10].

ACDF is a procedure that is well-researched in high-level contact athletes, with mostly excellent results [1, 2, 11]. A few studies have assessed the efficacy of CDR with excellent results and no setbacks in returning to play [9, 11, 12]. This report



**Figure 3:** Cervical disk arthroplasty at C5–C6 and C6–C7.

shows a quick resolution of radiculopathy in a young collegiate football player. This case study demonstrates that CDR is an effective surgery for cervical disk disease in contact athletes and should be considered in this population.

### Conclusion

The small, yet growing body of literature supporting CDR for high-level athletes is promising. Its effectiveness and potential to decrease long-term complications, as in adjacent segment degeneration, make it a good alternative to ACDF in this

population. However, further comparative studies are needed to determine the most effective surgical intervention in the symptomatic high-level contact athlete population.

### Clinical Message

Cervical disk arthroplasty is a viable treatment option for cervical disk herniation in high-level athletes. Long-term studies and data are recommended.

**Declaration of patient consent:** The authors certify that they have obtained all appropriate patient consent forms. In the form, the patient has given the consent for his/ her images and other clinical information to be reported in the journal. The patient understands that his/ her names and initials will not be published and due efforts will be made to conceal their identity, but anonymity cannot be guaranteed.

**Conflict of interest:** Nil **Source of support:** None

### References

1. Leider J, Piche JD, Khan M, Aleem I. Return-to-play outcomes in elite athletes after cervical spine surgery: A systematic review. *Sports Health* 2021;13:437-45.
2. McAnany SJ, Overlay S, Andelman S, Patterson DC, Cho SK, Qureshi S, et al. Return to play in elite contact athletes after anterior cervical discectomy and fusion: A meta-analysis. *Global Spine J* 2017;7:552-9.
3. Watkins RG 4th, Chang D, Watkins RG 3rd. Return to play after anterior cervical discectomy and fusion in professional athletes. *Orthop J Sports Med* 2018;6:2325967118779672.
4. Lindi-Sugino R, Hartl R, Klezl Z. Cervical arthroplasty in a professional kick-boxing fighter, 7 years follow-up. *Acta Ortop Mex* 2021;35:282-5.
5. Chang SW, Bohl MA, Kelly BP, Wade C. The segmental distribution of cervical range of motion: A comparison of ACDF versus TDR-C. *J Clin Neurosci* 2018;57:185-93.
6. Xu S, Liang Y, Zhu Z, Qian Y, Liu H. Adjacent segment degeneration or disease after cervical total disc replacement: A meta-analysis of randomized controlled trials. *J Orthop Surg* 2018;13:244.
7. Steinberger J, Qureshi S. Cervical disc replacement. *Neurosurg Clin N Am* 2020;31:73-9.
8. Limanówka B, Sagan L. Changes in cervical range of motion following anterior cervical discectomy with fusion-preliminary results. *Neurol Neurochir Pol* 2020;54:568-75.
9. Satalich J, Carter S, Fisichella A, Widmeyer J, Kalluri P, Vap A. Return to football after a cervical disk arthroplasty: A case report. *J Orthop Case Rep* 2022;12:19-21.
10. Chung AS, Makovicka JL, Hassebrock JD, Patel KA, Tummala SV, Deckey DG, et al. Epidemiology of cervical injuries in NCAA football players. *Spine (Phila Pa 1976)* 2019;44:848-54.
11. Mai HT, Chun DS, Schneider AD, Hecht AC, Maroon JC, Hsu WK. The difference in clinical outcomes after anterior cervical fusion, disk replacement, and foraminotomy in professional athletes. *Clin Spine Surg* 2018;31:E80-4.
12. Reinke A, Behr M, Preuss A, Villard J, Meyer B, Ringel F. Return to sports after cervical total disc replacement. *World Neurosurg* 2017;97:241-6.

**Conflict of Interest:** Nil

**Source of Support:** Nil

**Consent:** The authors confirm that informed consent was obtained from the patient for publication of this case report

### How to Cite this Article

Satalich J, Wyatt P, O'Neill C, Kalluri P, O'Connell R. Cervical Disk Arthroplasty in a Collegiate Football Player. *Journal of Orthopaedic Case Reports* 2022 September;12(9): 41-43.

