Case Report | Journal of Orthopaedic Case Reports 2026 October:16(10):Page 52-56

Giant Cell Tumor of the Distal Phalanx of the Great Toe: Case Report

Evani Anirudh Sarma[1], Mantu Jain[1], Harshit Mishra[1], A Muhammad Zainul Aabid[1], Shahnawaz Khan[1], Jagatjyoti Panda[2]

Learning Point of the Article:

Giant cell tumor of the distal phalanx of the great toe is an exceptionally rare presentation of GCT. They show more aggressive behavior and higher recurrence rates than those in long bones. Amputation remains a definitive and reliable option in recurrent or aggressive lesions, with acceptable functional outcomes despite biomechanical compromise.

Abstract

Introduction: Giant cell tumor (GCT) of bone is a benign but locally aggressive neoplasm that most commonly involves the epiphyseal–metaphyseal regions of long bones. Involvement of the foot is rare, and occurrence in the distal phalanx of the great toe is exceptionally uncommon. GCTs arising in small bones are known to exhibit more aggressive behavior and higher recurrence rates than those in long bones, posing challenges for management.

Case Report: We report the case of a young adult presenting with progressive pain and swelling of the great toe. Radiographs and magnetic resonance imaging demonstrated an expansile osteolytic lesion of the distal phalanx with cortical destruction and soft-tissue extension. Histopathological examination following open biopsy confirmed the diagnosis of GCT of bone. The patient received three doses of denosumab, followed by surgical resection of the distal phalanx with the intent of limb preservation. The post-operative course was uneventful. At the 1-year follow-up, the patient remains symptom-free, with no evidence of recurrence.

Conclusion: GCT of the distal phalanx of the great toe is a rare entity with aggressive local behavior. Early diagnosis, histopathological confirmation, and appropriate surgical planning are essential for achieving local control. Limb-preserving strategies can be considered in selected cases, but vigilant follow-up is mandatory due to the high risk of recurrence.

Keywords: Giant cell tumor, great toe, amputation.

Introduction

Giant cell tumor (GCT) of bone is a benign but locally aggressive primary osseous neoplasm, comprising approximately 5–6% of all primary bone tumors and nearly 20% of benign bone tumors [1]. It most commonly arises in the epiphyseal–metaphyseal region of long bones in skeletally mature individuals, particularly around the knee and distal radius [1,2]. Involvement of the bones of the foot is distinctly uncommon, constituting less than 1% of reported cases, and phalangeal involvement is sporadic [3].

GCTs occurring in the small bones of the hand and foot are known to demonstrate more aggressive biological behavior compared to those arising in long bones. These tumors tend to present at a younger age, show rapid cortical destruction, and have a higher propensity for local recurrence [4]. Among these,

Access this article online

Website: www.jocr.co.in

DOI: https://doi.org/10.13107/jocr.2026.v16.i10.8184

Author's Photo Gallery

Dr. Evani Anirudh Sarma

Dr. Mantu Jain

Dr. Harshit Mishra

Dr. A Muhammad Zainul Aabid

Dr. Shahnawaz Khan

Dr. Jagatjyoti Panda

[1]Department of Orthopaedics, All India Institute of Medical Sciences, Bhubaneswar, Odisha, India,
[2]Research Associate, Department of Orthopaedics, All India Institute of Medical Sciences, Bhubaneswar, Odisha, India.

Address of Correspondence:
Dr. Mantu Jain,
Department of Orthopedics, All India Institute of Medical Sciences, Bhubaneswar, Odisha, India.
E-mail: montu_jn@yahoo.com

Submitted: 09/07/2026; Review: 22/08/2026; Accepted: September 2026; Published: October 2026

DOI: https://doi.org/10.13107/jocr.2026.v16.i10.8184

© The Author(s). 2026 Open Access. This article is distributed under the terms of the Creative Commons Attribution 4.0 International License (https://creativecommons.org/licenses/by-nc/4.0/), which permits unrestricted use, distribution, and non-commercial reproduction in any medium, provided you give appropriate credit to the original author(s) and the source, provide a link to the Creative Commons license, and indicate if changes were made. The Creative Commons Public Domain Dedication waiver (http://creativecommons.org/publicdomain/zero/1.0/) applies to the data made available in this article, unless otherwise stated.

Figure 1: Clinical photographs of the affected great toe showing a fusiform, globular enlargement of the distal great toe with stretched, shiny skin, areas of hyperkeratosis and superficial ulceration, and distortion of the nail plate, indicating a locally aggressive lesion with cutaneous compromise.

involvement of the distal phalanx of the great toe is exceedingly rare, with only isolated case reports documented in the literature [3].

Given the rarity of this presentation, there is no consensus on optimal management. While intralesional curettage may be adequate for less aggressive lesions, recurrence rates in small-bone GCTs are significantly higher, often requiring wide excision or amputation to achieve appropriate local control [5].

We report a rare case of GCT of the distal phalanx of the great toe, initially managed with biopsy and distal phalanx resection, which subsequently recurred and required amputation of the great toe.

Case Report

A young adult female patient in her early twenties presented with progressive pain and swelling involving the distal aspect of the great toe. The symptoms had gradually progressed over several months, without any antecedent trauma or infection. Clinical examination revealed a firm, tender swelling of the distal great

Figure 2: Anteroposterior and lateral radiograph of the foot demonstrating an expansile osteolytic lesion involving the distal phalanx of the great toe, with cortical thinning and destruction, without matrix calcification or periosteal reaction (a); Computed tomography scan of the foot showing ballooning expansion of the distal phalanx, confirming the aggressive lytic nature of the lesion and loss of normal bony architecture (b); Sagittal MRI of the great toe demonstrating a lobulated lesion involving the distal phalanx, with extension up to the subungual region and soft tissue involvement, consistent with a locally aggressive bone tumor (c); Coronal MRI showing replacement of the distal phalanx by tumor tissue with adjacent soft tissue extension, while the proximal phalanx and metatarsophalangeal joint appear preserved (d). MRI: Magnetic resonance imaging.

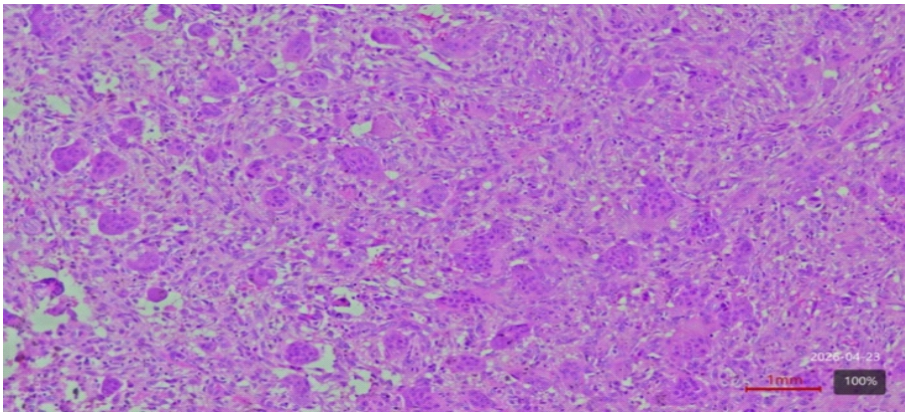

Figure 3: Histopathological section (H and E stain) showing features of a giant cell tumor of bone. Numerous uniformly distributed multinucleated osteoclast-like giant cells are seen dispersed within a background of mononuclear stromal cells. The stromal cells are oval to spindle-shaped with bland nuclei, representing the neoplastic component. Areas of hemorrhage and focal stromal cellularity are also evident (original magnification ×100).

toe, with stretched overlying skin, without local inflammatory signs or neurovascular deficits (Fig. 1).

Plain radiographs demonstrated an expansile osteolytic lesion involving the distal phalanx of the great toe, with cortical thinning and destruction, and no periosteal reaction or matrix calcification (Fig. 2a). Computed tomography scan also confirmed similar findings (Fig. 2b). An magnetic resonance imaging of the foot showed a lobulated lesion involving the distal phalanx that is hypointense to intermediate on T1-weighted images and heterogeneous intermediate-to-high signal on fluid-sensitive sequences, with areas of relatively low signal. There extends up to the articular surface with preserved joint cortex, without neurovascular encasement and also to subungual region and soft tissue involvement , consistent with a locally aggressive bone tumor (Fig. 2c and d). Based on the radiological appearance, a giant cell–rich lesion was suspected. A biopsy was performed, which revealed sheets of mononuclear stromal cells interspersed with numerous osteoclast-like multinucleated giant cells, consistent with GCT of bone (Fig. 3). The patient took three doses of denosumab. Following histopathological confirmation, surgical resection of the distal phalanx was undertaken. The immediate postoperative period was uneventful. Besides, the skin lesions on the dorsum of foot were "Lichen simplex chronicus" and she received intralesional steroids and tarolimus ointments besides antihistaminic in dermatological department. Postoperative follow-up was performed for 1 year, and no further recurrence was observed; the patient remains symptom-free (Fig. 4).

Discussion

GCT of bone is a benign but locally aggressive neoplasm that mostly affects the epiphyseal–metaphyseal regions of long bones in skeletally mature individuals [1,2]. Involvement of the foot is very uncommon, accounting for <1% of cases, and phalangeal involvement is among the rarest presentations [6,7]. Among these, occurrence in the distal phalanx of the great toe is extremely rare, with only isolated case reports available in the literature [3,8].

Several studies have demonstrated that GCT bones (GCTB) arising in the small bones of the hand and foot behave more aggressively than those in long bones, despite identical histological features [4,7]. These tumors tend to present at a younger age, show rapid cortical destruction, early soft-tissue extension, and have a significantly higher rate of local recurrence following intralesional procedures [4,5,7]. The limited bone stock of the phalanges, proximity to joints and the nail bed, and early cortical breach contribute to the difficulty of achieving adequate margins with conservative surgery.

The differential diagnosis of an expansile lytic lesion in the distal phalanx includes aneurysmal bone cyst, giant cell reparative granuloma, brown tumor of hyperparathyroidism, infection, enchondroma, and chondroblastoma [9]. Due to this overlap, histopathological confirmation through biopsy remains essential before definitive management. In the present case, the diagnosis was established on biopsy, followed by distal

Figure 4: (a and b) Post-operative anteroposterior and lateral radiographs after distal phalanx resection; (c) A clinical picture of the bilateral foot after resection of the left toe distal phalanx.

phalanx resection.

Recurrence rates following curettage for GCTB of the small bones have been reported to range from 50% to 80%, significantly higher than those observed in long-bone lesions [4,5,10]. Wide excision or amputation offers superior local control in recurrent or aggressive cases and is often recommended when tumor margins are compromised or soft-tissue extension is present [5,10]. In the present case, amputation was done for definitive disease control [3,8]. Although uncommon, malignant transformation of GCT is well-documented, especially in recurrent or poorly treated lesions [11]. In cases of locally aggressive tumors, resection or amputation of the affected digits offers the best results by preventing any such changes [12].

The great toe plays a critical role in normal gait, functioning as the principal load-bearing and propulsive unit during terminal stance and push-off. Biomechanical studies have demonstrated that the first metatarsophalangeal joint and hallux complex transmit approximately 40–60% of body weight during normal walking, with substantially higher forces – up to 2–3 times body weight – during athletic or high-demand activities [13,14,15]. At toe-off, the hallux stabilizes the medial column of the foot, facilitates efficient forward propulsion, and maintains plantar pressure distribution across the forefoot [16]. Loss of the great toe, therefore, predictably alters gait mechanics, resulting in lateral transfer of load to the lesser metatarsal heads and reduced push-off efficiency. Nevertheless, gait analysis and clinical outcome studies have shown that patients adapt well following hallux amputation through compensatory mechanisms, particularly when pain-free local control is achieved, and adjacent joints are preserved [6,16]. In the setting of GCT of the distal phalanx, the oncological benefit of definitive excision outweighs the anticipated biomechanical compromise, making great toe amputation a rational and functionally acceptable treatment option.

Conclusion

GCT of the distal phalanx of the great toe is a rare and locally aggressive entity. Despite its benign histology, it carries a high risk of recurrence following limited surgical procedures. Early diagnosis, appropriate biopsy, and definitive surgical intervention are essential for achieving appropriate local control. Amputation remains a reliable treatment option in recurrent cases.

Clinical Message

GCT of the distal phalanx of the great toe is rare, tends to be more aggressive with higher recurrence, and therefore, amputation is a definitive treatment with acceptable functional outcomes.

Declaration of patient consent: The authors certify that they have obtained all appropriate patient consent forms. In the form, the patient has given the consent for his/ her images and other clinical information to be reported in the journal. The patient understands that his/ her names and initials will not be published and due efforts will be made to conceal their identity, but anonymity cannot be guaranteed.

Conflict of interest: Nil **Source of support:** None

References

1. Campanacci M, Baldini N, Boriani S, Sudanese A. Giant-cell tumor of bone. J Bone Joint Surg Am 1987;69:106-14.

2. Goldenberg RR, Campbell CJ, Bonfiglio M. Giant-cell tumor of bone. An analysis of two hundred and eighteen cases. J Bone Joint Surg Am 1970;52:619-64.

3. Bachhal V, Rangdal S, Saini U, Sament R. Giant cell tumor of distal phalanx of great toe. A case report. Foot (Edinb) 2011;21:198-200.

4. Szendröi M. Giant cell tumor of bone. J Bone Joint Surg Br 2004;86:5-12.

5. Turcotte RE. Giant cell tumor of bone. Orthop Clin North Am 2006;37:35-51.

6. O'Keefe RJ, O'Donnell RJ, Temple HT, Scully SP, Mankin HJ. Giant cell tumor of bone in the foot and ankle. Foot Ankle Int 1995;16:617-23.

7. Biscaglia R, Bacchini P, Bertoni F. Giant cell tumor of the bones of the hand and foot. Cancer 2000;88:2022-32.

8. Yokouchi M, Arishima Y, Nagano S, Shimada H, Nakamura S, Setoguchi T, et al. Giant cell tumor of the distal phalanx of the fourth toe: A case report. J Foot Ankle Surg 2016;55:306-9.

9. Lang S. Differential diagnosis of giant cell-rich lesions of bone. Pathologe 2008;29 Suppl 2:245-9.

10. Balke M, Schremper L, Gebert C, Ahrens H, Streitbuerger A, Koehler G, et al. Giant cell tumor of bone: Treatment and outcome of 214 cases. J Cancer Res Clin Oncol 2008;134:969-78.

11. Palmerini E, Picci P, Reichardt P, Downey G. Malignancy in giant cell tumor of bone: A review of the literature. Technol Cancer Res Treat 2019;18:1533033819840000.

12. Hashimoto K, Nishimura S, Ito T, Akagi M. Malignant giant cell tumor of toe: A case report and review of literature.

Medicine (Baltimore) 2022;101:e29471.

13. McCormick JJ, Anderson RB. Turf toe: Anatomy, diagnosis, and treatment. Sports Health 2010;2:487-94.

14. Najefi AA, Jeyaseelan L, Welck M. Turf toe: A clinical update. EFORT Open Rev 2018;3:501-6.

15. Frimenko RE, Lievers W, Coughlin MJ, Anderson RB, Crandall JR, Kent RW. Etiology and biomechanics of first metatarsophalangeal joint sprains (turf toe) in athletes. Crit Rev Biomed Eng 2012;40:43-61.

16. Embaby OM, Elalfy MM. First metatarsophalangeal joint: Embryology, anatomy and biomechanics. World J Orthop 2025;16:102506.

Acknowledgement: Dr. Manas Baisakh (Prolife Diagnostics) for providing the HPE slide of the patient.

Conflict of Interest: Nil
Source of Support: Nil

Consent: The authors confirm that informed consent was obtained from the patient for publication of this article

How to Cite this Article

Sarma EA, Jain M, Mishra H, Aabid AMZ, Khan S, Panda J. Giant Cell Tumor of the Distal Phalanx of the Great Toe: Case Report. Journal of Orthopaedic Case Reports 2026 October;16(10): 52-56.