Case Report | Journal of Orthopaedic Case Reports 2026 October:16(10):Page 57-62

Is Cell-Free Collagen Matrix Effective in the Treatment of Large Cartilage Defects of Knee? Early Functional and Quantitative Magnetic Resonance Imaging Cartigram Assessment in Two Patients

Ajay[1], Ruhi Parveen[1], Subhashis Mandal[1], Pallav Mishra[1], Yassir Mehmood[1], Ankit Ruhela[1]

Learning Point of the Article:

Cell-free collagen matrix is effective in early healing of even large (2–4 cm) Grade IV chondral defects with excellent functional outcomes. It promotes hyaline like cartilage regeneration as evidenced by qMRI Cartigram.

Abstract

Introduction: Articular cartilage injuries, particularly large full-thickness defects (International Cartilage Repair Society Grade IV), present a significant challenge due to the tissue's limited regenerative capacity. Cell-free collagen matrix, an acellular Type I collagen matrix, has shown promise in promoting cartilage repair. However, its role in treating large chondral defects of the knee with objective radiological correlation remains underexplored. Through two case reports, we have shown that cell free collagen matrix is also effective in early healing of large cartilage defects of knee. To the best of our knowledge, this is among the first reports to document healing of large chondral defects using cell free collagen matrix assessed by quantitative T2 mapping.

Case Report: We have presented two cases of large, isolated chondral defects of the medial femoral condyle treated with acellular collagen matrix. Both patients, one 17-year-old male and another 33-year-old male with large chondral defects (3.5 × 2.5 cm and 4 × 2 cm) of knee underwent diagnostic arthroscopy and loose body removal followed by cartilage repair using acellular collagen matrix through mini-open arthrotomy. Functional outcomes were evaluated using International Knee Documentation Committee (IKDC) and Lysholm scores. Cartilage healing was assessed at 6 months with quantitative magnetic resonance imaging using T2 mapping (Cartigram). Both patients demonstrated marked early functional improvement, with IKDC scores increasing from 31.03 to 71.26 in first case and 33.33–73.56 in second case, while Lysholm scores increased from 38 and 42 to 85 in both the patients at 6 months. Cartigram revealed T2 relaxation times at the repair sites are comparable to the adjacent normal cartilage, suggesting excellent hyaline-like cartilage regeneration.

Conclusion: Cell free collagen matrix is effective in early healing of isolated large Grade IV cartilage defects of knee, by promoting hyaline like cartilage regeneration with excellent radiological and functional outcomes. Further studies with large population size and longer follow-up are needed to be done to establish its long-term efficacy.

Keywords: Acellular collagen matrix, cartilage defect(s), cell free collagen matrix, chondral damage, chondrofiller, large cartilage defect(s).

Introduction

Articular cartilage is robust and elastic type of connective tissue that plays a crucial role in the physiological mobility of joints by providing improved cushioning and reducing friction on articulated surfaces [1]. Articular cartilage can be damaged due to trauma, sports or normal aging degenerative process. Once

Access this article online

Website: www.jocr.co.in

DOI: https://doi.org/10.13107/jocr.2026.v16.i10.8186

Author's Photo Gallery

Dr. Ajay | Dr. Ruhi Parveen | Dr. Subhashis Mandal | Dr. Pallav Mishra | Dr. Yassir Mehmood | Dr. Ankit Ruhela

[1]Department of Orthopaedics, Sports Injury Centre, VMMC and Safdarjung Hospital, New Delhi, India.

Address of Correspondence:
Dr. Ruhi Parveen,
Department of Orthopaedics, Sports Injury Centre, VMMC and Safdarjung Hospital, New Delhi - 110029, India.
E-mail: ruhip5596@gmail.com

Submitted: 11/07/2026; Review: 04/08/2026; Accepted: September 2026; Published: October 2026

DOI: https://doi.org/10.13107/jocr.2026.v16.i10.8186

© The Author(s). 2026 Open Access. This article is distributed under the terms of the Creative Commons Attribution 4.0 International License (https://creativecommons.org/licenses/by-nc/4.0/), which permits unrestricted use, distribution, and non-commercial reproduction in any medium, provided you give appropriate credit to the original author(s) and the source, provide a link to the Creative Commons license, and indicate if changes were made. The Creative Commons Public Domain Dedication waiver (http://creativecommons.org/publicdomain/zero/1.0/) applies to the data made available in this article, unless otherwise stated.

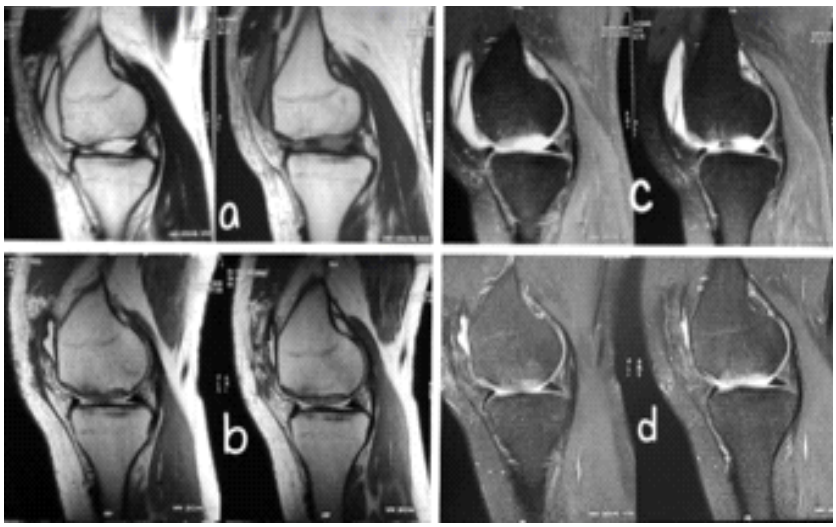

Figure 1: Pre-operative and post-operative conventional magnetic resonance imaging of the cartilage defect of case 1. (a) pre-operative T1 sagittal section, (b) post-operative T1 sagittal section, (c) Pre-operative T2 sagittal section, (d) post-operative T2 sagittal section.

damaged, it cannot heal itself due to its avascular nature and the limited mitotic potential of chondrocytes [2]. At present, there is no universal technique for replacement of cartilage defect suitable for all patients. The method chosen depends on the defect's grade, size, and localization, along with age and activity level of the patients [1]. Various surgical methods have been discussed to address cartilage defects including microfracture, osteochondral autograft transfer system, mosaicplasty, autologous chondrocyte implantation, among others [3]. Another method is to use collagen gel, which has become an attractive solution for chondral defects in recent times. Cell free collagen matrix is an example of absorbable acellular Type 1 collagen implant. When applied to the focal area of cartilage lesion, it forms a protective layer over injured area and provides a matrix for migration of stem cells and chondrocytes, thus it aims to restore articular cartilage [4].

Promising results have been reported using the acellular collagen matrix for the cartilage defects of knee, hip and talus [4,5,6,7,8,9,10]. With respect to knee joints, most of the authors have used it in small to medium chondral defects (up to 2 cm^2) [4,7,8]. However, its use in large cartilage defects (>2 cm^2) is not very well studied. Furthermore, there is paucity of literature showing the precise quality of repaired cartilage, as conventional magnetic resonance imaging (MRI) cannot quantitatively measure the quality of cartilage repair. The quantitative MRI (qMRI) T2 mapping, such as Cartigram, can quantitatively measure alterations in the water and collagen content of hyaline articular cartilage precisely and T2 value gives a quantitative assessment of quality of articular cartilage [11, 12]. Here, we have reported two cases with larger cartilage defect (up to 3.5 cm^2) of the knee treated with acellular collagen matrix that showed excellent early healing depicted in qMRI T2 mapping with equally good early functional outcomes.

Case Report

We have reported two cases of isolated International Cartilage Repair Society Grade IV [13] articular cartilage defects of large size in the knee treated with acellular collagen matrix and showed the quality of repair using qMRI T2 mapping with early functional outcomes using Lysholm and International Knee Documentation Committee (IKDC) score. The surgical technique and post-operative rehabilitation were same for both the patients, which are described as follows.

Surgical procedure

The surgical procedures were done under spinal anesthesia. Both the cases were operated by the same surgeon. With pneumatic tourniquet applied, first diagnostic arthroscopy was done and loose bodies were removed. Under arthroscopy, the

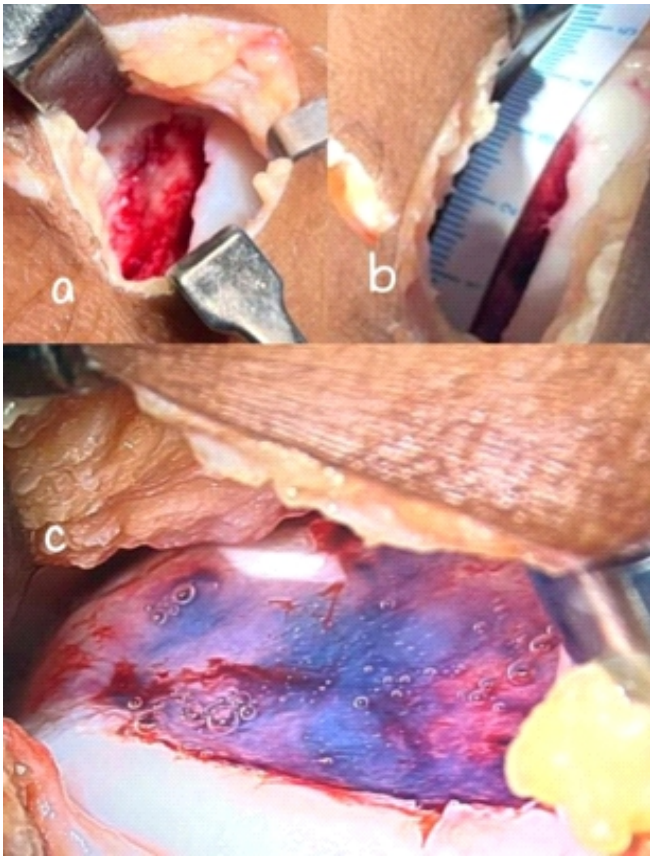

Figure 2: Intraoperative pictures of case 1: (a) cartilage defect after debridement, (b) defect size measurement, (c) repair of defect using cell free collagen matrix.

Figure 3: Pre-operative and post-operative conventional magnetic resonance imaging of case 2. (a) pre-operative T2 sagittal and coronal sections, (b) post-operative T2 sagittal and coronal sections.

defect was visualized and its size was carefully measured using a probe. In both cases, the defect was in medial femoral condyle. Following diagnostic arthroscopy, a mini-open arthrotomy was performed to address the defect. The cartilage defects were carefully debrided using a motorized shaver and curette. The size of the defects was documented. After debridement, it was irrigated and dried to ensure a clean and moisture-free surface. Cell free collagen matrix, previously stored at −20°C, was taken out of refrigeration and allowed to defrost at room temperature over 15–20 min. During this period, it transitioned from a solid white state to a transparent gel form, indicating readiness for application. The acellular collagen matrix was applied into the defect using pre-attached cannula until the defect was filled completely. Following application, the area was left undisturbed for gelification which was determined by the change of color from transparent to white. The limb was maintained in the same position throughout the setting phase. Once the collagen matrix had solidified, standard layered wound closure was performed followed by compression dressing application.

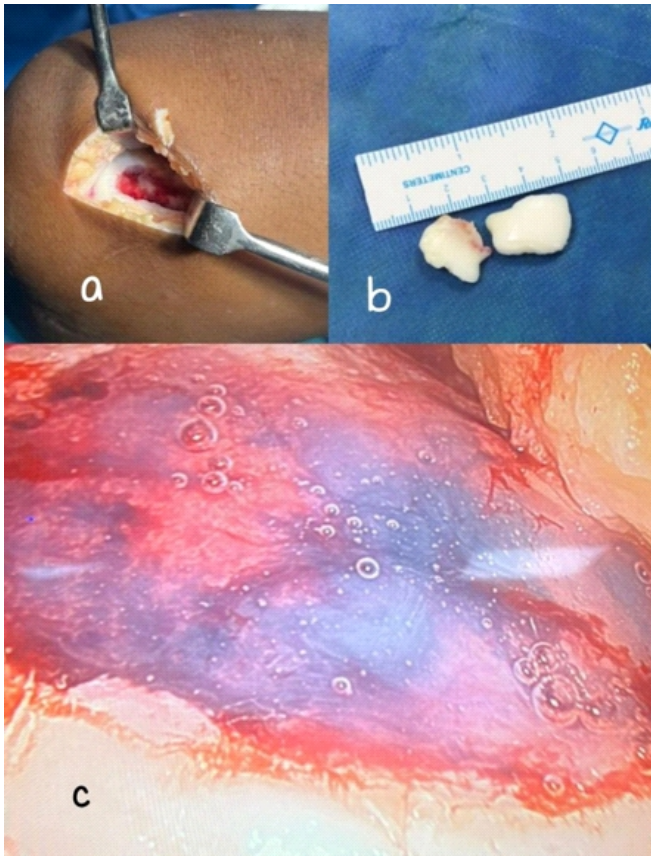

Figure 4: Intraoperative images of case 2: (a) cartilage defect after debridement, (b) removed loose bodies, (c) defect after repair using cell free collagen matrix.

Post-operative rehabilitation protocol

Table 1.

Table 1: postoperative rehabilitation protocol.

Time	Exercises
0–2 weeks	Immobilized in extension, ice, compression
	Ankle pumps
	Non-weight-bearing
	Active straight leg raise without extensor lag
	Patellar mobilization
2–6 weeks	Knee flexion increased by 30° every 2 weeks
	Non-weight-bearing
	Isometric quadriceps, , hamstring strengthening exercise, side lying hip abduction
6–8 weeks	Partial weight-bearing with brace and walker
	Full knee range of motion achieved
8–12 weeks	Full weight-bearing allowed
	Strengthening of quadriceps, hamstring
	Balancing exercises
12–24 weeks	Single leg strength exercises (single leg heel raise, single leg dead lift, single leg squat)
	Gym based strengthening of quadriceps, VMO, hamstrings.
	Strengthening of hip abductors and flexors.
	Things to avoid: Exercises into knee flexion >90°, cutting/pivoting, sports specific activity
After 6 months	Return to normal activities

VMO: Vastus medialis obliquus

Follow-up

Regular follow-ups were carried out at one month interval for 6 months. Clinical outcomes were evaluated based on Lysholm

and IKDC scores at 3rd, 6th and 12th month. At 6 months, a Cartigram (qMRI T2 mapping) was done to check the healing of the cartilage repair.

Case report 1

A 17-year-old male (non-athlete) presented with a two-month history of non-traumatic right knee pain and catching sensation, aggravated by weight-bearing activities. The pre-operative IKDC and Lysholm scores were 31.03 and 38, respectively. MRI of the knee revealed osteochondritis dissecans involving the medial femoral condyle, with a large osteochondral defect measuring approximately 3.2 × 2 cm and the presence of two sizable loose bodies (Fig. 1). He underwent arthroscopic removal of the loose bodies followed by mini-open cartilage repair using cell free collagen matrix as described above (Fig. 2). After debridement, the defect size was 3.5 × 2.5 cm. Post-operative IKDC score increased from 31.03 to 60.4 and 71.26 at 3rd and 6th months, respectively, whereas the Lysholm score increased from 38 to 69 and 85 at 3rd and 6th months, respectively. A follow-up Cartigram was performed at 6 months to evaluate the healing of the repair (Fig. 3). The T2 values at the site of cartilage repair of medial femoral condyle was 48–53, which is similar to the T2 values of adjacent normal cartilage (39–49), suggesting excellent healing.

Case report 2

A 33-year-old man (non-athlete) presented with left knee pain for 3 months following fall from stairs. Pain was particularly on weight-bearing and knee movement. On clinical examination there was terminal loss of flexion due to pain. MRI was suggestive of large cartilage defect at the weight-bearing area of medial femoral condyle with two loose bodies (Fig. 4). The pre-operative IKDC and Lysholm score was 33.33 and 42, respectively. He also underwent diagnostic arthroscopy and loose body removal, followed by mini-open repair of cartilage defect using acellular collagen matrix (Fig. 5). After debridement, the defect size was 4 × 2 cm. Post-operative IKDC scores at 3rd, 6th, and 12th month were 62, 73.56, and 81.60, respectively, Lysholm scores at 3rd, 6th and 12th month were 71, 85 and 95. Follow-up Cartigram at 6 months suggested the T2 values at the site of cartilage repair site were 44–56, which is similar to the T2 values of adjacent normal cartilage (44–54), suggesting excellent healing (Fig. 6).

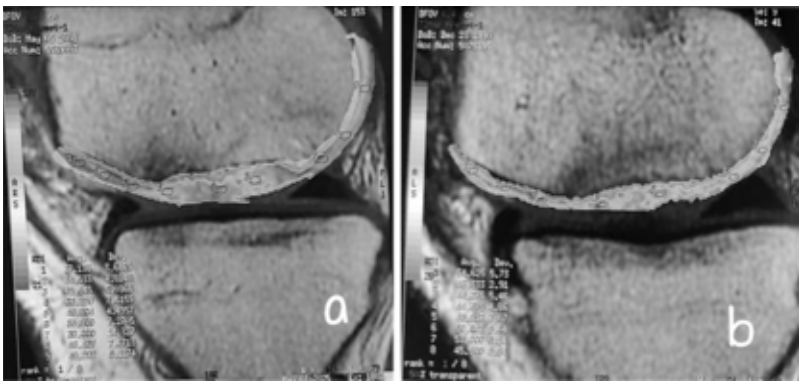

Figure 5: Cartigram at 6 months (T2 values are written within the image). (a) Cartigram of case 1, (b) Cartigram of case 2.

Discussion

Restoration of cartilage defects still remains a major obstacle in orthopedics. Extensive research has been done in the last decade to find suitable biomaterial which could be used. Cell free collagen matrix has become an attractive technique for restoring the cartilage defects. The basic principle of acellular collagen matrix is to fill the cartilage defect with matrix structure, which provides a scaffold for chondrocytes to migrate from the perilesional tissue, enabling attachment, proliferation and extracellular matrix production [7].

Schneider [7], in his study done in 2016 showed successful filling of all the cartilage defects of knee using cell free collagen matrix in thirteen patients with radiological correlation using conventional MRI sequence. The defects were of small and medium size (mean size <2.5 cm).

In another study, published in 2024, Simeonov found encouraging results by employing cell free collagen matrix to restore articular cartilage. He concluded that collagen matrix provides excellent surgical solution to younger patients with chondral defects <2 cm2 based on clinical outcomes. However, no follow-up MRI was done [4].

Similarly, in the study conducted by Syed et al. on cell free collagen matrix and treatment of cartilage defects in the knee, the mean chondral defect size was 11.82–17.82 mm. They have evaluated the outcomes using IKDC score and concluded that it could serve as a good treatment option for Grade IV chondral defects [8].

Schüttler et al. [6] and Efe et al. [5] in their respective studies showed clinical as well as MRI correlation for the repair of knee chondral defects of small size (<11 mm) using cell free collagen Type 1 matrix.

In the current literature, the cartilage defects of knee treated with acellular collagen matrix were of small to medium size (<2.5 cm). In our study, maximum dimension of both the defects was of more than 2.5 cm. In addition, there are not many studies on healing of knee articular cartilage defect and its MRI correlation. In fact, we were able to find only one study on knee cartilage defect repair using acellular

collagen matrix, done by Schneider [7], where MRI studies were done in follow-up to show the repair quality. However, to the best of our knowledge, we were not able to find any English literature where Cartigram was done to assess the healing quality of cell free collagen matrix in cartilage injuries. T2 relaxation mapping with MRI, such as Cartigram, can help visualize and quantitatively evaluate the water content of cartilage. The changes in T2 values correlate with variations in water content and collagen structure and organization, as well as changes in hyaline cartilage composition and its depletion [11]. In addition, T2 mapping enables demonstration of treatment response based on changes in T2 values [14]. Here, we have assessed the healing of repaired cartilage defects using Cartigram at 6 months. In both the cases, the Cartigram showed excellent healing with T2 values of 48–53 in the first case and 44–56 in the second case, respectively, which were similar to T2 values of adjacent normal cartilage. The IKDC score in our study was 71.26 and 73.56 in the first and second cases, respectively, at 6 months. The mean IKDC scores at 6 months in other reference studies were 72.1 (Schneider), 66.25 (Syed et al.). We have applied cell free collagen matrix through mini-open arthrotomy instead of doing arthroscopically as the defect size was larger than usually described in literature.

Conclusion

This case report highlights the potential of cell free collagen matrix as an effective treatment for large Grade IV chondral defects of the knee, showing both excellent early functional recovery and promoting hyaline like cartilage regeneration as evidenced by qMRI Cartigram. To the best of our knowledge, this is among the first reports to document healing of large chondral defects of size >2.5 cm^2 using cell free collagen matrix assessed by quantitative T2 mapping. Further prospective studies with larger cohorts and longer follow-ups are needed to establish its long-term efficacy.

Clinical Message

Cell free collagen matrix can be effectively used to treat large (2–4 cm) chondral defects with excellent early radiological and functional outcomes.

Declaration of patient consent: The authors certify that they have obtained all appropriate patient consent forms. In the form, the patient has given the consent for his/ her images and other clinical information to be reported in the journal. The patient understands that his/ her names and initials will not be published and due efforts will be made to conceal their identity, but anonymity cannot be guaranteed.

Conflict of interest: Nil **Source of support:** None

References

1. Buryanov OA, Chornyi VS, Bazarov MO, Mohilnytskyy AO, Hutsailiuk VI, Kusyak AP, et al. Modern technologies for replacement of cartilage defects. Trauma 2024;25:45-53.

2. Steinert AF, Ghivizzani SC, Rethwilm A, Tuan RS, Evans CH, Nöth U. Major biological obstacles for persistent cell-based regeneration of articular cartilage. Arthritis Res Ther 2007;9:213.

3. Gracitelli GC, Moraes VY, Franciozi CE, Luzo MV, Belloti JC. Surgical interventions (microfracture, drilling, mosaicplasty, and allograft transplantation) for treating isolated cartilage defects of the knee in adults. Cochrane Database Syst Rev 2016;9:CD010675.

4. Simeonov E. Implantation of ChondroFiller Liquid® as a scaffold material for the treatment of chondral lesions of the knee joint. JIMAB 2024;30:5936-41.

5. Efe T, Theisen C, Fuchs-Winkelmann S, Stein T, Getgood A, Rominger MB, et al. Cell-free collagen type I matrix for repair of cartilage defects-clinical and magnetic resonance imaging results. Knee Surg Sports Traumatol Arthrosc 2012;20:1915-22.

6. Schüttler KF, Götschenberg A, Klasan A, Stein T, Pehl A, Roessler PP, et al. Cell-free cartilage repair in large defects of the knee: Increased failure rate 5 years after implantation of a collagen type I scaffold. Arch Orthop Trauma Surg 2019;139:99-106.

7. Schneider U. Controlled, randomized multicenter study to compare compatibility and safety of ChondoFiller liquid (cell free 2-component collagen gel) with microfracturing of patients with focal cartilage defects of the knee joint. Video J Orthop Surg 2016;1:1-8.

8. Syed RF, Thati S. Chondrofiller and treatment of cartilage defects in the knee. Acta Sci Orthop 2024;7:3-7.

9. Mazek J, Gnatowski M, Salas AP, O'Donnell JM, Domżalski M, Radzimowski J. Arthroscopic utilization of ChondroFiller gel for the treatment of hip articular cartilage defects: A cohort study with 12- to 60-month follow-up. J Hip Preserv Surg 2021;8:22-7.

10. Khan PS, Meleppuram JJ, Ahmed HN, Nizaj N, Nair AV, Ananthakrishnan R, et al. Arthroscopic collagenous matrix therapy for osteochondral lesions of the talus. Arthrosc Tech

2025;14:103575.

11. Lee SH, Lee YH, Song HT, Suh JS. Quantitative T2 mapping of knee cartilage: Comparison between the synthetic MR imaging and the CPMG sequence. Magn Reson Med Sci 2018;17:344-9.

12. Safna MA, Sunil M, Kumar K. T2 mapping [Cartigram] in the evaluation of the articular cartilage in traumatic knee injury. MedPulse Int J Radiol 2019;9:59-62.

13. Van Den Borne MP, Raijmakers NJ, Vanlauwe J, Victor J, De Jong SN, Bellemans J, et al. International cartilage repair society (ICRS) and Oswestry macroscopic cartilage evaluation scores validated for use in autologous chondrocyte implantation (ACI) and microfracture. Osteoarthritis Cartilage 2007;15:1397-402.

14. Mnezes NM, Gray ML, Hartke JR, Burstein D. T2 and T1rho MRI in articular cartilage systems. Magn Reson Med 2022;51:503-9.

Conflict of Interest: Nil
Source of Support: Nil

Consent: The authors confirm that informed consent was obtained from the patient for publication of this article

How to Cite this Article

Ajay, Parveen R, Mandal S, Mishra P, Mehmood Y, Ruhela A. Is Cell-Free Collagen Matrix Effective in the Treatment of Large Cartilage Defects of Knee? Early Functional and Quantitative Magnetic Resonance Imaging Cartigram Assessment in Two Patients. Journal of Orthopaedic Case Reports 2026 October;16(10): 57-62.