Case Report | Journal of Orthopaedic Case Reports 2026 October:16(10):Page 113-119

Arthroscopic Piecemeal Excision of a Large Intra-articular Infrapatellar Osteochondroma of the Knee: A Case Report

Nazmuddin Jetaji[1], Sara Sami[2], Rajan Babu[1], Sreekanth Reddy Rajoli[1]

Learning Point of the Article:

Large intra-articular infrapatellar osteochondromas, though exceptionally rare, can be safely and effectively managed with an arthroscopic piecemeal excision technique, facilitating early rehabilitation and avoiding the morbidity of open surgery.

Abstract

Introduction: Intra-articular osteochondromas are uncommon mass-occupying lesions of the knee, with a reported prevalence of approximately 1 in 1 million. Large lesions in the infrapatellar region are exceptionally rare, and only a handful of cases have been described in the literature. Based on a comprehensive review of the English literature, to the best of our knowledge, we report what appears to be one of the largest intra-articular infrapatellar osteochondromas successfully excised using a minimally invasive arthroscopic technique.

Case Report: A 46-year-old Filipino female presented with a 6-month history of progressive pain, swelling, and restriction of motion in the left knee. Imaging revealed a well-defined ossified mass in the infrapatellar region measuring approximately 28 × 20 mm – comparable in size to the native patella. The lesion was excised arthroscopically in a piecemeal fashion followed by retrieval through a mini-open medial parapatellar incision. Histopathological examination confirmed the diagnosis of an osteochondroma with a hyaline cartilaginous cap.

Conclusion: This case demonstrates that large intra-articular osteochondromas of the infrapatellar region, though rare, can be safely and effectively managed with arthroscopic piecemeal excision, facilitating early rehabilitation and avoiding the morbidity of open surgery. The presence or absence of synovial tissue within the lesion helps determine the etiology and malignant potential, although transformation remains rare.

Keywords: Osteochondroma, intra-articular, infrapatellar fat pad, arthroscopy, excision.

Introduction

Intra-articular osteochondromas are rare benign lesions of the knee, distinct from the more common extra-articular osteochondromas that typically arise from the metaphysis and grow away from the joint. The reported prevalence of intra-articular osteochondromas is approximately 1 in 1 million [1]. When located within the infrapatellar fat pad (Hoffa's fat pad), these lesions present a unique diagnostic and surgical challenge due to their proximity to the patellar tendon and their potential to cause significant mechanical symptoms.

We report a case of a large intra-articular infrapatellar osteochondroma in a middle-aged female, which caused considerable discomfort during ambulation and a significant block to the range of motion (ROM) of the knee. The lesion was removed using a minimally invasive arthroscopic and mini-open technique, which is described in detail. We also review the literature to identify similar cases, their management, and the possible etiologies of such lesions. The differential diagnoses

Access this article online

Website: www.jocr.co.in

DOI: https://doi.org/10.13107/jocr.2026.v16.i10.8206

Author's Photo Gallery

Dr. Nazmuddin Jetaji

Miss. Sara Sami

Dr. Rajan Babu

Dr. Sreekanth Reddy Rajoli

[1]Department of Orthopedics Surgery, LLH Hospital, Abu Dhabi, UAE,
[2]Department of Research and Health Innovation, Burjeel Medical City, Abu Dhabi, UAE.

Address of Correspondence:
Dr. Nazmuddin Jetaji,
Department of Orthopedics Surgery, LLH Hospital, Abu Dhabi, UAE.
E-mail: njetaji@gmail.com

Submitted: 23/07/2026; Review: 05/08/2026; Accepted: September 2026; Published: October 2026

DOI: https://doi.org/10.13107/jocr.2026.v16.i10.8206

© The Author(s). 2026 Open Access. This article is distributed under the terms of the Creative Commons Attribution 4.0 International License (https://creativecommons.org/licenses/by-nc/4.0/), which permits unrestricted use, distribution, and non-commercial reproduction in any medium, provided you give appropriate credit to the original author(s) and the source, provide a link to the Creative Commons license, and indicate if changes were made. The Creative Commons Public Domain Dedication waiver (http://creativecommons.org/publicdomain/zero/1.0/) applies to the data made available in this article, unless otherwise stated.

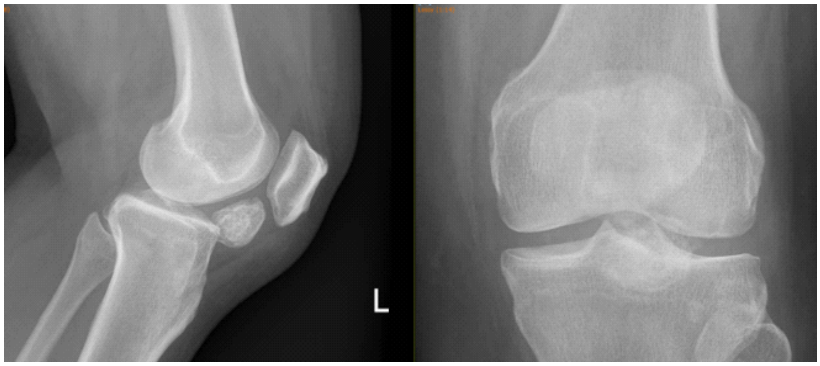

Figure 1: Left knee radiograph showing calcified mass in the infrapatellar region.

include Trevor's disease (dysplasia epiphysealis hemimelica), synovial osteochondromatosis, extraskeletal para-articular osteochondroma, hereditary multiple exostoses (HME), and chondrosarcoma (Table 1).

Case Report

A 46-year-old Filipino female presented with a 6-month history of progressive pain and swelling in the left knee. The pain was of gradual onset, dull in character, and of moderate intensity, occasionally radiating to the left lower limb. Symptoms were aggravated by activity, knee movement, and weight-bearing, and were partially relieved by rest and analgesic medication. The patient also reported swelling, stiffness, intermittent locking, and occasional giving-way episodes, resulting in significant functional limitation including difficulty walking, climbing stairs, and performing daily activities. There was no history of trauma or previous knee surgery. No relevant past medical history or comorbidities were noted.

On physical examination, there was visible fullness over the anterior aspect of the left knee, particularly in the infrapatellar region. The swelling was firm to hard in consistency, fixed to the underlying structures, and non-fluctuant. The overlying skin was normal with no signs of inflammation. Knee ROM was restricted, with an extension lag of 20° and flexion limited to 110°. A painful click was elicited during terminal extension. Joint line tenderness was absent, and ligamentous stability tests were unremarkable. Meniscal tests were negative.

Plain radiographs (Fig. 1) of the left knee demonstrated a well-defined ossified mass in the infrapatellar region within the joint space, appearing similar in size to the patella.

A preoperative non-contrast magnetic resonance imaging (MRI) (Figs. 2 and 3) of the left knee identified a 2.6 × 2.7 × 2.2 cm corticated, T1- and T2-hypointense mass in the infrapatellar fat pad, featuring a thin T2-hyperintense and T1-isointense rim consistent with a cartilaginous surface. Associated smaller foci, edematous changes, and synovial thickening suggested juxta-articular chondromas, with secondary findings including minimal joint effusion and Grade 1 anterior cruciate ligament

Figure 2: Sagittal image of magnetic resonance imaging of the knee showing the well-calcified mass surrounded by cartilage cap.

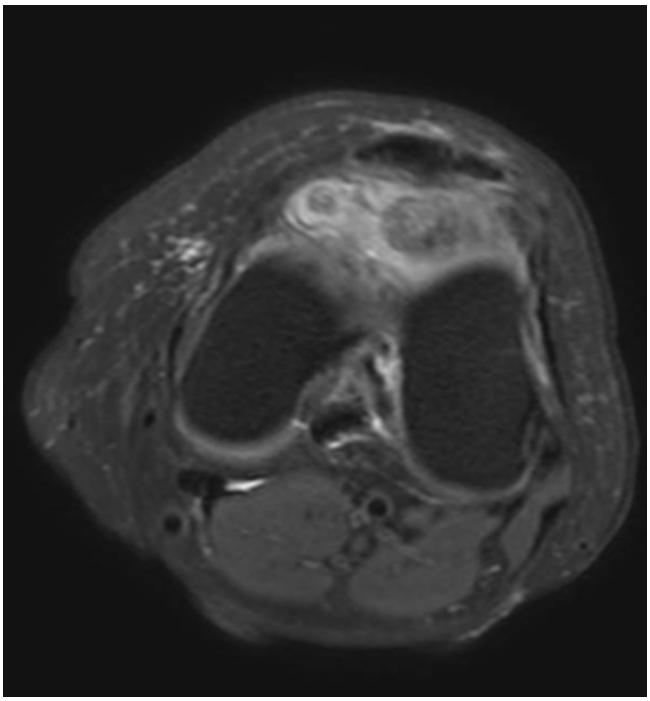

Figure 3: Axial section of the magnetic resonance imaging left knee demonstrating the same lesion.

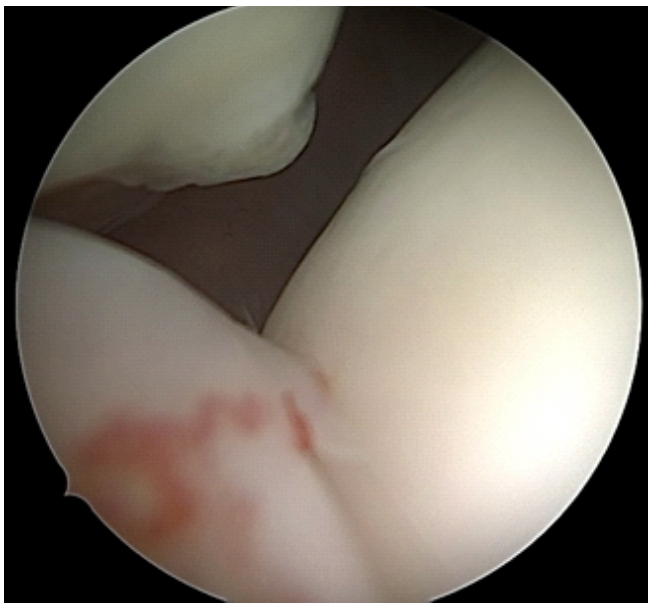

Figure 4: Arthroscopic view of the mass (left) with femoral condyle on the right and patella on the top.

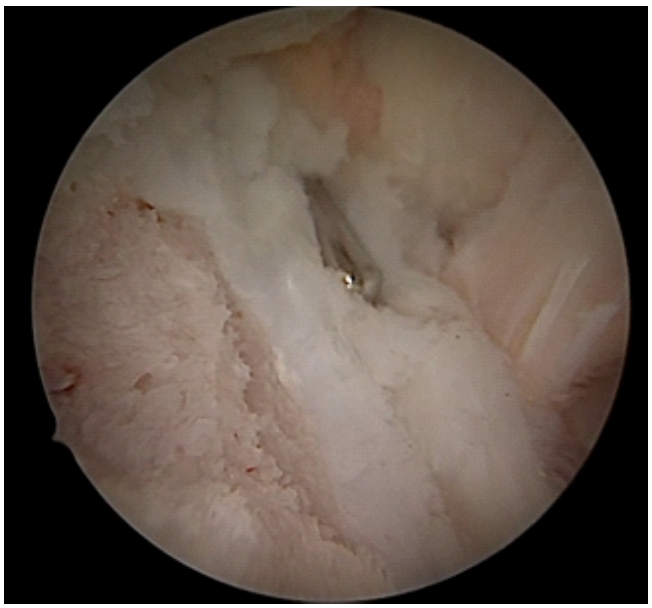

Figure 5: Arthroscopic view after piecemeal partial excision. Ossified core on the left with cartilage cap surrounding it.

signal alteration. Multiple smaller osteocartilaginous loose bodies were also identified within the joint cavity. No meniscal tear was observed. The presence of multiple loose bodies argues against a diagnosis of extraskeletal para-articular osteochondroma.

Based on imaging findings, the provisional diagnosis was osteocartilaginous loose bodies with synovial hypertrophy, suggestive of a juxta-articular chondroma. The differential diagnoses considered at this stage included extraskeletal para-articular osteochondroma, synovial osteochondromatosis, Trevor's disease, and chondrosarcoma. The absence of multiple lesions in the synovium, the patient's age, and the absence of skeletal dysplasia made synovial osteochondromatosis and Trevor's disease less likely. The well-defined corticated margins and absence of aggressive features on MRI argued against chondrosarcoma. Intraoperative findings and histopathological examination subsequently confirmed the diagnosis of a large intra-articular infrapatellar osteochondroma.

Surgical technique

The patient underwent arthroscopic excision of the infrapatellar intracapsular osteochondroma under spinal anesthesia. She was positioned supine on the operating table with a pneumatic tourniquet applied to the proximal thigh. The tourniquet was inflated to 250 mmHg. The operative limb was prepared and draped in the usual sterile manner.

Due to the mass effect produced by the infrapatellar lesion, arthroscopic portals were established 5–10 mm more lateral and medial, respectively, relative to the standard anterolateral and anteromedial portals, based on palpation of the soft spot. This modification was necessary to improve visualization and instrument maneuverability within the anterior compartment. A diagnostic arthroscopy was initially performed to evaluate the intra-articular structures.

An intracapsular osteochondroma arising from the region deep to the infrapatellar fat pad was identified. The lesion was surrounded by synovial tissue and partially obscured by the hypertrophic fat pad. Careful synovial debridement was performed using an arthroscopic shaver and radiofrequency probe to expose the margins of the tumor (Fig. 4). Throughout

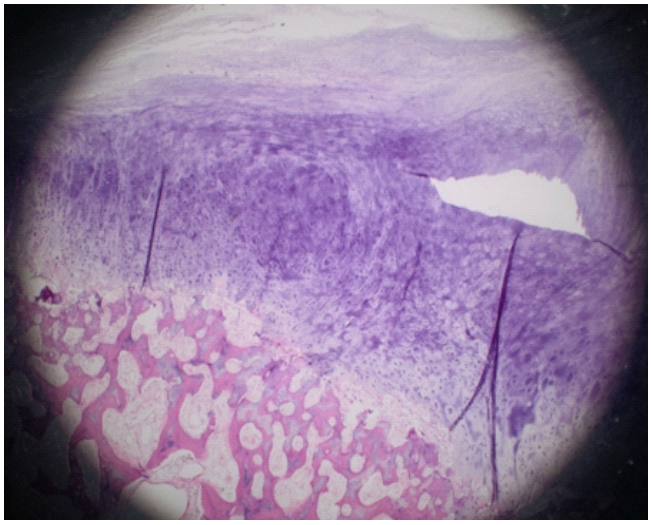

Figure 6: Osteochondroma with hyaline cartilaginous cap and underlying lamellar bone trabeculae with interface of enchondral ossification hematoxylin and eosin ×1.25

infrapatellar fat pad to be excised arthroscopically in the published literature.

the procedure, clear identification and protection of the patellar tendon were maintained, as meticulous delineation of this structure was critical to avoid inadvertent injury during resection.

Once the lesion was adequately exposed and demarcated, the osteochondroma was carefully freed from the surrounding synovium. Arthroscopic shavers and burrs were used to progressively thin the lesion in a controlled piecemeal fashion, reducing its bulk and facilitating safe removal (Fig. 5). The ossified core was particularly dense and required an arthroscopic burr for debulking. After sufficient reduction in size, the residual tumor fragments were retrieved through a small medial parapatellar mini-incision, allowing complete excision of the mass.

The joint was subsequently inspected arthroscopically to confirm complete removal of the lesion and to ensure that the patellar tendon and surrounding structures remained intact. The joint was thoroughly irrigated to remove debris, hemostasis was achieved, and the arthroscopic portals were closed in standard fashion. Total tourniquet time was 120 min. There were no intraoperative complications.

Surgical tips and pearls

1. Delineate and define the patellar tendon with electrocautery at low power while excising the anterior part of the mass

2. Place portals at the palpable soft spots slightly medial and lateral compared to the standard portals, to accommodate the mass-occupying lesion obstructing standard portal placement

3. Perform a complete arthroscopic knee examination to rule out loose bodies hidden in the gutters and posterior compartment.

Postoperatively, the patient was allowed full weight-bearing and early mobilization. At 6–8 weeks, the extension lag had improved from 20° to 10°, and knee flexion had improved from 110° to approximately 150°. Visual analogue scale score on flexion and attempted terminal extension was 7/10 preoperatively, reducing to 1/10 on flexion and 2/10 on extension at 5-month follow-up.

Pathology

Histopathological examination of the excised specimen revealed sections from the left knee intracapsular mass lesion comprising a hyaline cartilaginous cap of maximum thickness 5 mm, covered by fibro-collagenous tissue with myxoid change. The underlying bone trabeculae were prominent and variably widened, with intervening fatty marrow displaying areas of fat necrosis and calcification. Some tissue fragments appeared infarcted. No features of malignancy were identified (Fig. 6). These findings were consistent with a diagnosis of osteochondroma.

Discussion

Osteochondromas are the most common benign bone tumors, typically arising from the metaphysis of long bones and growing away from the adjacent joint [2]. Intra-articular osteochondromas are considerably rarer, with a reported prevalence of approximately 1 in 1 million [1]. The infrapatellar fat pad (Hoffa's fat pad) is an exceptionally uncommon location for such lesions, and cases of this size have rarely been described in the literature.

The present case is notable for the size of the lesion (28 × 20 mm), which approximated the dimensions of the native patella, and for the successful application of a minimally invasive arthroscopic piecemeal excision technique. A comprehensive search of the PubMed, MEDLINE, and Google Scholar databases (1990–2024) using the keywords "intra-articular," "osteochondroma," "infrapatellar," and "arthroscopy," restricted to English-language, full-text publications, revealed a paucity of similar cases. As demonstrated in Table 2, the largest previously reported intra-articular osteochondroma managed arthroscopically measured 2 × 2 cm (Kulkarni et al., 2024 [3]), making the present case, to the best of our knowledge, one of the largest such lesions in the infrapatellar fat pad to be excised arthroscopically in the published literature.

The present case represents, to the best of our knowledge, one of the largest intra-articular infrapatellar osteochondromas managed arthroscopically reported in the literature to date.

Table 1: Differential diagnosis of intra-articular and para-articular ossified masses of the knee

Differential diagnosis	Key clinical features	Distinguishing characteristics
Intra-articular osteochondroma	Solitary, ossified mass within joint space; mechanical symptoms	Arises within joint capsule; covered by synovial tissue; benign cartilage cap
Trevor's disease (Dysplasia epiphysealis hemimelica)	Developmental disorder; usually presents in childhood/young adults; male predominance	Asymmetrical cartilage overgrowth of the epiphysis; often involves multiple joints
Extraskeletal para-articular osteochondroma	Mass adjacent to joint; mechanical symptoms	Develops outside joint capsule; lacks synovial covering; no bony continuity with skeleton
Synovial osteochondromatosis	Multiple loose bodies; joint swelling and stiffness	Multiple cartilaginous nodules within synovium; metaplastic origin
Chondrosarcoma	Painful, enlarging mass; older age group	Aggressive features on imaging (e.g., cortical destruction); cellular atypia on histopathology

Table 2: Published cases of intra-articular and para-articular osteochondromas of the knee

Author (Year) [References]	Age/Sex	Location	Lesion size	Treatment	Outcome and follow-up
Kesgin *et al*. (2013) [16]	27/M 24/F	Adjacent to femoral trochlea	Not reported	Arthroscopic resection	Complete relief; return to full activity within 2 weeks; no recurrence at 3 years and 1 year, respectively
Morey *et al*. (2014) [14]	16/M	Intercondylar notch of femur	Not reported	Arthroscopic excision (*en bloc*)	Painless; full ROM (0–140°) at 1-year follow-up
Mulcahy and Hoch (2015) [7]	25/F	Hoffa's fat pad (extraskeletal para-articular)	3×5 cm	Open excision	Not reported in abstract
Maheshwari *et al*. (2006) [9]	35/M	Infrapatellar fat pad (extraskeletal para-articular)	3.5×2.5 cm	Open excision	Full ROM at 18 months
Nishimura *et al.* (2020) [8]	35/M 38/M 55/M	Infrapatellar fat pad (para-articular)	Not reported	Open simple marginal resection	Pain resolved; full ROM restored; no recurrence at mean 51 months
Chouliaras *et al*. (2021) [15]	32/F	Superolateral aspect of distal femur (intra-articular)	Not reported	Arthroscopic resection (osteotome+burr)	Complete relief; return to full activity at 1 month; no recurrence at 7-year follow-up
Kulkarni *et al*. (2024) [3]	55/F	Intercondylar notch (intra-articular loose body)	2×2 cm	Arthroscopic removal	Complete relief; resumed routine activities within 1 month
Present case	46/F	Infrapatellar fat pad (intra-articular)	28×20 mm (comparable to native patella)	Arthroscopic piecemeal excision+mini-open retrieval	Significant improvement in ROM and pain (VAS 7/10→1–2/10) at 5-month follow-up

Numbers in brackets correspond to the reference list. ROM: Range of motion, VAS: Visual analogue scale, M: Male, F: Female

Several differential diagnoses were considered in this case.

Trevor's disease

Trevor's disease (dysplasia epiphysealis hemimelica) is a developmental disorder of the epiphysis that may present as an intra-articular osteochondroma [4]. It is twice as common in males [5] and most cases present in childhood. Trevor's disease should be considered as a differential diagnosis when a young adult or child presents with an intra-articular mass [6]. Given the patient's age of 46 years and the absence of skeletal dysplasia, Trevor's disease was considered unlikely in the present case.

Extraskeletal para-articular osteochondroma

A close differential diagnosis of intra-articular osteochondroma is extraskeletal para-articular osteochondroma, due to the absence of bony continuity with the underlying skeleton [7,8,9]. The presence or absence of synovial tissue surrounding the lesion is a key differentiating feature. True intra-articular osteochondromas, like the present case, arise within the joint capsule and are covered by synovium, whereas para-articular lesions develop outside the joint capsule. Open excision has been described as the treatment of choice for para-articular lesions [7,8]; however, the present case demonstrates that arthroscopic excision is feasible and may offer advantages in terms of reduced morbidity.

Synovial osteochondromatosis

Synovial osteochondromatosis may present as a solitary giant lesion in the intercondylar notch [10]. Although generally benign, malignant transformation has been reported in approximately 5% of cases [11]. The absence of multiple synovial nodules and the histopathological findings in the present case effectively excluded this diagnosis.

HME

HME is an autosomal dominant disorder that primarily arises from the metaphysis of long bones but may also affect the epiphysis [12,13]. The absence of multiple exostoses in the present case ruled out this diagnosis.

Chondrosarcoma

The risk of malignant transformation in solitary osteochondromas is estimated to be <1%. The absence of aggressive features on MRI and the benign histopathological findings confirmed the diagnosis of osteochondroma in the present case.

The surgical management of intra-articular osteochondromas

traditionally involved open excision, particularly for large lesions in the infrapatellar region [7,8]. However, arthroscopic excision has become increasingly favored due to its advantages of lower morbidity, faster recovery, and improved cosmetic outcomes [3,14,15,16]. Open excision, while providing excellent exposure, requires a larger arthrotomy, which can lead to increased post-operative pain, a higher risk of arthrofibrosis, prolonged rehabilitation, and a less cosmetically appealing scar. Conversely, the arthroscopic approach minimizes soft-tissue disruption, preserves the extensor mechanism, and allows for a thorough evaluation of the entire joint to identify and remove any concomitant loose bodies or associated intra-articular pathology. While arthroscopic removal of smaller loose bodies is well-established, the piecemeal excision of a mass measuring 28 × 20 mm from the infrapatellar fat pad represents a significant technical challenge. In this case, the piecemeal approach using arthroscopic shavers and burrs allowed for controlled debulking of the tumor, avoiding the need for a large arthrotomy. The mini-open parapatellar incision was solely for the retrieval of the reduced fragments, maintaining the minimally invasive nature of the procedure. The successful outcome, with significant improvement in ROM and pain scores at 5 months, highlights the efficacy of this approach.

The histopathological findings in this case are of paramount importance. The identification of a benign hyaline cartilaginous cap without features of cellular atypia or malignant transformation definitively confirms the diagnosis of a benign osteochondroma and rules out more sinister pathologies such as chondrosarcoma. Although the risk of malignant transformation in solitary osteochondromas is exceedingly low (<1%), and recurrence following complete excision is rare, we recommend a long-term clinical and radiological follow-up for these patients. Routine surveillance, ideally extending beyond 2–5 years, is advisable to monitor for any signs of recurrence or secondary degenerative joint changes, particularly in cases involving large, mass-occupying lesions. A limitation of this report is the relatively short follow-up period of 5 months; longer-term surveillance will be necessary to fully assess the durability of the outcome and to detect any late recurrence or degenerative joint changes.

Conclusion

Large intra-articular osteochondromas arising from the infrapatellar fat pad are exceptionally rare lesions that may cause significant mechanical symptoms and functional impairment. This case demonstrates that even a lesion approximating the size of the native patella can be safely and effectively managed using minimally invasive arthroscopic piecemeal excision, thereby avoiding the morbidity associated with open surgery. Histopathological examination remains essential to confirm the diagnosis and exclude malignancy, while early mobilization following arthroscopic excision facilitates rapid functional recovery. Although the exact etiology in this case remains uncertain, the absence of synovial tissue favors a diagnosis of extraskeletal para-articular osteochondroma. However, the presence of multiple smaller, morphologically similar loose bodies raises the possibility of synovial chondromatosis.

Clinical Message

Orthopedic surgeons should consider intra-articular osteochondroma in the differential diagnosis of a solitary, ossified mass in the infrapatellar region presenting with mechanical knee symptoms. Arthroscopic piecemeal excision, combined with a mini-open retrieval, is a safe, effective, and minimally invasive treatment option for large lesions, offering significant advantages over traditional open excision. The presence or absence of synovial tissue in the histopathology assists in determining the etiology.

Declaration of patient consent: The authors certify that they have obtained all appropriate patient consent forms. In the form, the patient has given the consent for his/ her images and other clinical information to be reported in the journal. The patient understands that his/ her names and initials will not be published and due efforts will be made to conceal their identity, but anonymity cannot be guaranteed.

Conflict of interest: Nil **Source of support:** None

References

1. Araujo CR Jr., Montandon S, Montandon C, Teixeira KI, Moraes FB, Moreira MA. Best cases from the AFIP: Dysplasia epiphysealis hemimelica of the patella. Radiographics 2006;26:581-6.

2. Murphey MD, Choi JJ, Kransdorf MJ, Flemming DJ, Gannon FH. Imaging of osteochondroma: Variants and complications with radiologic-pathologic correlation. Radiographics 2000;20:1407-34.

3. Kulkarni S, Patil VS, Naik S, Bhansali Y. Arthroscopic excision of a solitary intra-articular osteochondroma manifesting as a loose body: A presentation of an extremely rare medical condition. Cureus 2024;16:e66083.

4. Gökkuş K, Atmaca H, Sagtas E, Saylik M, Aydin AT. Trevor's disease: Up-to-date review of the literature with case series. J

Pediatr Orthop B 2017;26:532-45.

5. Rosero VM, Kiss S, Terebessy T, Köllö K, Szöke G. Dysplasia epiphysealis hemimelica (Trevor's disease): 7 of our own cases and a review of the literature. Acta Orthop 2007;78:856-61.

6. Maheshwari AV, Pitcher JD. Intraarticular osteochondroma of the knee. Indian J Orthop 2015;49:260-1.

7. Mulcahy H, Hoch B. An extraskeletal para-articular osteochondroma of Hoffa's fat pad. Radiol Case Rep 2015;5:420.

8. Nishimura T, Saku I, Kanda S, Fukushima T, Akiyama T. Para-articular osteochondroma of the infrapatellar fat pad: A report of three cases. Int J Surg Case Rep 2020;69:105-8.

9. Maheshwari AV, Jain AK, Dhammi IK. Extraskeletal paraarticular osteochondroma of the knee--a case report and tumor overview. Knee 2006;13:411-4.

10. Fornaciari P, Schai PA, Niehaus R, Exner UG. Intra-articular giant synovial osteochondroma: Case reports of the ankle and knee joint. Case Rep Orthop 2015;2015:320139.

11. Davis RI, Hamilton A, Biggart JD. Primary synovial chondromatosis: A clinicopathologic review and assessment of malignant potential. Hum Pathol 1998;29:683-8.

12. Stieber JR, Dormans JP. Manifestations of hereditary multiple exostoses. J Am Acad Orthop Surg 2005;13:110-20.

13. Choudhry A, Gimm G, Kang HW, Shin CH, Yoo WJ, Choi IH, et al. Intra-articular acetabular osteochondroma in patients with multiple hereditary exostoses. J Pediatr Orthop B 2022;31:e90-4.

14. Morey VM, Jalan D, Mittal R, Gamangatti S. Intraarticular osteochondroma of the knee. Indian J Orthop 2014;48:332-4.

15. Chouliaras V, Sotiriadis I, Flevas DA. Arthroscopic excision of an intra-articular osteochondroma of the knee. Cureus 2021;13:e17154.

16. Kesgin E, Çelik C, Karaoğlu S. Arthroscopic resection of osteochondroma of the knee: Two case reports. Eklem Hastalik Cerrahisi 2013;24:112-6.

Conflict of Interest: Nil
Source of Support: Nil

Consent: The authors confirm that informed consent was obtained from the patient for publication of this article

How to Cite this Article

Jetaji N, Sami S, Babu R, Rajoli SR. Arthroscopic Piecemeal Excision of a Large Intra-articular Infrapatellar Osteochondroma of the Knee: Journal of Orthopaedic Case Reports 2026 October;16(10): 113-119.