Case Report | Journal of Orthopaedic Case Reports 2026 October:16(10):Page 270-275

An Unusual Presentation of Right fifth Flexor Digitorum Profundus Tendon Zone 3 Rupture Following Jersey Finger Mechanism Injury

Alex Wu[1], Ibin Varughese[1], Michelle Caudwell[1]

Learning Point of the Article:

A "Jersey finger" injury with intact distal insertion should warrant a concealed zone 3 FDP rupture; early imaging is crucial to yield a precise operative approach.

Abstract

Introduction: Zone 3 mid-substance flexor tendon ruptures not only are exceptionally rare but also can clinically masquerade as zone 1 "Jersey finger" during forceful distal interphalangeal joint extension trauma, which can lead to challenges in both conducting diagnosis and surgical intervention planning.

Case Report: A 58-year-old Caucasian gentleman presented with right little finger pain and deformity. He was referred to the orthopedic department as a "Jersey finger.. The mechanism was innocuous and incongruent with the pathology. It involved pulling and pushing a standard household doorknob. He described a "snap and pop" sensation and pain over his mid-palm A1 pulley level. Clinically, his finger demonstrated flexor digitorum profundus (FDP) function loss and flexor lag deformity. He was also found to have an unusual presentation of diffuse tenderness along the A1 pulley toward zone 3 metacarpal levels. Magnetic resonance imaging (MRI) was performed to fully elucidate the pathology. A complete mid-substance full-thickness tendon rupture was identified in zone 3. It was at the level of the metacarpal base. Primary tendon repair was performed with two minimally invasive surgical incisions (fifth metacarpal Brunner incision and carpal tunnel approach) while using a Lim-Tsai six-strand cruciate core tendon repair technique with circumferential 5' proline reinforcement. After his early active range of motion (ROM) flexor protocol hand therapy, the patient fully regained active ROM and strong grip functional recovery during his 6th-week post-operative review.

Conclusion: In this case report, we demonstrated that zone 3 mid-substance full-thickness FDP tendon ruptures can mimic Jersey finger injury as an unusual clinical presentation. Therefore, thorough clinical assessment and radiographic investigations (ultrasound or MRI) are crucial to identify precise ruptured tendon stump locations and guide primary tendon repair with minimal invasive surgical approach. As a result, patients can benefit from having minimal surgical scar tissue while reducing the risk of infection and regaining early functional recovery.

Keywords: Tendon injury, flexor digitorum profundus, zone III flexor tendon rupture, mid-substance tendon rupture, tendon transfer, primary tendon repair.

Introduction

Flexor digitorum profundus (FDP) tendon rupture is one of the most common and complex injuries encountered by hand surgeons [1,2,3]. The mechanism of injury includes traumatic volar lacerations or forceful finger distal interphalangeal (DIP) extension resulting in "Jersey Finger," which is known as an insertional tear injury of FDP from the distal phalanx base at Flexor Zone 1 [1,2]. According to established literature, isolated

Access this article online

Website: www.jocr.co.in

DOI: https://doi.org/10.13107/jocr.2026.v16.i10.8262

Author's Photo Gallery

Dr. Alex Wu

Dr. Ibin Varughese

Dr. Michelle Caudwell

[1]Department of Orthopaedic, Redcliffe Hospital, Redcliffe, Australia.

Address of Correspondence:
Dr. Alex Wu,
Department of Orthopaedic, Redcliffe Hospital, Redcliffe, Australia.
E-mail: alex.wu@health.qld.gov.au

Submitted: 12/07/2026; Review: 07/08/2026; Accepted: September 2026; Published: October 2026

DOI: https://doi.org/10.13107/jocr.2026.v16.i10.8262

© The Author(s). 2026 Open Access. This article is distributed under the terms of the Creative Commons Attribution 4.0 International License (https://creativecommons.org/licenses/by-nc/4.0/), which permits unrestricted use, distribution, and non-commercial reproduction in any medium, provided you give appropriate credit to the original author(s) and the source, provide a link to the Creative Commons license, and indicate if changes were made. The Creative Commons Public Domain Dedication waiver (http://creativecommons.org/publicdomain/zero/1.0/) applies to the data made available in this article, unless otherwise stated.

Figure 1: Right hand fifth little finger X-ray film – anteroposterior, oblique, lateral views; no fracture/lesion.

when tendon fraying occurs against bone spike irregularities such as uncontrolled inflammatory arthritis, advanced osteoarthritis, carpal fractures, or even tumor [4,5,6,7,8]. Fluoroquinolones antibiotic regimen is also another high-risk factor with unclear mechanisms but leading to tendinopathy and tendon rupture [4,5,6,7,8,9].

Based on the current database, there is still limited literature review of zone 3 flexor tendon rupture injuries. In this article, we illustrate that a zone 3 flexor FDP rupture of the little finger can be complex and clinically masquerade as a Jersey finger injury, which often requires pre-operative ultrasonography and magnetic resonance imaging (MRI) investigations to precisely guide incision approach, minimize post-operative surgical scar tissue, reduce infection risks, and allow early functional recovery.

Zone 3 FDP closed injuries are rare and can clinically mimic Jersey finger presentation [3].

Unlike Zone 1 avulsion injury occurring in healthy tendons, Zone 3 FDP rupture is secondary to mid-substance tears associated with some underlying pathologic conditions [3,4,5]. The Intrinsic risk factors include following an intra-tendinous steroid injection or diminished neurovascular/nutrition supply resulting in tendon weakness [3,4,5,6,7]. Meanwhile, the extrinsic causes are typically found

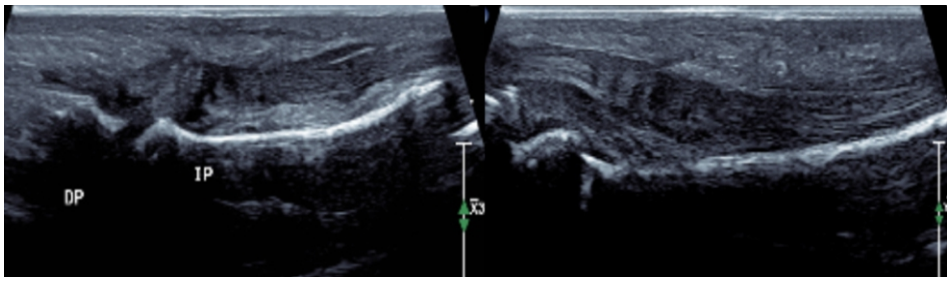

Figure 2: Ultrasound sonography investigation – right little finger flexor digitorum superficialis and flexor digitorum profundus from Flexor Zone 1 - Zone 2.

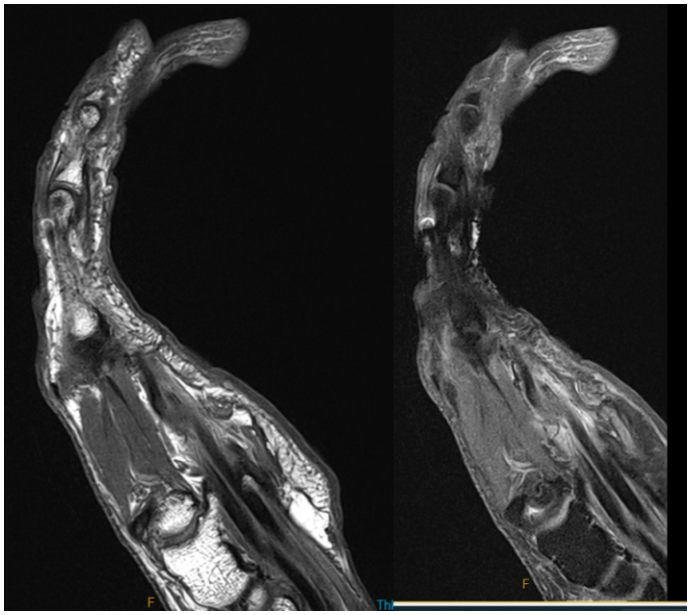

Figure 3: Right hand magnetic resonance imaging – Discontinuity of flexor digitorum profundus (FDP) tendon at the level of fifth metacarpal, but distal FDP tendon at metacarpophalangeal joint and distal interphalangeal joint is intact. Flexor digitorum superficialis is intact.

Case Report

Case

A 58-year-old gentleman presented to the emergency department with an acute onset of inability to actively flex his right little DIP joint following by pulling a door with his little finger on a Sunday evening. The mechanism of his injury was described as a closed Jersey finger injury associated with a "pop" sensational pain.

Aside from being right-hand dominant, he previously had multiple upper limb injuries including right rotator cuff tear repair, left biceps tendon rupture repair, and ongoing left shoulder rotator cuff tear pathology. His other medical background includes treated hepatitis C, diverticulosis, benign colonic polyps, ex-marijuana user, ex-smoker, and right tibial intramedullary nail fixation post motorbike accident. Otherwise, he denied any inflammatory/autoimmune arthropathy, recent right-hand fracture, repetitive/antecedent hand symptoms, malignancy, or fluoroquinolone antibiotic usage.

On examination, his right little finger had an abnormal resting attitude with a 20° DIP flexor lag deformity with FDP power loss grade 3/5, as well as absent tenodesis effect of his little

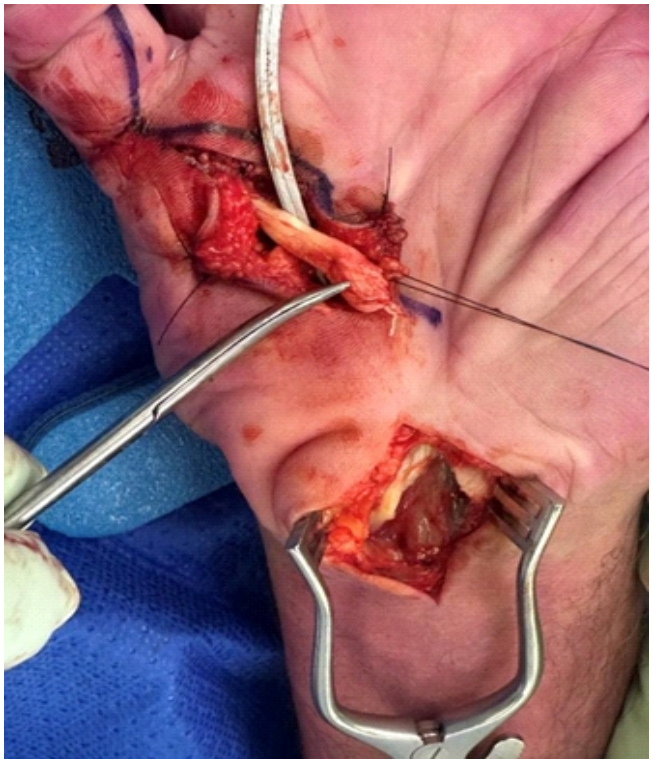

Figure 4: Intra-op photography of the distal stump at A1 pulley level. Carpal tunnel surgical wound with inflamed synovial tissue.

finger following passive wrist extension. He is also found with an unusual presentation of diffuse tenderness along the A1 pulley toward zone 3 and 4 metacarpal levels. Otherwise, the rest of his right-hand physical examination is unremarkable.

His right-hand X-ray illustrated that there is no fracture or abnormal lesion, but there is some subtle fifth digit ulnar deviation (Fig. 1). An ultrasound investigation pre-operatively was performed, suspecting a zone 1 flexor tendon avulsion rupture injury (Leddy and Packer Classification type1) [1] while commencing on an ulnar position of safety immobilization (POSI) cast to avoid retraction of ruptured tendon ends.

Surprisingly, his ultrasound formal report demonstrated that his little finger FDP and flexor digitorum superficialis (FDS) tendon appear intact from flexor zone 1 to zone 2 levels (Fig. 2). Because of his unusual clinical presentation and negative ultrasound findings, an MRI scan was requested to identify levels of tendon rupture. This demonstrated a full-thickness fifth FDP rupture at metacarpophalangeal (MCP) flexor zone 3 level (distal stump location) with an intact FDP tendon at the DIP/MCP joint. Nevertheless, the proximal stump could not be identified from flexor zone 1 to zone 4, indicating potentially located more proximally in flexor zone 5 or within his carpal tunnel anatomy (Fig. 3).

Operative procedure and intra-operative findings

Under general anesthesia, the absence of tenodesis effect was noted. A Brunner incision approach was made directly over the right fifth MCP flexor zone 2-3, which revealed that a portion of the fifth FDP tendon was underneath the A1 pulley. Meanwhile, his FDS, neurovascular bundles, and superficial palmar arch bundles were intact and protected. After partially releasing the A1 pulley, his fifth FDP tendon distal stump was found entrapped within the pulley, which appeared to be an attrition rupture with friable tendon end surrounding extensive-thicken inflammatory synovitis tissue (Fig. 4). However, the proximal tendon stump could not be identified at flexor zone 3-4 despite using tendon passer instrument, which was consistent with our MRI investigation result.

To locate the FDP tendon proximal stump, a separated carpal tunnel surgical incision wound was made and we proceeded with carpal tunnel release while protecting the median nerve. We identified that the proximal stump was found entrapped within the carpal tunnel with similar attrition rupture with friable tendon appearance surrounding extensive synovitis tissue (Fig. 5).

The proximal stump of FDP was further bypassed from the carpal tunnel surgical window to the distal end with the tendon passer instrument. Due to unhealthy and friable attrition tendon rupture stump ends, we determined to trim the tendon

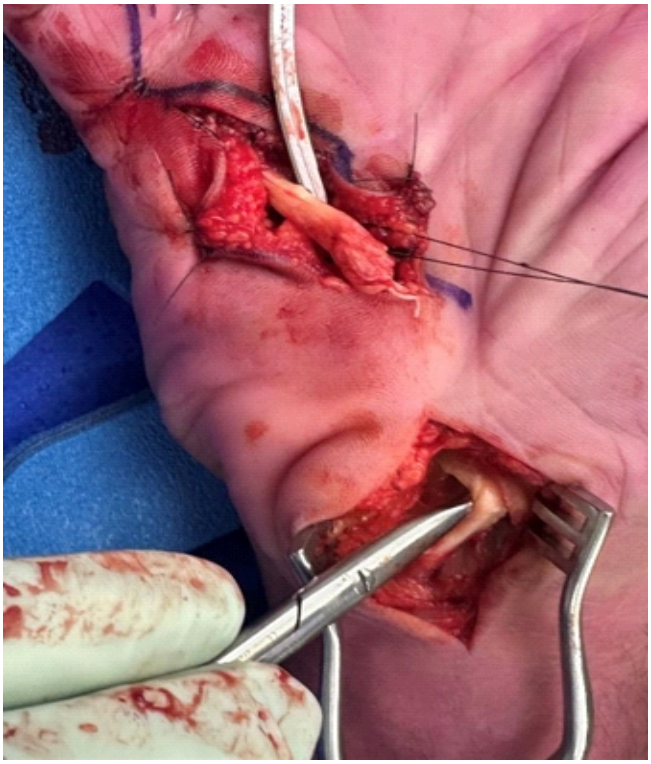

Figure 5: Intra-operative photography of the proximal stump at the carpal tunnel level.

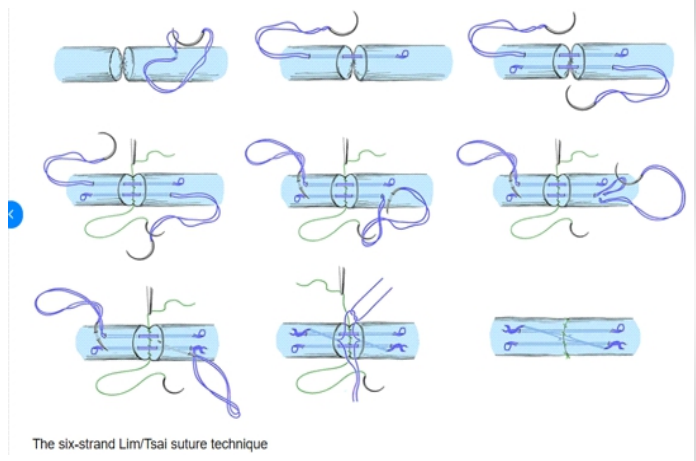

Figure 6: Lim-Tsai tendon 6-strand repair technique [10, 11].

by a total of 0.5 cm shorter and then repaired it primarily with Lim-Tsai Tendon repair technique using x2 Arthrex 4-0 Fiber Loop suture in a six-strand cruciate fashion (Fig. 6) [10,11]. The repaired tendon was further reinforced with a circumferential continuous running fashion with a 5-0 Prolene suture. Before wound closure, we also ensured that his right little finger attitude was within normal finger cascade without contracture as well as restoring his little finger digital flexion cascade with the presence of tenodesis effect. Following his incision wound closure, an ulnar POSI cast was applied for temporary protection before his first occupational hand therapy clinic review.

Post-operative hand therapy recovery protocol

Upon his day 3 post-operative recovery, the patient was transitioned to a removable dorsal blocking splint and commenced on an early active range of motion (ROM) flexor protocol with passive flexion and active extension hand exercises with our hospital occupational hand therapy clinic.

During his weeks post-operative wound review, the patient had an uneventful surgical wound recovery with normal little finger resting attitude and preserved tenodesis effect (Fig. 7). His initial post-operative complication includes parathesis sensation over the thumb and sensitive over his carpal tunnel surgical wound, but these eventually resolved with hand ROM exercise, gentle desensitization hand-therapy, and tubigrip compression.

Although he initially had rapid fatigue during hand exercises, his hand function further improved with position modifications and weekly hand-therapy rehabilitation with the goal of returning to his baseline functions such as laying asphalt, riding motorbike, and more importantly, enjoying fishing for his retirement. During his 6th-week post-operative follow-up visit, the patient was discharged with satisfactory finger flexion/extension ROM and strong grip noted.

Discussion

After following a forceful DIP extension blunt injury, flexor tendon avulsion rupture mostly occurs at the tendon insertional site attaching to the base of distal phalanx in the flexor zone 1. Spontaneous flexor tendon ruptures within Zone 3 are uncommon and clinically masquerade as a "Jersey finger" injury, which can lead to challenges in both conducting diagnosis and surgical interventions [1,2,4].

In this study, we present a rare clinical case of little finger zone 3 flexor tendon ruptures over the MCP following a "Jersey finger" mechanism of injury. Surprisingly, our surgical exploration reveals that the distal ruptured tendon stump is identified within the A1 pulley, while the proximal stump is entrapped within the carpal tunnel ligament. Moreover, our intra-operative findings demonstrate that the ruptured tendon stumps appear to be friable attrition surrounding extensive synovitis tissue. Unfortunately, we did not take any biopsy samples in this case report study.

To further stratify the risk of flexor zone 3 tendon ruptures, a recent systematic review study (n = 27) from Mungalpara, et al. illustrates that the potential mechanisms of injuries associated with "pop" sensation include resisted flexion of the distal

Figure 7: 2-week post-operative surgical wound outcome with normal right little finger resting attitude.

interphalangeal joint (DIPJ), sudden hyperextension of DIPJ, hyperextension of flexed finger, blunt palmar trauma, or even the "Jersey finger" mechanism [3,12]. Over the past 60 years, 33 out of 66 cases were involved with isolated fifth digit FDP zone 3 tendon ruptures, which appeared to be the most common digit [3,12,13,14,15,16,17,18].

Overall, we conclude that Zone 3 flexor tendon rupture injuries must be assessed with thorough history of the above mechanism of injury, identifying risk factors, and clinical examination including palpation from the flexor zone 1-4 and over the carpal tunnel level. Moreover, objective diagnostic tools such as ultrasound including flexor zone 1-4 or MRI investigations can be crucial not only to precisely identify the locations of ruptured tendon stumps but also to effectively execute the surgical plan by minimizing incision wound extension, surgical time, and surgeon's fatigue with cost-effectiveness considerations [18]. As a result, patients can benefit from having minimal surgical scar tissue with maximal early functional recovery.

Conclusion

This case report illustrates that zone 3 concealed FDP tendon ruptures can potentially masquerade as common zone 1 DIPJ flexor tendon avulsion injury. The mechanism of injury could be innocuous and incongruent with the pathology as it involved pulling and pushing a standard household doorknob. Thus, detailed clinical examination with adjunct ultrasound or even MRI investigations is valuable to identify the precise location of severed tendon stumps. As a result, patients can benefit from having minimal surgical scar tissue while reducing the risk of infection and regaining early functional recovery.

Clinical Message

Zone 3 mid-substance FDP tendon ruptures can rarely mimic Jersey finger injury. Therefore, thorough clinical assessment and radiographic investigations are crucial to precisely conduct minimal invasive surgical approach while optimizing patients' functional outcomes.

Declaration of patient consent: The authors certify that they have obtained all appropriate patient consent forms. In the form, the patient has given the consent for his/ her images and other clinical information to be reported in the journal. The patient understands that his/ her names and initials will not be published and due efforts will be made to conceal their identity, but anonymity cannot be guaranteed.

Conflict of interest: Nil **Source of support:** None

References

1. Ahn L. Flexor Tendon Injuries - Hand - Orthobullets; 2019. Available from: https://www.orthobullets.com/hand/6031/flexor-tendon-injuries [Last accessed on 6 May 2026].

2. Jersey Finger - Hand - Orthobullets. Available from: https://www.orthobullets.com/hand/6015/jersey-fingerc [Last accessed on 6 May 2026].

3. Mungalpara N, Peresada D, Mejia A. Flexor tendon injuries in zone 3: A comprehensive review and case report on flexor digitorum profundus rupture of the middle finger. J Orthop Case Rep 2025;15:46-56.

4. Ertel AN. Flexor tendon ruptures in rheumatoid arthritis. Hand Clin 1989;5:177-90.

5. Kelleher JC. Spontaneous rupture of the flexor tendons of a little finger due to projection of the hook of the hamate. A case report. Plast Reconstructive Surg 1983;72:583.

6. Masada K, Kanazawa M, Fuji T. Flexor tendon ruptures caused by an intraosseous ganglion of the hook of the hamate. J Hand Surg Br 1997;22:383-5.

7. Ashall G. Flexor pollicis longus rupture after fracture of the distal radius. Injury 1991;22:153-5.

8. Roberts JO, Regan PJ, Roberts AH. Rupture of flexor pollicis longus as a complication of Colles' fracture: A case report. J Hand Surg Br 1990;15:370-2.

9. Kannus P, Józsa L. Histopathological changes preceding spontaneous rupture of a tendon. A controlled study of 891 patients. J Bone Joint Surg Am 1991;73:1507-25.

10. Wirtz C, Leclère FM, Oberfeld E, Unglaub F, Vögelin E. A retrospective analysis of controlled active motion (CAM) versus modified Kleinert/Duran (modKD) rehabilitation protocol in flexor tendon repair (zones I and II) in a single center. Arch Orthop Trauma Surg 2023;143:1133-41.

11. Wong YR, Lee CS, Loke AM, Liu X, Suzana MJ, Tay SC. Comparison of flexor tendon repair between 6-strand Lim-Tsai with 4-strand cruciate and Becker technique. J Hand Surg Am 2015;40:1806-11.

12. Lee JS, McGrouther DA. Are flexor tendon ruptures ever spontaneous? - a literature review on closed flexor tendon ruptures of the little finger. J Hand Surg Asian Pac Vol 2019;24:180-8.

13. Bois AJ, Johnston G, Classen D. Spontaneous flexor tendon ruptures of the hand: Case series and review of the literature. J Hand Surg Am 2007;32:1061-71.

14. Thitiworakarn N, Vinitpairot C, Jianmongkol S. Closed spontaneous rupture of the flexor tendon in zone 3: A case series. J Southeast Asian Orthop 2022;46:39-43.

15. El Zahran T, Collins K, Terk MR. Bilateral spontaneous rupture of the flexor digitorum superficialis and the flexor digitorum profundus in a diabetic patient. Skeletal Radiol 2013;42:297-301.

16. Hashizume H, Nishida K, Fujiwara K, Inoue H. Spontaneous "spaghetti" flexor tendon ruptures in the rheumatoid wrist. Mod Rheumatol 2004;14:257-9.

17. Yoon JH, Jung JS, Kim H. Spontaneous zone III flexor tendon rupture of the little finger: A case report. J Wound Manage Res 2022;18:53-7.

18. Drapé JL, Tardif-Chastenet De Gery S, Silbermann-Hoffman O, Chevrot A, Houvet P, Alnot JY, et al. Closed ruptures of the flexor digitorum tendons: MRI evaluation. Skeletal Radiol 1998;27:617-24.

Conflict of Interest: Nil
Source of Support: Nil

Consent: The authors confirm that informed consent was obtained from the patient for publication of this article

How to Cite this Article

Wu A, Varughese I, Caudwell M. An Unusual Presentation of Right fifth Flexor Digitorum Profundus Tendon Zone 3 Rupture Following Jersey Finger Mechanism Injury. Journal of Orthopaedic Case Reports 2026 October;16(10): 270-275.