Original Article | Journal of Orthopaedic Case Reports 2026 October:16(10):Page 314-319

Morphometric Variants of the Coccyx in an Eastern Indian Cohort: Analysis from a Tertiary Care Center

Manoj K Nayak[1], Biswajit Sahoo[1], Sneha Aribaskar[1], M Mayur[2], Mantu Jain[2], Kulbhushan Kamboj[3]

Learning Point of the Article:

In the eastern Indian population, Type I coccyx with four segments is the most common morphology, and the coccyx tends to be relatively straighter, providing important baseline anthropometric data that may help explain patterns of idiopathic coccydynia and allow comparison with other Southeast Asian populations.

Abstract

Introduction: The coccyx, forming the terminal portion of the human spine, has anatomical variations among countries, populations, and ethnicities. Given its complex structure involving multiple ligaments, muscles, and neural elements, the study of anatomical variations can provide valuable insight into the mechanisms underlying idiopathic coccydynia. Due to limited existing research on the morphometry of the Indian population, this study aims to examine the morphometry observed in the eastern Indian population.

Materials and Methods: A cross-sectional study of coccyx morphometry was conducted on patients who visited the radiology department of a tertiary care hospital in eastern India. A total of 109 patients were included, who had a computed tomography scan of the abdomen and pelvis. Patients with complaints of tumors or trauma to the spine were excluded. The coccygeal images were evaluated using the modified classification by Nathan et al.

Results: Among the 109 patients, Type I coccyx was the most common type, with four segments in the coccyx. The mean straight and curved sacral lengths are 10.38 cm and 11.08 cm, and the straight sacrococcygeal length is 11.9 cm. The mean sacrococcygeal angle and intercoccygeal angle are 116.2° and 38.99°, respectively. Coccygeal spicules were seen in 30.3% of patients. 74.3% of the population had no intercoccygeal or sacrococcygeal joint subluxation.

Conclusion: Our analysis showed Type I of the coccyx was the most prevalent type, with four segments being most common. Our study also indicated that our population has a straighter coccyx. Our study can be correlated with the Southeast Asian population and can act as a baseline study for future anthropometric studies.

Keywords: Coccyx morphometry, coccydynia, coccyx, India.

Introduction

The coccyx is located at the end of the vertebral column, also known as the tailbone. It is considered a vestigial part of the human body [1]. It is also involved in weight-bearing and is a dynamic structure that alters its position during sitting and standing. It also serves as a site for the attachment of various ligaments and structures in the pelvis. The study of the coccyx can be executed by studying cadavers, radiographs, computed tomography (CT), and magnetic resonance imaging (MRI) [2,3]. Coccydynia was initially described by Simpson in 1859 as severe pain in the coccyx region provoked by sitting or changing the position from sitting to standing [4]. Coccydynia can be due

Access this article online

Website: www.jocr.co.in

DOI: https://doi.org/10.13107/jocr.2026.v16.i10.8278

Author's Photo Gallery

Dr. Manoj K Nayak

Dr. Biswajit Sahoo

Dr. Sneha Aribaskar

Dr. M Mayur

Dr. Mantu Jain

Dr. Kulbhushan Kamboj

[1]Department of Radiology, All India Institute of Medical Sciences, Bhubaneswar, Odisha - 751019, India,
[2]Department of Orthopaedics, All India Institute of Medical Sciences, Bhubaneswar, Odisha - 751019, India,
[3]Department of Orthopaedics, All India Institute of Medical Sciences, Rajkot, Gujarat -360006, India.

Address of Correspondence:
Dr. Mantu Jain,
Department of Orthopaedics, All India Institute of Medical Sciences, Bhubaneswar - 751019, Odisha, India.
E-mail: montu_jn@yahoo.com

Submitted: 15/07/2026; Review: 02/08/2026; Accepted: September 2026; Published: October 2026

DOI: https://doi.org/10.13107/jocr.2026.v16.i10.8278

© The Author(s). 2026 Open Access. This article is distributed under the terms of the Creative Commons Attribution 4.0 International License (https://creativecommons.org/licenses/by-nc/4.0/), which permits unrestricted use, distribution, and non-commercial reproduction in any medium, provided you give appropriate credit to the original author(s) and the source, provide a link to the Creative Commons license, and indicate if changes were made. The Creative Commons Public Domain Dedication waiver (http://creativecommons.org/publicdomain/zero/1.0/) applies to the data made available in this article, unless otherwise stated.

Table 1: The classification proposed by Nathan *et al*.

Class	Definitions
Type I	The coccyx is slightly curved downward
Type II	The coccyx has a marked curve with the apex pointing forward.
Type III	The coccyx is angled forward sharply between the first and second or second and third segments
Type IV	Anteriorly subluxated at the level of the sacrococcygeal joint or first intercoccygeal joint of the coccyx
Type V	Coccygeal retroversion
Type VI	Coccygeal scoliotic

to various causes, and the majority (1/3rd of them) is idiopathic; other known causes include trauma after childbirth, long hours of sitting on hard surfaces, disc changes, inflammation, and even obesity and female gender [5,6].

The morphometry of the coccyx enhances the existing literature and aids in comprehending idiopathic coccydynia. There is a scarcity of data regarding the pattern and morphology in the Indian population. Consequently, this study conducted a morphological assessment of the coccyx in the eastern Indian population at a tertiary care center.

Materials and Methods

A cross-sectional study of coccyx morphometry was conducted on patients visiting the radiology department of a tertiary care hospital in eastern India. The study was started after approval by the Institutional Ethics Committee of AIIMS Bhubaneswar (T/IM-NF/Radiod/24/182). Following the Declaration of Helsinki (2013) and adherence to good clinical practices, this study was carried out from January to December 2025. Written informed consent was obtained from each patient.

Using Enmaster2.0 software, we set the correlation coefficient to 0.4, the power to 80%, and the confidence interval to 90%; this resulted in a calculated sample size of 41. However, we included 109 patients who had undergone CT scans of the abdomen and pelvis for various causes in the prior 6 months. Patients with complaints of trauma to the spine or tumors involving the spine were excluded from our study.

These scans were acquired by a 256 Slice Somatom Definition Flash CT by Siemens Healthcare GmbH with a slice thickness of 1–1.5 mm, and measurements were taken by an experienced radiologist.

The coccygeal images were evaluated using the modified classification by Nathan et al., as depicted in Table 1 [7].

The morphometric variables were assessed on multidetector computed tomography as suggested by Woon et al,Marwan et al. and Yoon et al., as described in Table 2 [2,8,9]. The measurement parameters are shown in Figs. 1-3.

The data were entered in an Excel sheet. The patient information in these scans was masked carefully to maintain confidentiality. Two observers independently classified cases. Interobserver reliability was assessed using Cohen's kappa coefficient. Finally, the data were analyzed descriptively using the Statistical Package for the Social Sciences v30.

Results

The study included 109 patients: 56 males and 53 females. Based on Nathan et al.'s modified classification, the most common coccyx type was Type I (41.3%), followed by Type II (19.3%). The coccyx was found to have four segments (58.7%), most commonly, followed by three segments (24.8%). The

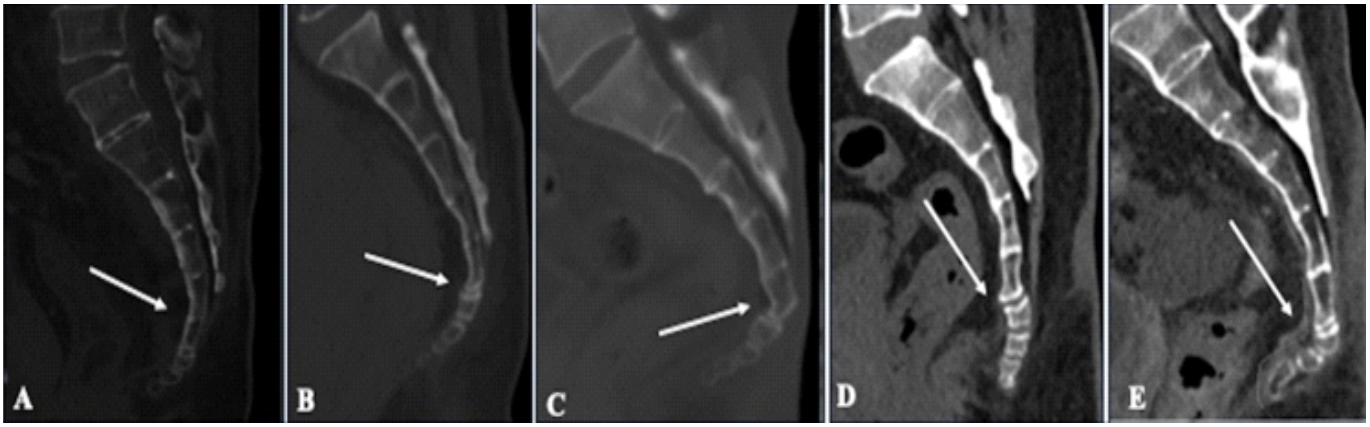

Figure 1: The type of coccyx on a sagittal computed tomography (CT) scan. (a) Type I coccyx: The coccyx is slightly curved downward (arrow). (b) Type II coccyx: The coccyx has a marked curve with the apex pointing forward (arrow). (c) Type III coccyx: The coccyx is angled forward sharply between the first and second or second and third segments (arrow). (d) Type IV coccyx: Anteriorly subluxated at the level of the sacrococcygeal joint or first or second intercoccygeal joint of the coccyx (arrow). (e) Type V coccyx: Coccygeal retroversion (arrow).

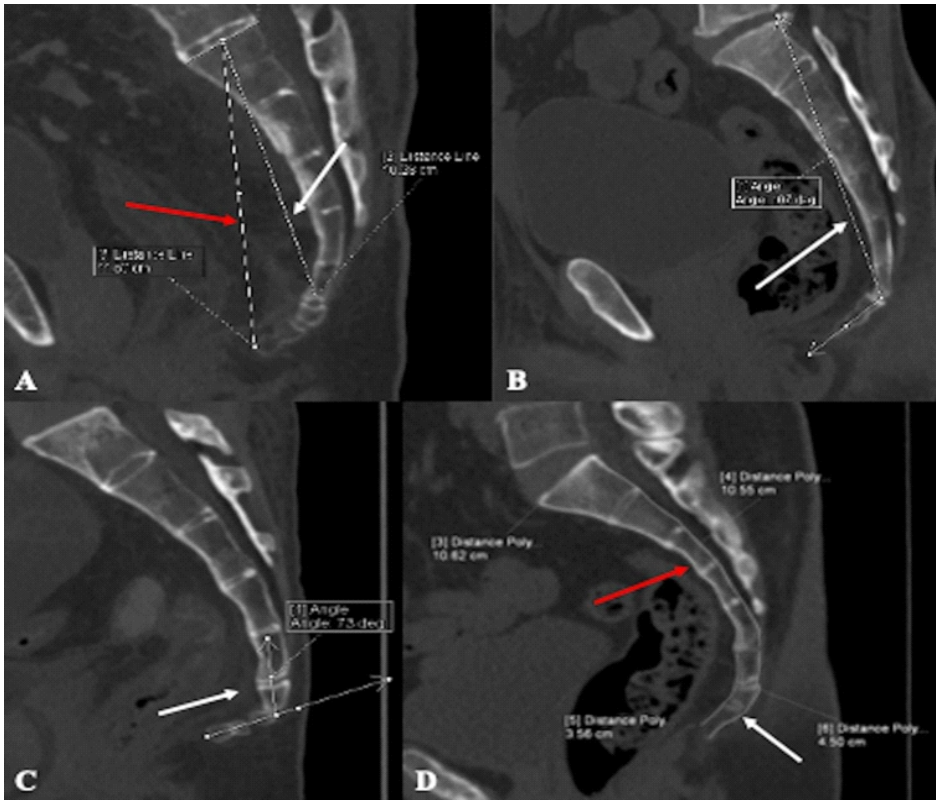

Figure 2: Different measurements of a sagittal computed tomography (CT) scan. (A) STRAIGHT Sacral length: A straight line joining the midpoint of the upper border of S1 to the midpoint of the inferior border of S5, distance line 2 in Figure 2a (white arrow); Straight Sacrococcygeal length: A straight line joining the midpoint of the upper border of S1 to the tip of the coccyx, distance line 3 in Figure 2a (red arrow). (b) Sacrococcygeal angle: Angle between the line joining the midpoint of the upper border of S1–1st coccyx and the line between the 1st and last coccyx segment (white arrow). (c) Showed the intercoccygeal angle: Angle between the line drawn parallel to the long axis of the 1st coccyx segment and the line parallel to the long axis of the last coccyx segment in midsagittal position (white arrow). (d) Showed coccygeal curved length: Mean of the anterior and posterior curved coccygeal lengths measured from the upper border of the 1st coccyx segment to the tip of the coccyx (white arrow) and Sacral curved length: Mean of the anterior and posterior curved sacral lengths measured from the upper border of S1 to the inferior border of S5 (red arrow).

various dimensions related to the coccyx are described in a tabular manner (Tables 3-5).

Sacralization of the first coccygeal segment was around 12.8%, and coccygeal spicules were seen in 30.3%. Sacrococcygeal and intercoccygeal joint fusion was seen in 32.1% and 67.9% of the study population, respectively. Intercoccygeal joint fusion occurred in 67.9% of people, with the 2nd–4th joints most common at 18.4%, and full coccyx fusion in 1.8%. Subluxation of the intercoccygeal segments was most commonly seen at the C1-C2 vertebral level in 15.6% of the study population. In comparison, 74.3% of the population had no intercoccygeal or sacrococcygeal joint subluxation (Table 6).

The calculated Cohen's kappa value was 0.67, indicating substantial agreement between observers.

Discussion

The coccyx is considered to be a mobile structure rather than a static one and usually contains 3–5 segments [2,10]. Just as the morphology of the skeleton varies between countries, ethnicities, and even small communities, the coccyx also has many variations in its morphology. There are only a handful of data available on the Asian population and less data on the Indian population. Notably, the coccyx is a site for attaching several structures such as ligaments, tendons, and ganglions [11]. The morphological variations in the coccyx may lead to an imbalance in the forces acting on the surrounding structures. They can also lead to pain referred to as coccydynia, which was initially described by Simpson in the year 1859 as severe pain in the coccyx region provoked by sitting or changing the position from sitting to standing.[12] Females are more prone to develop coccydynia than males [13]. The dissimilarity in the female and male pelvis anatomy was proposed by Duncan [14].

Radiographs are the initial modality of investigation for the coccyx, and dynamic acquisitions can be made using sitting and standing X-rays. However, due to poor resolution and overlapping soft tissue, these are suboptimal for evaluation. Cross-sectional imaging such as CT clarifies the bony anatomy of the coccyx, whereas MRI provides detailed views of soft tissues and ligaments.

Postacchini and Massobrio were the pioneers in presenting a classification of coccyx morphology in radiographs [15]. Following this, Nathan et al. presented a revised classification of coccygeal morphology, describing six categories [7].

A study on Korean cohorts and the Chinese population showed Type II to be the most common (51%) [9,16], and an MRI-based study in the Nepalese population by Paudyal et al. also showed Type II (46.3%) as the most common, followed by Type I (40.5%) [17]. However, in our study, the predominant coccyx type was Type I (41.3%), followed by Type II (19.3%). These are similar to the European study that showed Type I being the most common (64%), followed by Type II (16%) [2]. Marwan et al. also found type I (47.5%) in arab population.[8] This finding reflects a notable ethnic variation. However,

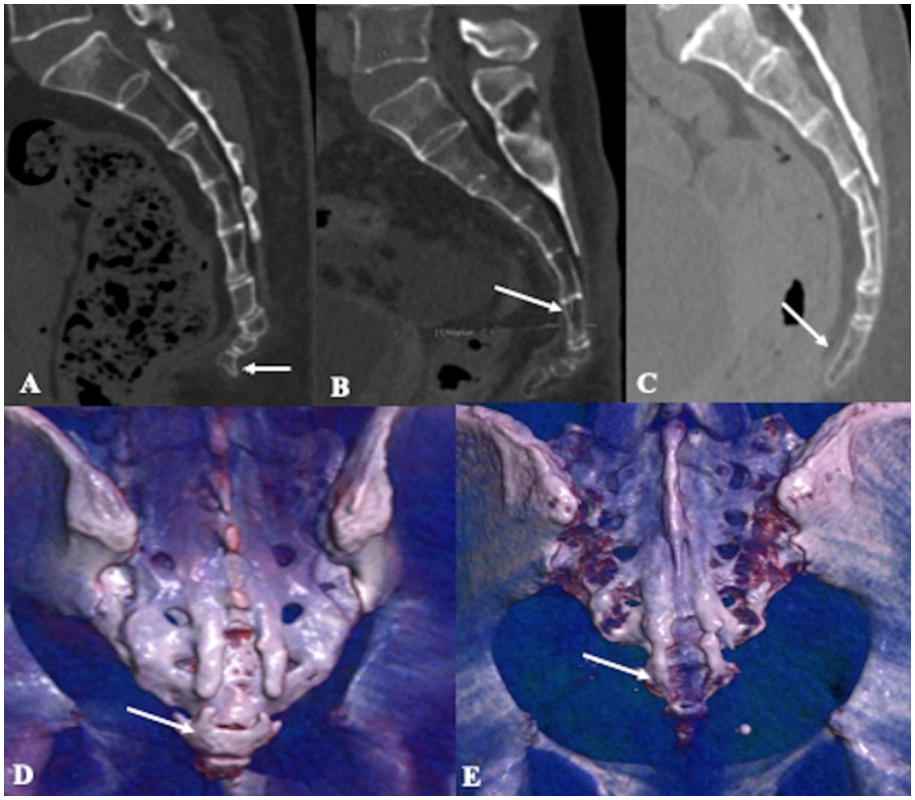

Figure 3: The morphologic variations in the coccyx on computed tomography (CT) scan and volume rendered technique (VRT) images of a sagittal NCCT image. (a) Coccygeal spicule: A bone spicule projecting from the terminal coccygeal segment (white arrow). (b) Sacrococcygeal joint fusion (white arrow). (c) Intercoccygeal joint fusion (white arrow). VRT images. (d) Bilateral sacralization of coccyx (white arrow) and (e) bilateral partial sacralization of the coccyx (white arrow).

remarkably, we found a relatively high prevalence of Type IV (18.3%), which may suggest a regional or lifestyle influence. In our study, most subjects had four coccygeal segments (58.7%), followed by three segments (24.8%). Similar findings were noted in both the European (76%) and Korean (64.8%) cohorts, but the Nepalese cohort showed three segments (45.3%) to be more common [2,9,17].

Types III to VI were found to have a significantly higher incidence in patients with coccydynia than Type II, followed by Type I, which is shown to have the lowest incidence. We have a higher incidence of Type I in our cohort. Shams et al. compared the coccygeal features of patients with and without coccydynia using MRI and reported Type II as the most common morphology in their coccydynia cohort [18].

Sacrococcygeal joint fusion was 32.1%, similar to the 34% reported by Yoon et al. but lower than Woon et al.'s 57%. 2.9 intercoccygeal fusion in our study was seen in 67.9% [2]. Paudyal et al. noted similar fusion patterns, suggesting comparable prevalence across South Asian populations [17].

The mean sacrococcygeal angle in our study was 116.3°, slightly higher than the values observed by Woon et al. (106° ± 13°), Paudyal et al. (107.1°), and Yoon et al. (110°) [2,17]. Similarly, our mean intercoccygeal angle was 39°, lower than Korean males (53.9°) and females (44.7°), potentially indicating a straighter coccyx in our Indian population.

Coccygeal spicules were present in 30.3% of our subjects, which is higher than the 23% prevalence reported by Woon et al. and 11.6% in Paudyal et al.'s MRI study [2,17]. This discrepancy may stem from differences in imaging modality sensitivity (CT vs. MRI) or regional bone density patterns. Subluxation was observed only in about 25.7% of cases, with 74.3% not having any subluxation, which is a considerable proportion compared to Woon et al., where it is typically reported as rare (3%) [2]. Authors have reported that the presence of a posterior spicule is a significant factor in coccydynia, especially due to chronic adventitious bursitis, in at least 14% of coccydynia patients [5]. While subluxation does not always correlate with pain, its radiological presence can serve as an anatomical risk factor for coccydynia.

Sacralization was observed in 12.8% of cases, which is consistent

Table 2: The morphometric variables assessed on multidetector computed tomography

Morphometric variables	Definitions
Coccygeal straight length	Measured in a straight line from the middle of the upper border of Co1 to the coccygeal tip.
Coccygeal curved length	Mean of the anterior and posterior curved coccygeal lengths measured from the upper border of the 1st coccyx segment to the tip of the coccyx.
Sacral straight length	A straight line joining the midpoint of the upper border of S1 to the midpoint of the inferior border of S5.
Sacral curved length	Mean of the anterior and posterior curved sacral lengths measured from the upper border of S1 to the inferior border of S5.
Sacrococcygeal straight lengths	Measured from S1 to the tip of the coccyx as described above.
Sacrococcygeal angle	Angle between the line joining the midpoint of the upper border of S1 and 1st coccyx and the line between the 1st and last coccyx segment.
Intercoccygeal angle	Angle between the line drawn parallel to the long axis of the 1st coccyx segment and the line parallel to the long axis of the last coccyx segment in mid-sagittal position.

Table 3: Number of coccygeal segments present in the spine and prevalence of each type in our study population

No. of coccygeal segments	Frequency (%)
2	4 (3.7)
3	27 (24.8)
4	64 (58.7)
5	14 (12.8)
Total (*n*)	109

Table 4: Morphological type of coccyx in our study population

Coccyx morphological type	Frequency (%)
1	45 (41.3)
2	21 (19.3)
3	13 (11.9)
4	20 (18.3)
5	6 (5.5)
6	4 (3.7)
Total(n)	109

Table 5: Dimensions of sacral and coccygeal curved length, straight length, and sacrococcygeal and intercoccygeal angle

Measurement	Mean±SD (cm)
Sacral curved length	11.03±0.878
Coccygeal curved length	3.32±0.724
Sacral straight length	10.38±0.856
Sacrococcygeal straight length	11.99±1.16
Sacrococcygeal angle	116.28±11.81
Intercoccygeal angle	38.99±19.71

Table 6: Describes the frequency of coccygeal spicule, sacralization, sacrococcygeal and intercoccygeal joint fusion, and sacrococcygeal and intercoccygeal joint subluxation in our study population

Variables	Frequency (%)
Coccygeal spicule	33 (30.3)
Sacralization	14 (12.8)
Sacrococcygeal joint fusion	35 (32.1)
Intercoccygeal joint fusion	74 (67.9)
Sacrococcygeal and intercoccygeal joint subluxation	28 (25.7)

with other Asian studies and higher than the rates reported by Woon et al. in European populations [2]. Type I coccyx was the most common in our study, showing higher rates of joint fusion, coccygeal spicule presence, and increased sacrococcygeal angle. Our study included only the static scan performed in the supine position in adults, so dynamic alterations in the coccyx morphology could not be evaluated.

Strengths and limitations

The study is limited by its single-center design and lack of clinical correlation with symptoms such as coccydynia. In addition, morphometric data were derived from supine CT scans, which may not fully represent the weight-bearing configuration of the coccyx. A larger sample would better represent the spectrum of coccygeal morphology. However, our sample exceeded the calculated minimum sample size and provides important baseline morphometric data from an underrepresented eastern Indian population. Ours was a cross-sectional morphometric study, and symptoms/clinical outcomes/coccydynia could not be evaluated. Therefore, we could not compare the morphological differences between those with and without symptoms. Future studies can be longitudinal, incorporating dynamic imaging or correlations with age-stratified analysis, body mass index, occupational and lifestyle factors, obstetric history, and symptomatology. Multicenter studies involving different regions of India would enhance understanding.

Conclusion

In our CT-based cross-sectional study, we analyzed various morphological parameters of the coccyx to provide an understanding of its basic prevalent morphology in the Indian population. This study contributes vital regional anatomical data and aids orthopedic surgeons and pain specialists. The data from the analysis can be used as a baseline for future anthropological studies and comparative ethnicity-based morphometry studies.

Clinical Message

A predominantly Type I, relatively straight coccyx with four segments is the common anatomical pattern in the eastern Indian population, suggesting that deviations from this morphology – such as increased angulation, spicules, or joint subluxation – may have greater clinical relevance in patients presenting with idiopathic coccydynia.

Declaration of patient consent: The authors certify that they have obtained all appropriate patient consent forms. In the form, the patient has given the consent for his/ her images and other clinical information to be reported in the journal. The patient understands that his/ her names and initials will not be published and due efforts will be made to conceal their identity, but anonymity cannot be guaranteed.

Conflict of interest: Nil **Source of support:** None

References

1. Yagi F, Yamada Y, Yamada M, Yokoyama Y, Mukai K, Nakahara T, et al. Three-dimensional evaluation of the coccyx movement between supine and standing positions using conventional and upright computed tomography imaging. Sci Rep 2021;11:6886.

2. Woon JT, Perumal V, Maigne JY, Stringer MD. CT morphology and morphometry of the normal adult coccyx. Eur Spine J 2013;22:863-70.

3. Shalaby SA, Eid EM, Allam OA, Ali AM, Gebba MA. Morphometric study of the normal Egyptian coccyx from (age 1-40 year). Int J Clin Dev Anat 2015;1:32-41.

4. Woon JT, Stringer MD. Clinical anatomy of the coccyx: A systematic review. Clin Anat 2012;25:158-67.

5. Maigne JY, Rusakiewicz F, Diouf M. Postpartum coccydynia: A Case series study of 57 women. Eur J Phys Rehabil Med 2012;48:387-92.

6. Nasiri A, Farajzadeh Vajari F, Sane S, Afsargharehbagh R. Assessment of Ganglion impar block effect on treatment results of coccydynia: A cross-sectional study. Anesthesiol Pain Med 2024;14:e142137.

7. Nathan ST, Fisher BE, Roberts CS. Coccydynia: A review of pathoanatomy, aetiology, treatment and outcome. J Bone Joint Surg Br 2010;92-B:1622-7.

8. Marwan YA, Al-Saeed OM, Esmaeel AA, Kombar OR, Bendary AM, Azeem ME. Computed tomography-based morphologic and morphometric features of the coccyx among Arab adults. Spine (Phila Pa 1976). 2014;39(20):E1210-9.

9. Yoon MG, Moon MS, Park BK, Lee H, Kim DH. Analysis of sacrococcygeal morphology in koreans using computed tomography. Clin Orthop Surg 2016;8:412-9.

10. Fogel GR, Cunningham PY 3rd, Esses SI. Coccygodynia: Evaluation and management. J Am Acad Orthop Surg 2004;12:49-54.

11. Ashby K, Yilmaz E, Mathkour M, Olewnik Ł, Hage D, Iwanaga J, et al. Ligaments stabilizing the sacrum and sacroiliac joint: A comprehensive review. Neurosurg Rev 2022;45:357-64.

12. Simpson: On Coccyodynia, and the Diseases of the Coccyx. Available from: https://www.coccyx.org/medabs/simpson.htm [Last accessed on 2025 Jun 07].

13. Karadimas EJ, Trypsiannis G, Giannoudis PV. Surgical treatment of coccygodynia: An analytic review of the literature. Eur Spine J 2011;20:698-705.

14. Duncan GA. Painful Coccyx. Arch Surg 1937;34:1088-104.

15. Postacchini F, Massobrio M. Idiopathic coccygodynia. Analysis of fifty-one operative cases and a radiographic study of the normal coccyx. J Bone Joint Surg Am 1983;65:1116-24.

16. Feng H, Chen X, Cao C, Wan D, Liu H, Zhang E, et al. The susceptibility of coccydynia in morphology: A cross-sectional study. Pain Res Manag 2025;2025:2932223.

17. Paudyal S, Karna BP, Joshi BR. Evaluation of anatomical variation of human coccyx on magnetic resonance imaging. Nepal J Radiol 2022;12:2-6.

18. Shams A, Gamal O, Mesregah MK. Sacrococcygeal morphologic and morphometric risk factors for idiopathic coccydynia: A magnetic resonance imaging study. Global Spine J 2023;13:140-8.

Conflict of Interest: Nil
Source of Support: Nil

Consent: The authors confirm that informed consent was obtained from the patient for publication of this article

How to Cite this Article

Nayak MK, Sahoo B, Sneha A, Mayur M, Jain M, Kamboj K. Morphometric Variants of the Coccyx in an Eastern Indian Cohort: Analysis from a Tertiary Care Center. Journal of Orthopaedic Case Reports 2026 October;16(10):314-319.