Original Article | Journal of Orthopaedic Case Reports 2026 October:16(10):Page 400-407

Functional Outcome of Lucerne Cast in Patients with Metacarpal Fracture with or without Proximal Phalanx Fracture: An Observational Prospective Study

Prateek Sahu[1], Manmohan Shakya[1], Syed Tariq Mahamood[1], Mohit Dashore[1], Nilesh Gupta[1], Gautam Chatterji[1]

Learning Point of the Article:

Functional immobilization with the Lucerne cast permits movement of uninvolved joints and was associated with favorable short-term functional and radiological outcomes in appropriately selected closed metacarpal fractures

Abstract

Introduction: Metacarpal fractures are among the most common hand injuries encountered in clinical practice, predominantly affecting young, active adults. The Lucerne cast (LuCa) is a semi-rigid functional metacarpal cast that immobilizes the metacarpophalangeal joints in flexion while preserving wrist and interphalangeal joint motion. Evidence regarding its outcomes across varying fracture complexity remains limited.

Materials and Methods: This prospective observational study enrolled 30 adult patients with closed 2nd–5th metacarpal fractures, with or without proximal phalanx involvement, managed with the LuCa at a tertiary care center. Functional outcomes were assessed using the Michigan Hand Outcomes Questionnaire (MHQ) at 1, 4, 8, and 12 weeks. Radiological union and immobilization duration were recorded as secondary outcomes.

Results: The cohort was predominantly male (80%) with a mean age of 35.27 ± 9.95 years. Isolated metacarpal fractures constituted 83.3% of cases. Mean total MHQ scores improved significantly within both fracture groups from week 1 to week 12 ($P < 0.001$). No statistically significant between-group differences were observed in MHQ scores at the assessed follow-up points, immobilization duration, or timing of radiological union.

Conclusion: In this prospective observational study, LuCa immobilization was associated with progressive improvement in patient-reported hand function and satisfactory radiological healing over 12 weeks in appropriately selected closed metacarpal fractures, with or without associated proximal phalanx fractures.

Keywords: Lucerne cast, Metacarpal fracture, Michigan hand questionnaire, functional outcome, conservative management, proximal phalanx fracture.

Introduction

Metacarpal fractures are among the most frequently encountered skeletal injuries of the hand, accounting for a substantial proportion of upper-extremity fractures presenting to emergency and orthopedic services. These injuries predominantly affect young and economically productive individuals and may result in considerable functional impairment if inadequately managed. Although fracture

Access this article online

Website: www.jocr.co.in

DOI: https://doi.org/10.13107/jocr.2026.v16.i10.8300

Author's Photo Gallery

Dr. Prateek Sahu

Dr. Manmohan Shakya

Dr. Syed Tariq Mahamood

Dr. Mohit Dashore

Dr. Nilesh Gupta

Dr. Gautam Chatterji

[1]Department of Orthopaedics, Peoples College of Medical Sciences and Research Centre, Bhopal, Madhya Pradesh, India.

Address of Correspondence:
Dr. Manmohan Shakya,
Department of Orthopaedics, Peoples College of Medical Sciences and Research Centre, Bhanpur, Bhopal - 462037, Madhya Pradesh, India.
E-mail: mannmbbs@gmail.com

Submitted: 12/07/2026; Review: 09/08/2026; Accepted: September 2026; Published: October 2026

DOI: https://doi.org/10.13107/jocr.2026.v16.i10.8300

© The Author(s). 2026 Open Access. This article is distributed under the terms of the Creative Commons Attribution 4.0 International License (https://creativecommons.org/licenses/by-nc/4.0/), which permits unrestricted use, distribution, and non-commercial reproduction in any medium, provided you give appropriate credit to the original author(s) and the source, provide a link to the Creative Commons license, and indicate if changes were made. The Creative Commons Public Domain Dedication waiver (http://creativecommons.org/publicdomain/zero/1.0/) applies to the data made available in this article, unless otherwise stated.

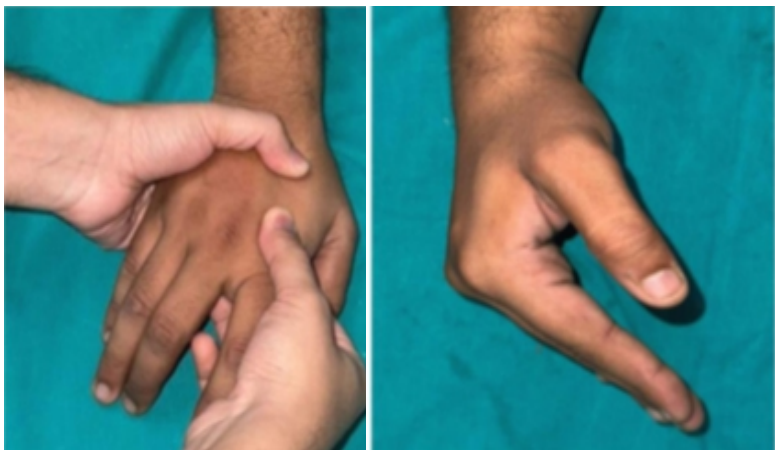

Figure 1: (a) Initial reduction, (b) Positioning of joints.

characteristics vary according to the mechanism of injury and the involved ray, the majority of non-thumb metacarpal fractures can be treated successfully using non-operative methods when acceptable alignment and rotational stability are maintained [1, 2]. The fifth metacarpal, particularly the neck region, is the most commonly affected site, and restoration of hand function remains the principal objective of treatment [1].

Contemporary management of metacarpal fractures emphasizes not only fracture union but also preservation of joint mobility and prevention of stiffness. Excessive immobilization may contribute to tendon adhesions, reduced range of motion, and delayed functional recovery. Consequently, modern conservative treatment strategies increasingly advocate functional immobilization techniques that provide adequate fracture stability while permitting early movement of uninvolved joints [2,3]. Recent literature has highlighted the importance of rehabilitation-oriented management approaches in optimizing outcomes following metacarpal injuries, particularly among active individuals who require rapid return to daily and occupational activities [3].

The Lucerne cast (LuCa) is a semi-rigid functional metacarpal cast specifically designed to immobilize the metacarpophalangeal (MCP) joints in flexion while preserving motion at the wrist and interphalangeal joints. By maintaining MCP flexion, the cast reduces deforming forces across the fracture site and facilitates fracture stability without unnecessarily restricting adjacent joint motion. This biomechanical principle is consistent with current concepts of functional fracture care, which aim to balance immobilization with early mobilization of unaffected structures [2, 4].

The management of associated proximal phalanx fractures presents an additional challenge because hand function depends on coordinated motion across multiple joints. Recent systematic reviews have demonstrated that stable extra-articular proximal phalanx fractures can often be managed successfully with conservative treatment protocols incorporating controlled MCP flexion and free mobilization of the interphalangeal joints, achieving high union rates and favorable functional outcomes [5, 6]. However, evidence evaluating whether the coexistence of proximal phalanx fractures influences recovery when treated using functional casting techniques remains limited.

Assessment of treatment effectiveness in hand trauma increasingly relies on validated patient-reported outcome measures. The Michigan Hand Outcomes Questionnaire (MHQ) is one of the most widely accepted instruments for evaluating hand-specific function, activities of daily living (ADL), pain, work performance, esthetics, and patient satisfaction. Its reliability, validity, and responsiveness have been demonstrated across a broad spectrum of hand conditions and injuries, making it particularly suitable for longitudinal assessment of recovery following fracture treatment [7].

Despite growing interest in functional immobilization techniques, prospective evidence examining the outcomes of the LuCa in patients with metacarpal fractures, particularly those with concomitant proximal phalanx involvement, remains scarce. Therefore, the present study was undertaken to evaluate the functional outcomes of LuCa immobilization in

Figure 2: Design of the cast.

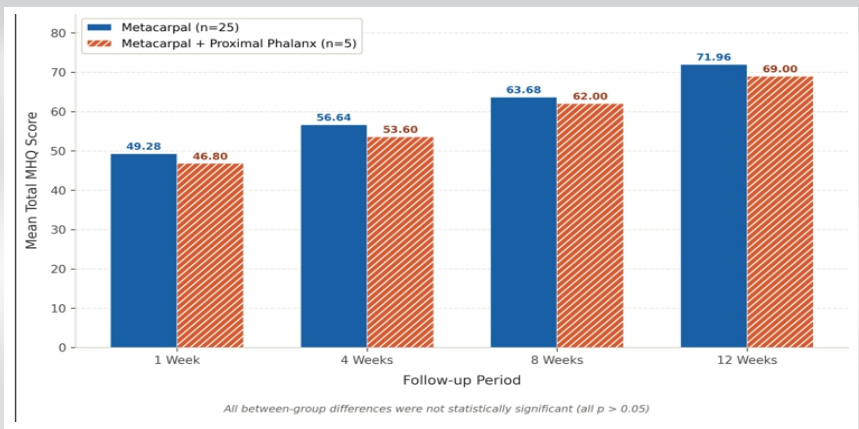

Figure 3: Mean total Michigan Hand Outcomes Questionnaire score by fracture type at each follow-up.

patients with metacarpal fractures with or without associated proximal phalanx fractures using serial MHQ assessment and radiological follow-up.

Materials and Methods

Study design and setting

This was an observational prospective study conducted at the Department of Orthopaedics, Peoples College of Medical Sciences and Research Centre, Bhopal, Madhya Pradesh, India – a tertiary care teaching institution. Patients presenting to the Outpatient Department and Emergency Services with metacarpal fractures of the 2nd through 5th rays, with or without proximal phalanx involvement, were enrolled over the study period from April 2024 to September 2025.

Sample size and sampling technique

Thirty patients who fulfilled the eligibility criteria were included using a consecutive sampling strategy, whereby every consenting eligible patient presenting during the study period was enrolled sequentially until the target sample was reached.

Eligibility criteria

Patients aged 18 years or older presenting with fractures of the 2nd to 5th metacarpals – involving the neck, shaft, or extra-articular region – with or without an associated proximal phalanx fracture, were considered for inclusion. Fractures of the first ray (thumb metacarpal) were excluded. Patients were not enrolled if they had compound fractures, metacarpal shortening from segmental bone loss, irreducible dislocations, or if operative management was deemed necessary. Additional exclusion criteria comprised pre-existing impaired hand function attributable to arthritis or neurological conditions, concomitant injuries in the ipsilateral upper limb, disorders of bone metabolism other than osteoporosis (such as Paget's disease, renal osteodystrophy, or osteomalacia), connective tissue or hyperflexibility disorders (including Marfan's syndrome and Ehlers–Danlos syndrome), congenital hand anomalies, and any cutaneous condition precluding safe cast application.

Treatment: LuCa application

All enrolled patients were managed with the LuCa, a semi-rigid circumferential metacarpal cast designed to immobilize the MCP joints while preserving motion at the wrist, proximal interphalangeal (PIP), and distal interphalangeal (DIP) joints. Where fracture displacement was present, closed reduction was performed under digital block or local anesthesia before casting, with careful correction of angular, rotational, and axial deformity.

The cast was applied with the MCP joints positioned in 70°–90° of flexion. This degree of flexion reduces the differential tension between flexor and extensor tendons, thereby enhancing fracture stability at the reduction site. The cast design leaves the finger flexion creases, wrist flexion crease, and distal palmar crease uncovered, ensuring unimpeded motion at the non-immobilized joints. The dorsal component of the cast prevents MCP hyperextension while maintaining the flexed posture.

Patients received standardized instructions to actively mobilize the interphalangeal joints of all fingers approximately 20 times daily to minimize stiffness. Cast removal was performed after approximately 4 weeks of conservative functional treatment, followed by supervised rehabilitation. Predefined thresholds for acceptable deformity – including apex angulation, axial deviation, and rotational error – were applied at each clinical review; cases exceeding these limits were referred for surgical

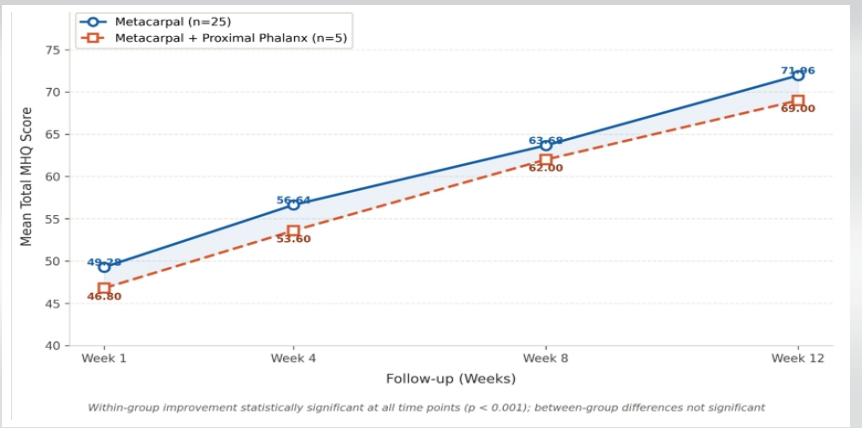

Figure 4: Progressive Michigan Hand Outcomes Questionnaire score improvement over time by fracture type.

Table 1: Baseline demographic and clinical profile (*n*=30)

Variable	Category	*n* (%)
Age (years)	Mean±SD	35.27±9.95
	≤30 years	12 (40.0)
	31–40 years	10 (33.3)
	>40 years	8 (26.7)
Gender	Male	24 (80.0)
	Female	6 (20.0)
Occupation	Manual	17 (56.7)
	Student	7 (23.3)
	Non-manual	6 (20.0)
Side involved	Right	19 (63.3)
	Left	11 (36.7)
Dominant hand involved	Yes	19 (63.3)
	No	11 (36.7)
Mechanism of injury	Fall	11 (36.7)
	Sports	7 (23.3)
	Assault	6 (20.0)
	RTA	6 (20.0)

SD: Standard deviation, RTA: Road traffic accidents

consideration (Fig. 1 and 2).

Data collection

Following written informed consent, baseline sociodemographic and clinical data were recorded using a structured pro forma. This included age, sex, occupation, hand dominance, side of injury, mechanism of injury, fracture type, bone involved, and time elapsed since injury. Radiological evaluation using standard anteroposterior, oblique, and lateral projections of the affected hand was performed at 1 week, 8 weeks, and 12 weeks post-injury to confirm initial reduction, monitor fracture alignment, and document healing. Radiological union was defined as bridging callus visible across three of four cortices on anteroposterior and lateral radiographs.

Functional outcomes were assessed using the MHQ, a validated patient-reported outcome measure comprising six domains: Hand function, ADL, pain, work performance, esthetics, and patient satisfaction [8]. Each domain is scored on a 0–100 scale, with higher scores indicating better outcomes; the pain domain is reported as a reversed score such that higher values denote less pain. MHQ assessments were conducted at 1 week, 4 weeks, 8 weeks, and 12 weeks following treatment initiation. Secondary outcomes recorded included duration of cast immobilization, overall follow-up duration until functional recovery, and requirement for referral to specialized hand therapy in cases of persistent stiffness, pain, or delayed recovery.

Statistical analysis

Data were entered in Microsoft Excel and analyzed using the Statistical Package for the Social Sciences version 23.0. Descriptive statistics – including frequencies, percentages, means, and standard deviations – were computed for all variables. Between-group comparisons for categorical variables were performed using the Chi-square test, with Fisher's exact test applied where expected cell frequencies were small. Continuous variables were compared between the two fracture type groups using the independent samples t-test. Within-group changes in MHQ scores between week 1 and subsequent follow-up time points were evaluated using paired-samples t-tests.

Ethical considerations

Ethical approval for the study was obtained from the Institutional Ethics Committee of Peoples College of Medical Sciences and Research Centre, Bhopal (Reference No. IEC–2024/61 dated March 26, 2024). Written informed consent was secured from all participants in their preferred local language prior to enrolment. Participant confidentiality and anonymity were maintained at all stages of the study.

Results

Table 2: Fracture characteristics (*n*=30)

Variable	Category	*n* (%)
Fracture type	Metacarpal only	25 (83.3)
	Metacarpal+proximal phalanx	5 (16.7)
Bone involved	5th	10 (33.3)
	2nd	5 (16.7)
	3rd	5 (16.7)
	4th	5 (16.7)
	4th and 5th	3 (10.0)
	2nd and 3rd	1 (3.3)
	3rd and 4th	1 (3.3)
Fracture pattern	Transverse	13 (43.3)
	Comminuted	6 (20.0)
	Oblique	6 (20.0)
	Spiral	5 (16.7)
Fracture location	Neck	13 (43.3)
	Shaft	11 (36.7)
	Base	6 (20.0)
Displacement	Present	25 (83.3)
	Absent	5 (16.7)

Table 3: Immobilization duration and radiological union by fracture type

Variable	Metacarpal (n=25)	Metacarpal+proximal phalanx (n=5)	t/P value
Mean immobilization (days), Mean ± standard deviation	24.42±2.78	25.60±1.95	t=1.002, P=0.325
Radiological union at 8 weeks, n (%)	17 (68.0)	5 (100.0)	P=0.289
Radiological union at 12 weeks, n (%)	8 (32.0)	0 (0.0)	

A total of 30 patients with metacarpal fractures, with or without proximal phalanx involvement, were enrolled and followed up to 12 weeks. The demographic and clinical profile of the study cohort is summarized in Table 1.

The mean age of the cohort was 35.27 ± 9.95 years (range 23–60 years), with the largest proportion belonging to in the ≤30-year age group (40.0%). Males outnumbered females by a ratio of 4:1, accounting for 80.0% of cases. More than half the patients (56.7%) were engaged in manual occupations, consistent with the physical demands associated with this injury pattern. The right hand was the injured side in 19 cases (63.3%), and in all of these the injured hand was also the dominant hand, yielding a dominant hand involvement rate of 63.3%. Falls constituted the most frequent mechanism of injury (36.7%), followed by sports-related trauma (23.3%), with assault and road traffic accidents each accounting for 20.0% of cases.

Fracture characteristics are detailed in Table 2. Isolated metacarpal fractures accounted for the vast majority of cases (83.3%), with combined metacarpal and proximal phalanx fractures seen in only 5 patients (16.7%). Among the bones involved, the 5th metacarpal was most commonly fractured (33.3%), while the 2nd, 3rd, and 4th metacarpals each contributed equally (16.7% apiece). Transverse fracture pattern predominated, seen in nearly half the cohort (43.3%), and neck fractures were the most frequent anatomical location (43.3%). Displaced fractures were present in 25 of 30 patients (83.3%).

Immobilization duration and radiological union data are presented in Table 3. The mean duration of LuCa immobilization was comparable between the two fracture groups – 24.42 ± 2.78 days for isolated metacarpal fractures versus 25.60 ± 1.95 days for combined fractures – with no statistically significant difference between them (t = 1.002, P = 0.325). Regarding radiological union, 22 of 30 patients (73.3%) achieved union by 8 weeks, while the remaining 8 (26.7%) united by 12 weeks. All five patients with combined metacarpal and proximal phalanx fractures demonstrated union at the 8-week assessment. Fisher's exact test revealed no significant difference in union timing between the two fracture types (P = 0.289).

Functional outcomes across all six MHQ domains at four follow-up time points are presented in Table 4. At week 1, scores across all domains were broadly similar between the two groups. Over the 12-week observation period, both groups demonstrated a consistent upward trajectory across every domain – function, ADL, pain (reversed), work, esthetics, and patient satisfaction. By week 12, mean total MHQ scores reached 71.96 ± 7.29 in the metacarpal fracture group and 69.00 ± 8.00 in the combined fracture group. Despite the numerically higher scores seen in isolated metacarpal fractures at most time points, none of the between-group differences across any domain reached statistical significance at any follow-up (all P > 0.05). The closest approach to significance was observed in the ADL domain at week 1 (P = 0.063), which nonetheless fell short of the threshold.

The within-group improvement in total MHQ score over time

Table 4: Mean MHQ domain scores by fracture type at each follow-up

Domain	Fracture type	1 week	4 weeks	8 weeks	12 weeks	P (between groups at 12 weeks)
Function	Metacarpal	45.40±4.83	54.20±6.38	60.16±7.52	68.12±8.25	0.177
	MC+PP	45.00±4.64	49.40±7.16	58.00±6.63	62.40±9.45	
ADL	Metacarpal	48.76±7.36	53.84±7.48	62.08±7.95	71.80±8.99	0.37
	MC+PP	41.80±7.29	50.60±5.90	59.20±9.52	67.80±8.79	
Pain (reversed)	Metacarpal	57.92±6.69	65.04±6.96	71.08±7.97	79.68±9.66	0.564
	MC+PP	55.60±7.80	58.60±8.08	72.20±5.63	77.00±7.42	
Work	Metacarpal	43.64±6.07	49.84±7.76	58.12±8.46	65.40±8.82	0.54
	MC+PP	40.80±6.76	47.80±5.26	56.20±8.50	62.60±11.33	
Esthetics	Metacarpal	52.36±6.25	59.36±6.45	66.44±8.41	74.68±9.27	0.813
	MC+PP	54.60±6.99	59.60±6.19	64.40±11.15	73.60±9.18	
Satisfaction	Metacarpal	47.52±6.98	57.56±6.92	63.92±8.03	71.96±9.69	0.742
	MC+PP	43.60±6.62	56.20±3.63	62.60±4.93	70.40±8.91	
Total MHQ	Metacarpal	49.28±3.09	56.64±4.39	63.68±6.13	71.96±7.29	0.421
	MC+PP	46.80±2.78	53.60±3.65	62.00±6.33	69.00±8.00	

MHQ: Michigan Hand Outcomes Questionnaire, MC+PP: Metacarpal+Proximal phalanx, ADL: Activities of daily living

Table 5: Within-group paired MHQ improvement over time

Fracture type	Comparison	Mean at week 1	Mean at follow-up	Mean difference	SD of difference	*t*-value	*P*-value
Metacarpal (*n*=25)	1 versus 4 weeks	49.28	56.64	7.36	8.2	4.48	<0.001
	1 versus 8 weeks	49.28	63.68	14.4	8.7	8.28	<0.0001
	1 versus 12 weeks	49.28	71.96	22.68	9.1	12.46	<0.0001
MC+PP (*n*=5)	1 versus 4 weeks	46.8	53.6	6.8	2.97	5.12	0.006
	1 versus 8 weeks	46.8	62	15.2	3.45	9.84	<0.001
	1 versus 12 weeks	46.8	69	22.2	3.61	13.76	<0.001

MHQ: Michigan Hand Outcomes Questionnaire, MC+PP: Metacarpal+Proximal phalanx, SD: Standard deviation

is quantified in Table 5. For isolated metacarpal fractures, the mean total MHQ score rose from 49.28 at week 1 to 71.96 at week 12. Paired t-test comparisons against the baseline week-1 score confirmed that improvements at 4 weeks (mean difference 7.36, t = 4.48), 8 weeks (mean difference 14.40, t = 8.28), and 12 weeks (mean difference 22.68, t = 12.46) were all highly statistically significant ($P < 0.001$ to $P < 0.0001$). An identical pattern was observed in the combined fracture group: Mean scores progressed from 46.80 at week 1 to 69.00 at week 12, with within-group improvements at 4 weeks (mean difference 6.80, t = 5.12, P = 0.006), 8 weeks (mean difference 15.20, t = 9.84, $P < 0.001$), and 12 weeks (mean difference 22.20, t = 13.76, $P < 0.001$) all reaching statistical significance.

Fig. 3 presents a grouped bar chart comparing mean total MHQ scores between the two fracture types at each follow-up visit, visually reinforcing the parallel improvement and the absence of clinically meaningful between-group divergence at any time point. The progressive nature of recovery in both groups is further illustrated in Fig. 4, a dual-line trajectory plot across the 4 follow-up weeks. The near-parallel courses of the two lines, with a consistently narrow and non-significant gap, indicate that the addition of a proximal phalanx fracture did not materially alter the functional recovery trajectory achievable with LuCa immobilization.

Discussion

The present prospective observational study evaluated the functional outcomes of LuCa immobilization in patients with metacarpal fractures with or without associated proximal phalanx fractures. The principal findings demonstrated significant progressive improvement in hand function over the 12-week follow-up period, as reflected by increasing MHQ scores across all domains. Importantly, no statistically significant differences were observed between patients with isolated metacarpal fractures and those with concomitant proximal phalanx fractures regarding functional recovery, duration of immobilization, or radiological union. These findings suggest that the LuCa provides effective fracture stabilization while facilitating satisfactory restoration of hand function irrespective of fracture complexity.

The demographic profile observed in the present study is consistent with contemporary epidemiological literature describing metacarpal fractures as injuries predominantly affecting young adult males. The mean age of 35.27 years and the marked male predominance observed in our cohort are comparable to findings reported in recent studies evaluating metacarpal fracture populations, where occupational and recreational activities contribute substantially to injury occurrence [9,10]. Similarly, the predominance of fifth metacarpal involvement and neck fractures in our study mirrors current reports identifying these fracture patterns as the most frequently encountered metacarpal injuries in clinical practice [10].

A notable observation in the present investigation was the significant improvement in MHQ scores from the 1st week to the 12th week of follow-up in both fracture groups. The improvement was evident across domains assessing function, ADL, pain, work performance, esthetics, and patient satisfaction. These findings support the concept that preservation of motion in uninvolved joints contributes substantially to functional recovery. A recent multicenter study evaluating non-operative management of metacarpal fractures reported favorable patient-reported outcomes following treatment strategies that allowed functional mobilization, emphasizing the importance of minimizing unnecessary immobilization duration [11]. Our results further reinforce this principle by demonstrating consistent recovery trajectories in patients managed with the LuCa.

The absence of significant differences in functional outcomes between isolated metacarpal fractures and fractures associated with proximal phalanx involvement is clinically important. Historically, associated phalangeal injuries have been considered potential contributors to prolonged stiffness and delayed recovery. However, recent systematic reviews examining conservative treatment of extra-articular proximal phalanx fractures have reported excellent union rates and satisfactory range-of-motion outcomes when controlled MCP flexion and early interphalangeal mobilization are employed [12,13]. The comparable outcomes observed in our study suggest that the LuCa may effectively accommodate these biomechanical requirements, thereby mitigating the adverse functional consequences often associated with additional phalangeal injury.

Radiological healing outcomes in the present study were also

encouraging. Nearly three-quarters of patients achieved radiological union by 8 weeks, while all remaining fractures united by 12 weeks. Furthermore, no significant differences in union timing were detected between fracture groups. Contemporary literature indicates that most stable closed metacarpal fractures managed conservatively progress to union with low complication rates when acceptable alignment is maintained throughout treatment [10,14]. The union rates observed in our cohort are therefore consistent with current evidence supporting non-operative management for appropriately selected fracture patterns.

Another important aspect of the present study is the use of the MHQ as the primary assessment instrument. The MHQ remains one of the most comprehensive and widely validated patient-reported outcome measures for hand disorders, allowing evaluation of multiple dimensions of recovery beyond simple radiographic healing [15]. The progressive improvement across all MHQ domains observed in our patients underscores the value of assessing patient-centered outcomes when evaluating conservative treatment modalities. Improvements in pain relief, daily function, work performance, and patient satisfaction collectively indicate successful restoration of overall hand performance rather than merely fracture union.

The favorable outcomes observed with LuCa immobilization may be attributable to its biomechanical design. By maintaining the MCP joints in flexion while preserving wrist and interphalangeal joint motion, the cast promotes fracture stability without imposing excessive immobilization on adjacent structures. Such an approach aligns with current trends in hand fracture management that emphasize functional treatment principles and early mobilization wherever clinically feasible [11,12,13]. The comparable recovery observed in both fracture groups further suggests that this method can be applied effectively across a spectrum of closed metacarpal injuries.

Limitations

The present study has several limitations, including the relatively small sample size and the very small subgroup of patients with associated proximal phalanx fractures, which limit statistical power and generalizability. The absence of a control or comparison group prevents direct assessment of the relative efficacy of the LuCa, while the prospective non-randomized design may introduce selection and confounding bias. The single-center setting further limits external validity, and the 12-week follow-up does not permit assessment of long-term functional outcomes or late complications. Objective grip strength and long-term quantitative assessment of MCP, PIP, and DIP range of motion were not performed. The study included selected closed metacarpal fractures suitable for conservative management, and therefore, the findings should not be extrapolated to unstable or complex fractures requiring operative treatment. Although different fracture locations and patterns were included and 83.3% of fractures were displaced, outcomes were not separately analyzed according to fracture pattern, location, or degree of displacement. Rotational alignment was assessed clinically during reduction but was not quantitatively recorded as a separate post-reduction outcome. Formal blinding of outcome assessment was not employed, and rehabilitation adherence and intensity were not systematically documented. Finally, multiple paired comparisons were used to assess MHQ changes over time, which may increase the risk of type-I error. Larger multicenter comparative studies with longer follow-up, objective functional assessments, standardized fracture-alignment assessment, detailed rehabilitation documentation, and appropriate longitudinal statistical methods are warranted.

Conclusion

LuCa immobilization represents a practical, functional, and feasible conservative treatment approach for appropriately selected closed 2nd–5th metacarpal fractures, with or without associated proximal phalanx fractures. In this cohort, progressive improvement in patient-reported hand function was observed across all MHQ domains over the 12-week follow-up period, with radiological union achieved in all patients by 12 weeks. Patients with associated proximal phalanx fractures also demonstrated progressive functional recovery and satisfactory radiological healing, although interpretation of this subgroup is limited by its small sample size. The functional design of the LuCa permits mobilization of the wrist and interphalangeal joints while maintaining MCP flexion and fracture immobilization, supporting early functional rehabilitation. These findings support the feasibility of LuCa treatment in appropriately selected stable closed metacarpal fractures; however, the absence of a comparison group, non-randomized design, single-center setting, limited sample size, heterogeneous fracture patterns, and short follow-up preclude conclusions regarding comparative efficacy or long-term outcomes. Larger multicenter comparative studies with longer follow-up and objective functional assessment are warranted to further establish the role of LuCa immobilization in the management of metacarpal fractures.

Clinical Message

LuCa immobilization was associated with satisfactory short-term fracture union and progressive patient-reported functional recovery while allowing mobilization of uninvolved joints.

Declaration of patient consent: The authors certify that they have obtained all appropriate patient consent forms. In the form, the patient has given the consent for his/ her images and other clinical information to be reported in the journal. The patient understands that his/ her names and initials will not be published and due efforts will be made to conceal their identity, but anonymity cannot be guaranteed.

Conflict of interest: Nil **Source of support:** None

References

1. Lambi AG, Rowland RJ, Brady NW, Rodriguez DE, Mercer DM. Metacarpal fractures. J Hand Surg Eur Vol 2023;48 Suppl 2:42S-50.

2. Stash N, Kamal RN, Richard M, Shapiro LM. Metacarpal fractures: An evidence-based review to guide treatment. J Am Acad Orthop Surg 2025;33:1361-71.

3. Vikhe CS, Daga SS, Ramteke SU. Advancements in metacarpal fracture management: A narrative review of rehabilitative strategies. Cureus 2024;16:e69970.

4. Werntz RL, Varacallo MA. Metacarpal Fracture. In: StatPearls. Treasure Island, FL: StatPearls Publishing; 2026. Available from: https://www.ncbi.nlm.nih.gov/books/nbk551532. [Last accessed date 13 Aug 2026].

5. Zhang M, Hirth M, Cole T, Hew J, Lim P, Ng S. A systematic review of conservatively managed isolated extra-articular proximal phalanx finger fractures in adults. JPRAS Open 2024;41:37-51.

6. Arcuri P, Boccolari P, Bulli M, Scarpelli F, Donati D, Tedeschi R. Optimal recovery: Unveiling the success of conservative management for proximal phalanx fractures in adults-a scoping review. Surgeries 2025;6:12.

7. Mathis KH, Peters ST, Chung KC, Herren DB, Selles RW, Slijper HP, et al. A shorter, algorithm-based Michigan hand outcomes questionnaire remains valid for outcome assessment in hand patients. J Hand Surg Eur Vol 2026;51:1129-37.

8. Shauver MJ, Chung KC. The Michigan hand outcomes questionnaire after 15 years of field trial. Plast Reconstr Surg 2013;131:779e-87.

9. Champawat VS, Sidar RS, Uikey S, Jain V, Rajpoot M. Clinical outcome of intramedullary screw fixation in metacarpal and phalangeal fractures. J Orthop Case Rep 2026;16:284-90.

10. Walde M, Schaefer DJ, Kaempfen A. Treatment outcome of 2nd to 5th Metacarpal fractures: Kirschner wires versus intramedullary screws. J Clin Med 2024;13:7626.

11. De Haas LE, Jawahier PA, Hendriks TC, Salentijn DA, Van Hoorn BT, Groenwold RH, et al. Non-operative treatment of metacarpal fractures and patient-reported outcomes: A multicentre snapshot study. Eur J Trauma Emerg Surg 2024;50:2399-409.

12. Dagi AF, Hong DY, Strauch RJ. Extra-articular base fractures of the proximal phalanx in adults: A systematic review. J Hand Surg Asian Pac Vol 2024;29:49-58.

13. Kang HT, Lee JK. Current concepts in the management of phalangeal fractures in the hand. J Musculoskelet Trauma 2025;38:109-23.

14. Lixa J, Vital L, Vieira P, Esteves A, Silva M, Pinho A, et al. A comparative retrospective study on surgical versus conservative treatment of simple fifth metacarpal neck fractures. Cureus 2024;16:e73439.

15. Killip SC, MacDermid JC, Wouters RM, Sinden KE, Gewurtz RE, Selles RW, et al. Rasch analysis of the brief Michigan hand questionnaire in patients with thumb osteoarthritis. BMC Musculoskelet Disord 2022;23:551.

Conflict of Interest: Nil
Source of Support: Nil

Consent: The authors confirm that informed consent was obtained from the patient for publication of this article

How to Cite this Article

Sahu P, Shakya M, Mahamood ST, Dashore M, Gupta N, Chatterji G. Functional Outcome of Lucerne Cast in Patients with Metacarpal Fracture with or without Proximal Phalanx Fracture: An Observational Prospective Study. Journal of Orthopaedic Case Reports 2026 October;16(10): 400-407.